

Clinical Features of the Intrahepatic and Extrahepatic Cholangiocarcinoma

Giorgio Frega, Ingrid Garajová, Andrea Palloni, Stefania De Lorenzo, Maria Aurelia Barbera and Giovanni Brandi*

Department of Experimental, Diagnostic and Speciality Medicine, Sant'Orsola-Malpighi Hospital, University of Bologna, Bologna, Italy

Abstract: Cholangiocarcinoma (CCA) is a very heterogeneous cancer in many aspects including epidemiology, risk factors, clinical presentation and genetics. Medical literature reflects this feature especially in terms of differences of clinical presentation among the intrahepatic/extrahepatic subtypes and according to related risk factors and geographic areas. Consequently these tumors are often challenging to diagnose and treat and the prognosis is poor.

This manuscript deals with the clinical presentation and epidemiology of cholangiocarcinoma.

Keywords: Cholangiocarcinoma, Classification, Incidence, Risk factors, Clinical presentation.

INTRODUCTION

Cholangiocarcinoma (CCA) is a relatively rare tumor that develops along the biliary tract. It is the most common biliary tract malignancy, accounting for approximately 3% of all gastrointestinal tumors with an incidence of about 3/100000 [1]. Anatomically CCA is commonly classified in intrahepatic CCA (I-CCA) and extrahepatic CCA (E-CCA) in keeping with anatomical position in relation to the second-order bile ducts. The latter is distinguished in perihilar-CCA (or Klatskin tumor) and distal extrahepatic-CCA. The extrahepatic subtype is more common than I-CCA although the incidence of I-CCA is increasing [2]. Conversely the incidence of E-CCA is substantially stable or slightly decreased [3, 4]. The intrahepatic-CCA, the perihilar-CCA and distal extrahepatic-CCA respectively account for 6-8%, 50-67% and 27-42% of all cholangiocarcinomas (Figure 1) [5, 6]. The main risk factors are linked to geographic area and this condition leads to significant differences in the incidence rates (e.g. the incidence of I-CCA is 85/100000 in northeast Thailand and 3.36/100000 in Italy) [7]. These tumors are often challenging to diagnose and treat. The diagnosis results from an integration of clinical information, biochemical parameters, tumor markers, imaging studies, cytology and/or histology. Most of the E-CCAs occurs with the appearance of jaundice or related cholangitis at onset and, unlike the I-CCAs, only in a few cases patients are completely asymptomatic at diagnosis. Conversely a large percentage of patients

with I-CCA are asymptomatic at diagnoses and clinical-radiological findings are usually related with macroscopic features.

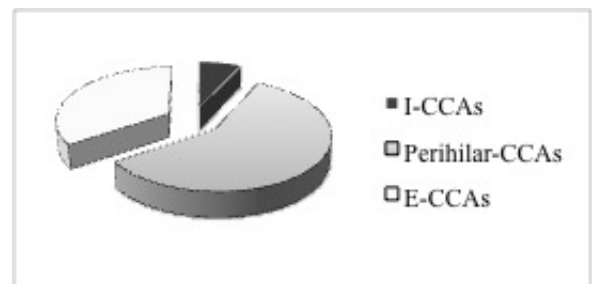


Figure 1: Percentage of intrahepatic-CCAs (I-CCAs), perihilar-CCAs and distal extrahepatic-CCAs (E-CCAs) within all cholangiocarcinomas [5, 6].

Unfortunately the majority of patients present with advanced disease. Complete surgical resection is the only potentially curative treatment but it is feasible only in a small percentage of cases [8]. At present, unlike other gastrointestinal cancers, such as rectal cancer, there are not definitive data about neoadjuvant therapy for CCA [9]. A trial from the Mayo Clinic showed positive results with a combined neoadjuvant therapy (5-FU-based chemo-radiation, brachithery and oral capecitabine) followed by liver transplantation in highly selected patients with perihilar-CCA [10, 11]. In presence of high-risk features (lymphnodal metastases, lymphovascular invasion, satellitosis) an adjuvant therapy should be considered, even if there aren't definitive recommendations [12, 13]. Chemotherapy (cisplatin plus gemcitabine) represents the standard-of-care for metastatic patients [14, 15]. Loco-regional therapies may be proposed for locally advanced or oligometastatic disease in selected cases.

*Address correspondence to this author at the Department of Experimental, Diagnostic and Speciality Medicine, University of Bologna, Sant'Orsola-Malpighi Hospital, Via Massarenti 9, 40138 Bologna, Italy; Tel: +390516364536; Fax: +390516364536; E-mail: giovanni.brandi@unibo.it

Endoscopic (or percutaneous) biliary drainage is useful in case of jaundice to prevent liver failure and cholangitis [16]. All in all, the prognosis is poor. This paper aims to be a quick guide on the clinical features of CCA with a brief analysis of the most important risk factors related to this disease.

RISK FACTORS

In more than 60% of CCA cases there are no detectable putative risk factors [17]. The presence of persistent inflammation is the common condition of the main known risk factors associated with the development of cholangiocarcinoma. Consequently this neoplasm could be considered a prototype of inflammation-associated cancer. Persisted tissue damage induces the proliferation of stem cells as a first step in the cancer process [7, 17]. Metaplasia usually occurs in a context of chronic inflammation and injury. The recent finding of stem cell niches in peribiliary glands of extrahepatic/intrahepatic biliary tree is interesting because these cells may play a primary role in the origin of CCA [18, 19].

According to the above, chronic diseases primarily affecting the extrahepatic bile ducts and/or large intrahepatic bile ducts such as primary sclerosing cholangitis (PSC), Caroli's disease, Vater ampulla adenoma, bile duct adenoma, bile duct cysts, hepatolithiasis and choledocholithiasis are related to both the E-CCA and I-CCA development [20]. Cholelithiasis and probably cholecystectomy, bilio-enteric surgical drainage and pancreatobiliary maljunction, are involved in the development of E-CCA in relation to the presence of bile duct dilatation and stagnation of bile [7].

PSC is one of the best-known risk factors for E-CCAs in the Western world. Among patients with PSC, the prevalence of CCA ranges from 5% to 10%, with an overall risk of 0.5% to 1.5%/year. The neoplasm occurs most often as a desmoplastic ductal lesion but may sometimes present itself as a focal I-CCA. The tumor is often detected within the first three years after the initial diagnosis of PSC. In the 20-30% of cases the diagnosis is synchronous, within one year in the 50% of cases [21].

Some factors (*i.e.* alcohol use, smoking, obesity, diabetes, longer duration of the concomitant inflammatory bowel disease, colorectal cancer or dysplasia in patients with ulcerative colitis, biliary stones, polymorphism in the NKG2D gene, exposure to asbestos) could modify CCA risk even if they are still

debated (Table 1) [2, 22]. Concerning I-CCA, viral and metabolic cirrhosis (induced by chronic hepatitis virus C and virus B infection or by hemochromatosis, Wilson's disease and non-alcoholic steato-hepatitis) can be considered as recently emerging risk factor with different strong of evidence [23-25].

Table 1: Risk Factors for Intra and Extrahepatic Cholangiocarcinoma

| |
|--|
| <p>Established Risk Factors (Strong Evidence)</p> <p>primary sclerosing cholangitis (PSC), Caroli's disease, hepato-choledocholithiasis, Vater ampulla adenoma, bile duct adenoma, bile duct cysts, HCV cirrhosis, fluke infections (<i>O. viverrini</i>, <i>Clonorchis sinensis</i>, <i>Schistosomiasis japonica</i>), bacterial infection (<i>Salmonella typhi</i>), thorotrast.</p> |
| <p>Still Debated Risk Factors (Moderate or Weak Evidence)</p> <p>cholecystectomy, bilio-enteric surgical drainage, pancreaticobiliary maljunction, alcohol use, obesity, diabetes, smoking, hemochromatosis, Wilson's disease, non alcoholic steato-hepatitis, HBV cirrhosis, longer duration of the concomitant inflammatory bowel disease, biliary stones, polymorphism in the NKG2D gene, exposure to asbestos, exposure to other xenobiotic</p> |

Abbreviations: HBV (hepatitis B virus); HCV (hepatitis C virus); PSC (primary sclerosing cholangitis).

In Asian countries additional relevant risk factors are *Opisthorchis viverrini* and *Clonorchis sinensis* (flukes that colonize the hepatobiliary ducts), but also *Schistosomiasis japonica* and *Salmonella typhi* in endemic regions [20]. Fluke infection induces a chronic inflammation resulting in increased cell turnover and susceptibility to endogenous and exogenous carcinogens infection [26]. Finally there are important evidences of association between the exposure to thorotrast (an old, no longer employed, radio-contrast agent) and hepatic malignancy, including CCA; while the role of other xenobiotic (*i.e.* nitrosamine, dioxins, vinyl chlorides) is still under investigation [27-29].

CLINICAL FEATURES

The clinical presentation is different from I-CCA and E-CCA. Moreover, clinical symptoms are usually late and do not facilitate an early diagnosis. Patients with extra-hepatic neoplasms usually present obstructive jaundice and sometimes complications such as cholangitis. Conversely patients with I-CCAs may present more non-specific symptoms like abdominal pain, malaise, night sweats, weight loss and loss of appetite [5].

The onset of disease was estimated to occur in a very wide range of ages. The median age at presentation ranged from 59 to 71 years. Alvaro *et al* reported that the age at diagnosis was significantly higher for E-CCA than I-CCA [30]. As regards I-CCAs,

a slight prevalence of male was observed in series analysed from Italy, United States, France and Greece [30-33]. E-CCAs were similarly distributed by sex [30].

Patients with an early stage I-CCA disease are usually asymptomatic [34]. Jaundice or cholangitis do not manifest until hilar infiltration [15, 35]. Hepatomegaly, night sweats and ascites usually appear late. Often disease remains silent even in advanced stage. An incidental diagnosis occurs in 12-30% of cases. A 30-73% of patients are asymptomatic at diagnosis [30, 31, 36, 37]. The main clinical manifestations included upper abdominal discomfort, pain or sense of fullness (42-65%), asthenia (8%), abdominal distension (2-4%), jaundice (2,5-3%), nausea (3%), lower back pain (2.5%), abdominal mass, pruritus (4%) and weight loss (18%) (Table 2) [30, 37].

The analysis of the sub-setting of patients with abdominal pain demonstrated that this condition without other symptoms represents a frequent clinical presentation of I-CCA (19.8%) with respect to E-CCA (3.9%) [30]. Conversely abdominal pain with jaundice occurs 2-fold more frequently in E-CCA than I-CCA (24.5% vs. 10.3%). Pruritus was rarely encountered both in E-CCA (6.9%) and in I-CCA (4.3%) [30]. As results, an early diagnosis of I-CCA is very difficult to achieve due to a specific presentation, the lack of early

symptoms or reliable tumor biomarkers and the wide range of differential diagnoses.

Otherwise, clinical presentation and radiological findings of I-CCA correlate with the pattern of growth: mass-forming (mass lesion in the liver and spread based on the intrahepatic metastasis), intraductal papillary (papillary projection into the ductal lumen), periductal infiltrating (spreading along the bile duct) and mixed types (neoplasms with mixed features) [38-40]. Interestingly this morphologically based classification in three principal subtypes (plus mixed types) relates with growth characteristic and natural history of the tumor [41, 42]. The mass-forming type is the most commonly subtype of ICC. The intraductal growth type, which accounts for about a 4% of I-CCAs, seems to have a significantly better prognosis [43-45]. Other features for each subtype have been reported, sometimes with discordant results due to the limited number of cases from the single centers.

As regards E-CCA, the neoplastic obstruction of the bile duct leads to the onset of jaundice, cholangitis and liver failure. Other symptoms of biliary obstruction such as pale stools, dark urine and pruritus are usually present. With some exceptions, despite the more early appearance of jaundice, even for the E-CCA the diagnosis is delayed. The problem of differential

Table 2: Signs and Symptoms of Cholangiocarcinomas

| Subtype | Very Early | Early | Late |
|---------|--|--|--|
| I-CCA | asymptomatic | usually asymptomatic jaundice or cholangitis only if hilar infiltration | upper abdominal discomfort pain or sense of fullness asthenia abdominal distension nausea, hyporexia weight loss lower back pain abdominal mass pruritus hepatomegaly night sweats ascites jaundice or cholangitis (if hilar infiltration) |
| E-CCA | asymptomatic jaundice (if intra-ductal growth in the common bile duct or hilum) | jaundice or cholangitis pancreatitis (if near Wirsung duct) | jaundice cholangitis pancreatitis (if near Wirsung duct) night sweats nausea, hyporexia weight loss upper abdominal discomfort pain or sense of fullness ascites pruritus asthenia |

Signs and symptoms that may occur as a consequence of the evolution of the tumor.

diagnosis is relevant. Over 80% of proximal biliary obstructions are secondary to neoplastic conditions, while the remaining 15-20% is caused by benign strictures (such as sclerosing cholangitis, choledocholithiasis, Mirizzi's syndrome and idiopathic benign stricture). In addition other malignancies secondarily involving the hepatic hilum may present with similar symptoms. There are no reported significant differences in most of the clinical variables between patients with E-CCA or patients with benign and other malignant obstructions, with the exception of fatigue [46].

Several elevated laboratory parameters may be suggestive although not diagnostic of CCA. The biochemical profile of patients with E-CCA is usually indicative of a status of biliary obstruction (increase in total and direct bilirubin, alkaline phosphatase and γ -glutamyltransferase). Singal *et al.* reported a median bilirubin level of 9.4 mg/dL in patients with E-CCA compared with a median bilirubin level of 1.0 in those with I-CCA [33]. Plasma serum markers (CA19-9 and CEA) may be useful for differential diagnoses even if the diagnostic utility of CA 19-9 and CEA is limited due to their low sensitivity (50-63% and 15-20%, respectively) [47-50]. In the context of primary sclerosing cholangitis the estimated sensitivity and specificity of CA 19-9 in predicting CCA are respectively 38-89% and 50-98% [51]. In these conditions the measurement of serum carbohydrate antigen (CA 19-9) could be useful despite the moderate sensitivity [52]. A CA 19-9 cut off of 130 U/ml in the absence of bacterial cholangitis detects CCA with 79% sensitivity and 98% specificity [53]. Recently it was shown that patients with PSC and/or CCA have different miRNA profiles in bile and serum [54]. The combination of specific miRNAs seems further improve the specificity and accuracy of diagnosis, although these findings need to be validated in larger series [55]. Furthermore, concerning the biochemical profile, elevated CA 19-9 and hyperbilirubinaemia are correlated with poor survival rates [33, 56]. Significantly higher CA 19-9 levels are reported in patients with unresectable CCA than patients with resectable CCA [57].

CONCLUSION

As described above, the clinical presentation of cholangiocarcinoma depends greatly on the site where the cancer develops and on the "height" and the extent of the obstruction of the biliary tree.

The classification of these neoplasms is substantially based on the macroscopic and

microscopic histopathologic features. Further work is needed to define the molecular and genetic profile of different types of CCA.

No reliable method of early detection is currently available. Sometimes an early diagnosis is possible in patients with E-CCA if there is a complete obstruction of bile flow from the initial development of the disease. Unfortunately, even in this circumstance, the therapeutic approach does not always allow high rates of healing due to the limits of surgery on such a complex anatomical district. The identification of novel serum markers could help in the near future to achieve more accurate and earlier diagnosis. This could lead to the advent of minimally invasive approaches to achieve radical treatment or to limit the rate of unresectable patients and non-radical resections.

At the current state the diagnosis and treatment of cholangiocarcinoma, especially if surgery is not feasible, remain a tough challenge in the field of the gastro-intestinal oncology.

REFERENCES

- [1] Vauthey JN, Blumgart LH. Recent advances in the management of cholangiocarcinomas. *Semin Liver Dis* 1994; 14(2): 109-14.
<http://dx.doi.org/10.1055/s-2007-1007302>
- [2] Brandi G, Di Girolamo S, Farioli A, de Rosa F, Curti S, Pinna AD, *et al.* Asbestos: a hidden player behind the cholangiocarcinoma increase? Findings from a case-control analysis. *Cancer Causes Control* 2013; 24(5): 911-8.
<http://dx.doi.org/10.1007/s10552-013-0167-3>
- [3] Ghosn M, Kourie HR, El Rassy E, Chebib R, El Karak F, Hanna C, *et al.* Optimum chemotherapy for the management of advanced biliary tract cancer. *World J Gastroenterol* WJG 2015; 21(14): 4121-5.
<http://dx.doi.org/10.3748/wjg.v21.i14.4121>
- [4] Khan SA, Toledano MB, Taylor-Robinson SD. Epidemiology, risk factors, and pathogenesis of cholangiocarcinoma *HPB* 2008; 10(2): 77-82.
<http://dx.doi.org/10.1080/13651820801992641>
- [5] Ghouri YA, Mian I, Blechacz B. Cancer review: Cholangiocarcinoma. *J Carcinog* [Internet] 2015 [cited 2016]; 14.
<http://dx.doi.org/10.4103/1477-3163.151940>
- [6] DeOliveira ML, Cunningham SC, Cameron JL, Kamangar F, Winter JM, Lillemoe KD, *et al.* Cholangiocarcinoma: thirty-year experience with 564 patients at a single institution. *Ann Surg* 2007; 245(5): 755-62.
<http://dx.doi.org/10.1097/01.sla.0000251366.62632.d3>
- [7] Bragazzi MC, Cardinale V, Carpino G, Venere R, Semeraro R, Gentile R, *et al.* Cholangiocarcinoma: Epidemiology and risk factors. *Transl Gastrointest Cancer*. 2011; 1(1): 21-32. Available from: <http://tgc.amegroups.com/article/view/74/63>
- [8] Ercolani G, Vetrone G, Grazi GL, Aramaki O, Cescon M, Ravaioli M, *et al.* Intrahepatic cholangiocarcinoma: primary liver resection and aggressive multimodal treatment of recurrence significantly prolong survival. *Ann Surg* 2010; 252(1): 107-14.
<http://dx.doi.org/10.1097/SLA.0b013e3181e462e6>

- [9] Garajová I, Di Girolamo S, de Rosa F, Corbelli J, Agostini V, Biasco G, *et al.* Neoadjuvant treatment in rectal cancer: actual status. *Chemother Res Pract* 2011; 839742. <http://dx.doi.org/10.1097/SLA.0b013e3181e462e6>
- [10] Heimbach JK, Gores GJ, Haddock MG, Alberts SR, Nyberg SL, Ishitani MB, *et al.* Liver transplantation for unresectable perihilar cholangiocarcinoma. *Semin Liver Dis* 2004; 24(2): 201-7. <http://dx.doi.org/10.1055/s-2004-828896>
- [11] Esnaola NF, Meyer JE, Karachristos A, Maranki JL, Camp ER, Denlinger CS. Evaluation and management of intrahepatic and extrahepatic cholangiocarcinoma. *Cancer* 2016. <http://dx.doi.org/10.1002/cncr.29692>
- [12] Brandi G, Venturi M, Pantaleo MA, Ercolani G, GICO. Cholangiocarcinoma: Current opinion on clinical practice diagnostic and therapeutic algorithms: A review of the literature and a long-standing experience of a referral center. *Dig Liver Dis* 2016; 48(3): 231-41. <http://dx.doi.org/10.1016/j.dld.2015.11.017>
- [13] Brandi G, Deserti M, Vasuri F, Farioli A, Degiovanni A, Palloni A, *et al.* Membrane Localization of Human Equilibrative Nucleoside Transporter 1 in Tumor Cells May Predict Response to Adjuvant Gemcitabine in Resected Cholangiocarcinoma Patients. *Oncologist* 2016; 21(5): 600-7. <http://dx.doi.org/10.1634/theoncologist.2015-0356>
- [14] Valle J, Wasan H, Palmer DH, Cunningham D, Anthony A, Maraveyas A, *et al.* Cisplatin plus gemcitabine versus gemcitabine for biliary tract cancer. *N Engl J Med* 2010; 362(14): 1273-81. <http://dx.doi.org/10.1056/NEJMoa0908721>
- [15] Weber SM, Ribero D, O'Reilly EM, Kokudo N, Miyazaki M, Pawlik TM. Intrahepatic cholangiocarcinoma: expert consensus statement. *HPB* 2015; 17(8): 669-80. <http://dx.doi.org/10.1111/hpb.12441>
- [16] Bertani H, Frazzoni M, Mangiafico S, Caruso A, Manno M, Mirante VG, *et al.* Cholangiocarcinoma and malignant bile duct obstruction: A review of last decades advances in therapeutic endoscopy. *World J Gastrointest Endosc* 2015; 7(6): 582-92. doi:10.4253/wjge.v7.i6.582.
- [17] Cardinale V, Bragazzi MC, Carpino G, Torrice A, Fraveto A, Gentile R, *et al.* Cholangiocarcinoma: increasing burden of classifications. *Hepatobiliary Surg Nutr* 2013; 2(5): 272-80. doi:10.3978/j.issn.2304-3881.2013.10.02.
- [18] Cardinale V, Wang Y, Carpino G, Cui C-B, Gatto M, Rossi M, *et al.* Multipotent stem/progenitor cells in human biliary tree give rise to hepatocytes, cholangiocytes, and pancreatic islets. *HepatoL Baltim Md* 2011; 54(6): 2159-72. <http://dx.doi.org/10.1002/hep.24590>
- [19] Carpino G, Cardinale V, Onori P, Franchitto A, Berloco PB, Rossi M, *et al.* Biliary tree stem/progenitor cells in glands of extrahepatic and intrahepatic bile ducts: an anatomical in situ study yielding evidence of maturational lineages. *J Anat* 2012; 220(2): 186-99. <http://dx.doi.org/10.1111/j.1469-7580.2011.01462.x>
- [20] Alvaro D, Cannizzaro R, Labianca R, Valvo F, Farinati F. Cholangiocarcinoma: A position paper by the Italian Society of Gastroenterology (SIGE), the Italian Association of Hospital Gastroenterology (AIGO), the Italian Association of Medical Oncology (AIOM) and the Italian Association of Oncological Radiotherapy (AIRO). *Digestive and Liver Disease* 2010; 42(12): 831-8. <http://dx.doi.org/10.1016/j.dld.2010.06.005>
- [21] Fevery J, Verslype C, Lai G, Aerts R, Van Steenberghe W. Incidence, diagnosis, and therapy of cholangiocarcinoma in patients with primary sclerosing cholangitis. *Dig Dis Sci* 2007; 52(11): 3123-35. <http://dx.doi.org/10.1007/s10620-006-9681-4>
- [22] Razumilava N, Gores GJ, Lindor KD. Cancer surveillance in patients with primary sclerosing cholangitis. *HepatoL Baltim Md* 2011; 54(5): 1842-52. <http://dx.doi.org/10.1002/hep.24570>
- [23] Donato F, Gelatti U, Tagger A, Favret M, Ribero ML, Callea F, *et al.* Intrahepatic cholangiocarcinoma and hepatitis C and B virus infection, alcohol intake, and hepatolithiasis: a case-control study in Italy. *Cancer Causes Control* 2001; 12(10): 959-64. <http://dx.doi.org/10.1023/A:1013747228572>
- [24] Yamamoto S, Kubo S, Hai S, Uenishi T, Yamamoto T, Shuto T, *et al.* Hepatitis C virus infection as a likely etiology of intrahepatic cholangiocarcinoma. *Cancer Sci* 2004; 95(7): 592-5. <http://dx.doi.org/10.1111/j.1349-7006.2004.tb02492.x>
- [25] Perumal V, Wang J, Thuluvath P, Choti M, Torbenson M. Hepatitis C and hepatitis B nucleic acids are present in intrahepatic cholangiocarcinomas from the United States. *Hum Pathol* 2006; 37(9): 1211-6. <http://dx.doi.org/10.1016/j.humpath.2006.04.012>
- [26] Kaewpitoon N, Kaewpitoon S-J, Pengsaa P, Sripa B. *Opisthorchis viverrini*: the carcinogenic human liver fluke. *World J Gastroenterol* 2008; 14(5): 666-74. PMID: 18205254. <http://dx.doi.org/10.3748/wjg.14.666>
- [27] Patel T. Cholangiocarcinoma--controversies and challenges. *Nat Rev Gastroenterol Hepatol* 2011; 8(4): 189-200. <http://dx.doi.org/10.1038/nrgastro.2011.20>
- [28] Banales JM, Cardinale V, Carpino G, Marzioni M, Andersen JB, Invernizzi P, *et al.* Expert consensus document: Cholangiocarcinoma: current knowledge and future perspectives consensus statement from the European Network for the Study of Cholangiocarcinoma (ENS-CCA). *Nat Rev Gastroenterol Hepatol* 2016; 13(5): 261-80. <http://dx.doi.org/10.1038/nrgastro.2016.51>
- [29] Ito Y, Kojiro M, Nakashima T, Mori T. Pathomorphologic characteristics of 102 cases of thorotrast-related hepatocellular carcinoma, cholangiocarcinoma, and hepatic angiosarcoma *Cancer* 1988; 62(6): 1153-62. [http://dx.doi.org/10.1002/1097-0142\(19880915\)62:6<1153::AID-CNCR2820620619>3.0.CO;2-I](http://dx.doi.org/10.1002/1097-0142(19880915)62:6<1153::AID-CNCR2820620619>3.0.CO;2-I)
- [30] Alvaro D, Bragazzi MC, Benedetti A, Fabris L, Fava G, Invernizzi P, *et al.* Cholangiocarcinoma in Italy: A national survey on clinical characteristics, diagnostic modalities and treatment. Results from the "Cholangiocarcinoma" committee of the Italian Association for the Study of Liver disease. *Dig Liver Dis Off J Ital Soc Gastroenterol Ital Assoc Study Liver* 2011; 43(1): 60-5. <http://dx.doi.org/10.1016/j.dld.2010.05.002>
- [31] El Rassi ZE, Partensky C, Scoazec JY, Henry L, Lombard-Bohas C, Maddern G. Peripheral cholangiocarcinoma: presentation, diagnosis, pathology and management. *Eur J Surg Oncol J Eur Soc Surg Oncol Br Assoc Surg Oncol* 1999; 25(4): 375-80. <http://dx.doi.org/10.1053/ejso.1999.0660>
- [32] Alexopoulou A, Soultati A, Dourakis S-P, Vasileva L, Archimandritis A-J. Cholangiocarcinoma: a 7-year experience at a single center in Greece. *World J Gastroenterol* 2008; 14(40): 6213-7. PMID: 18985813. <http://dx.doi.org/10.3748/wjg.14.6213>
- [33] Singal AG, Rakoski MO, Salgia R, Pelletier S, Welling TH, Fontana RJ, *et al.* The clinical presentation and prognostic factors for intrahepatic and extrahepatic cholangiocarcinoma in a tertiary care centre. *Aliment Pharmacol Ther* 2010; 31(6): 625-33. <http://dx.doi.org/10.1111/j.1365-2036.2009.04218.x>
- [34] Bartella I, Dufour J-F. Clinical Diagnosis and Staging of Intrahepatic Cholangiocarcinoma. *J Gastrointest Liver Dis JGLD* 2015; 24(4): 481-9. <http://dx.doi.org/10.15403/jgld.2014.1121.244.chl>
- [35] Blechacz B, Komuta M, Roskams T, Gores GJ. Clinical diagnosis and staging of cholangiocarcinoma. *Nat Rev*

- Gastroenterol Hepatol 2011; 8(9): 512-22.
<http://dx.doi.org/10.1038/nrgastro.2011.131>
- [36] Okabayashi T, Yamamoto J, Kosuge T, Shimada K, Yamasaki S, Takayama T, *et al.* A new staging system for mass-forming intrahepatic cholangiocarcinoma: analysis of preoperative and postoperative variables. *Cancer* 2001; 92(9): 2374-83. PMID: 11745293.
[http://dx.doi.org/10.1002/1097-0142\(20011101\)92:9<2374::AID-CNCR1585>3.0.CO;2-L](http://dx.doi.org/10.1002/1097-0142(20011101)92:9<2374::AID-CNCR1585>3.0.CO;2-L)
- [37] Shen W-F, Zhong W, Xu F, Kan T, Geng L, Xie F, *et al.* Clinicopathological and prognostic analysis of 429 patients with intrahepatic cholangiocarcinoma. *World J Gastroenterol* 2009; 15(47): 5976-82. PMID: 20014463.
<http://dx.doi.org/10.3748/wjg.15.5976>
- [38] Yamamoto J, Kosuge T, Shimada K, Takayama T, Yamasaki S, Ozaki H, *et al.* [Intrahepatic cholangiocarcinoma: proposal of new macroscopic classification]. *Nihon Geka Gakkai Zasshi* 1993; 94(11): 1194-200. PMID: 8272051.
- [39] Yamasaki S. [TNM classification of liver cancer]. *Gan To Kagaku Ryoho* 1997; 24(9): 1175-82. PMID: 9239174.
- [40] Yamasaki S. Intrahepatic cholangiocarcinoma: macroscopic type and stage classification. *J Hepatobiliary Pancreat Surg* 2003; 10(4): 288-91.
<http://dx.doi.org/10.1007/s00534-002-0732-8>
- [41] Patel T. Cholangiocarcinoma. *Nat Clin Pract Gastroenterol Hepatol* 2006; 3(1): 33-42.
<http://dx.doi.org/10.1038/npcgasthep0389>
- [42] Hirohashi K, Uenishi T, Kubo S, Yamamoto T, Tanaka H, Shuto T, *et al.* Macroscopic types of intrahepatic cholangiocarcinoma: clinicopathologic features and surgical outcomes. *Hepatogastroenterology* 2002; 49(44): 326-9. PMID: 11995443.
- [43] Yamamoto Y, Shimada K, Sakamoto Y, Esaki M, Nara S, Ban D, *et al.* Clinicopathological characteristics of intrahepatic cholangiocellular carcinoma presenting intrahepatic bile duct growth. *J Surg Oncol* 2009; 99(3): 161-5.
<http://dx.doi.org/10.1002/jso.21214>
- [44] Suh KS, Roh HR, Koh YT, Lee KU, Park YH, Kim SW. Clinicopathologic features of the intraductal growth type of peripheral cholangiocarcinoma. *Hepatol Baltim Md* 2000; 31(1): 12-7.
<http://dx.doi.org/10.1002/hep.510310104>
- [45] Shimada K, Sano T, Sakamoto Y, Esaki M, Kosuge T, Ojima H. Surgical outcomes of the mass-forming plus periductal infiltrating types of intrahepatic cholangiocarcinoma: a comparative study with the typical mass-forming type of intrahepatic cholangiocarcinoma. *World J Surg* 2007; 31(10): 2016-22.
<http://dx.doi.org/10.1007/s00268-007-9194-0>
- [46] Are C, Gonen M, D'Angelica M, DeMatteo RP, Fong Y, Blumgart LH, *et al.* Differential diagnosis of proximal biliary obstruction. *Surgery* 2006; 140(5): 756-63.
<http://dx.doi.org/10.1016/j.surg.2006.03.028>
- [47] Bridgewater J, Galle PR, Khan SA, Llovet JM, Park J-W, Patel T, *et al.* Guidelines for the diagnosis and management of intrahepatic cholangiocarcinoma. *J Hepatol* 2014; 60(6): 1268-89.
<http://dx.doi.org/10.1016/j.jhep.2014.01.021>
- [48] Dodson RM, Weiss MJ, Cosgrove D, Herman JM, Kamel I, Anders R, *et al.* Intrahepatic cholangiocarcinoma: management options and emerging therapies. *J Am Coll Surg* 2013; 217(4): 736-50.e4.
<http://dx.doi.org/10.1016/j.jamcollsurg.2013.05.021>
- [49] Maithel SK, Gamblin TC, Kamel I, Corona-Villalobos CP, Thomas M, Pawlik TM. Multidisciplinary approaches to intrahepatic cholangiocarcinoma. *Cancer* 2013; 119(22): 3929-42.
<http://dx.doi.org/10.1002/cncr.28312>
- [50] Luo X, Yuan L, Wang Y, Ge R, Sun Y, Wei G. Survival outcomes and prognostic factors of surgical therapy for all potentially resectable intrahepatic cholangiocarcinoma: a large single-center cohort study. *J Gastrointest Surg Off J Soc Surg Aliment Tract* 2014; 18(3): 562-72.
<http://dx.doi.org/10.1007/s11605-013-2447-3>
- [51] Nehls O, Gregor M, Klump B. Serum and bile markers for cholangiocarcinoma. *Semin Liver Dis* 2004; 24(2): 139-54.
<http://dx.doi.org/10.1055/s-2004-828891>
- [52] Liang B, Zhong L, He Q, Wang S, Pan Z, Wang T, *et al.* Diagnostic Accuracy of Serum CA19-9 in Patients with Cholangiocarcinoma: A Systematic Review and Meta-Analysis. *Med Sci Monit Int Med J Exp Clin Res* 2015; 21: 3555-63. PMID: 26576628.
<http://dx.doi.org/10.12659/MSM.895040>
- [53] Levy C, Lymp J, Angulo P, Gores GJ, Larusso N, Lindor KD. The value of serum CA 19-9 in predicting cholangiocarcinomas in patients with primary sclerosing cholangitis. *Dig Dis Sci* 2005; 50(9): 1734-40.
<http://dx.doi.org/10.1007/s10620-005-2927-8>
- [54] Voigtlander T, Gupta SK, Thum S, Fendrich J, Manns MP, Lankisch TO, *et al.* MicroRNAs in Serum and Bile of Patients with Primary Sclerosing Cholangitis and/or Cholangiocarcinoma. *PLoS One* 2015; 10(10): e0139305.
<http://dx.doi.org/10.1371/journal.pone.0139305>
- [55] Bernuzzi F, Marabita F, Lleo A, Carbone M, Mirolo M, Marzioni M, *et al.* Serum micromRNAs as novel biomarkers for primary sclerosing cholangitis and cholangiocarcinoma. *Clin Exp Immunol* 2016.
<http://dx.doi.org/10.1111/cei.12776>
- [56] Weber A, Landrock S, Schneider J, Stangl M, Neu B, Born P, *et al.* Long-term outcome and prognostic factors of patients with hilar cholangiocarcinoma. *World J Gastroenterol* 2007; 13(9): 1422-6. PMID: 17457974.
<http://dx.doi.org/10.3748/wjg.v13.i9.1422>
- [57] Patel AH, Harnois DM, Klee GG, LaRusso NF, Gores GJ. The utility of CA 19-9 in the diagnoses of cholangiocarcinoma in patients without primary sclerosing cholangitis. *Am J Gastroenterol* 2000; 95(1): 204-7.
<http://dx.doi.org/10.1111/j.1572-0241.2000.01685.x>

Received on 13-06-2016

Accepted on 11-08-2016

Published on 19-08-2016

<http://dx.doi.org/10.15379/2413-7308.2016.03.03>© 2016 Frega *et al.*; Licensee Cosmos Scholars Publishing House.

This is an open access article licensed under the terms of the Creative Commons Attribution Non-Commercial License

(http://creativecommons.org/licenses/by-nc/3.0/), which permits unrestricted, non-commercial use, distribution and reproduction in any medium, provided the work is properly cited.