

An Unusual Case of Complex Regional Pain Syndrome

George M. Weisz*

School of Humanities at University of New England Armidale, and University of New South Wales, Sydney, Australia

Abstract: The complex regional pain syndrome (CRPS) was reported in the literature following numerous traumatic events. Stretching the Brachial plexus, such as in peri-operational positioning, was as yet not found. The author is presenting a recently discovered such case. The clinical presentation is illustrated by a probable mechanism of pathogenesis.

Keywords: Complex regional pain, Peri-operative positioning, Cerebral disturbances, Traumatic disc protrusion, Paraesthesia.

INTRODUCTION

Complex regional pain syndrome (CRPS), previously known as sympathetic dystrophy, is a well differentiated condition defined by the International Society for the Study of Pain. The clinical syndrome was previously graded by Harden, Stanton-Hicks and Galer and more recently by the Budapest classification [1-5]. Various examples of traumatic and medical conditions have been published, all outlining autonomic sympathetic and cerebral disturbances that result in CRPS.

Peri-operational positional nerve compression and stretching were both found to cause peripheral neuritis, some temporary and some long lasting [6-8]. The author reports a case of positional CRPS which developed following a prolonged spinal surgical procedure in the prone position.

CASE REPORT

A 23 year old healthy man underwent a spinal fusion for a traumatic disc protrusion (5/S1), a procedure lasting close to three hours. Intra-operatively, he was positioned prone, the left arm abducted for intravenous infusion, and the right arm abducted for pulse and blood pressure control. Following the surgery, left arm ulnar nerve irritation was diagnosed, which gradually diminished and electrophysiologically was found to be intact. However, after 2-3 months, gradual and intensifying left upper limb pain appeared, paraesthesia and weakness developed, and the arm became immobile. The patient was treated

with various oral medications (analgesics, the anti-epileptic gabapentine, etc.), physiotherapy and hydrotherapy for an immobile shoulder on the left, non-dominant side.

On review one year from the spinal fusion, the left arm was hanging, held by the right hand, the pain was relentless and the paraesthesia was permanent. The grasping ability was nil, the skin had hypo-aesthesia, at the flexor side of the forearm and in the palm; the skin was moist in the palm and the skin colour was cyanotic and mottled. There were faint temperature changes, but no dystrophic skin, nail or hair changes. Reflexes were intact, passive movements of joints below the shoulder were slow, but present. The left shoulder movements were very restricted on passive attempts and caused pain. Active movements were 40 degrees of abduction, 50 degrees of flexion, and no internal or external movements were performed. A diagnosis of CRPS was established. Conservative treatment continued without much benefit.

DISCUSSION

Until a decade or so ago, the syndrome presented here was known as "sympathetic", suggesting a connection with the nervous system and comprising a reaction to nerve irritation or damage. It was also referred to as a "dystrophy" of the limb. Symptoms and signs were assembled in a rare and non-characteristic group, representing a disabling and painful condition. Reports of various medical and surgical conditions followed, however these were mainly after peripheral nerve contusion of the upper extremity: crush or physical injuries (fracture, dislocation), thermal or chemical nerve damage, post-shoulder or thyroid surgery, following lumbar and cervical spine surgery or brachial plexus neurolysis [9-10]. The condition was

*Address correspondence to this author at the School of Humanities, University of New England, Armidale and School of Humanities, University of New South Wales, Sydney, Australia; Tel: +61-2-9389284; Fax: 93888873; E-mail: gmweisz1@aol.com

treated conservatively with little effect. The course was prolonged and the prognosis was unpredictable.

Spinal surgery can involve prolonged time in theatre and demands avoidance of position-related complications. Unnatural positioning, such as prone positioning with compression on the peripheral nerves (ulnar, radial, femoral) is rare, less than 1% of spinal surgery procedures, but occasionally may result as lasting sequelae. Despite padding the arms and body, and with the best attempts at natural positioning, strain on the shoulders is inevitable. It is the compression of nerves between the clavicle, first rib and head of humerus in the abduction position, with stretch on the plexus, that might best explain the CRPS that developed in the case outlined in this report (Figures 1 and 2).

CONCLUSION

Prolonged unnatural positioning during an operation, in this case with prolonged shoulder

abduction, resulted in a temporary ulnar nerve irritation and resulted in the development of CRPS. The association between such surgical positioning and CRPS may not yet have been presented.

REFERENCES

- [1] Stanton-Hicks M, Janig W, Hassenbusch S, Haddox JD, Boas R, Wilson P. Reflex sympathetic dystrophy: changing concepts and taxonomy. *Pain* 1995; 63(1): 127-33. [http://dx.doi.org/10.1016/0304-3959\(95\)00110-E](http://dx.doi.org/10.1016/0304-3959(95)00110-E)
- [2] Wasner G, Schattschneider J, Binder A, Baron R. Complex regional pain syndrome—diagnostic, mechanisms, CNS involvement and therapy. *Spinal Cord* 2003; 41(2): 61-75. <http://dx.doi.org/10.1038/sj.sc.3101404>
- [3] Harden RN, Bruehl S, Stanton-Hicks M, Wilson PR. Proposed new diagnostic criteria for complex regional pain syndrome. *Pain Med* 2007; 8(4): 326-31. <http://dx.doi.org/10.1111/j.1526-4637.2006.00169.x>
- [4] Galer BS, Bruehl S, Harden RN. IASP diagnostic criteria for complex regional pain syndrome: a preliminary empirical validation study. *International Association for the Study of Pain. Clin J Pain* 1998; 14(1): 48-54. <http://dx.doi.org/10.1097/00002508-199803000-00007>
- [5] Harden RN, Bruehl S, Perez RS, Birklein F, Marinus J, Maihofner C *et al.* Validation of proposed diagnostic criteria

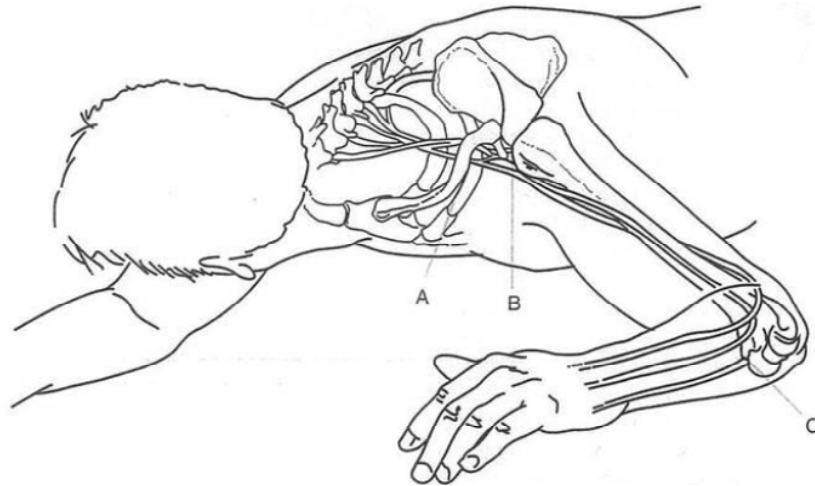


Figure 1: Intraoperative prone positioning [11].
A. rib cage, B. head of humerus, C. medial elbow compression.

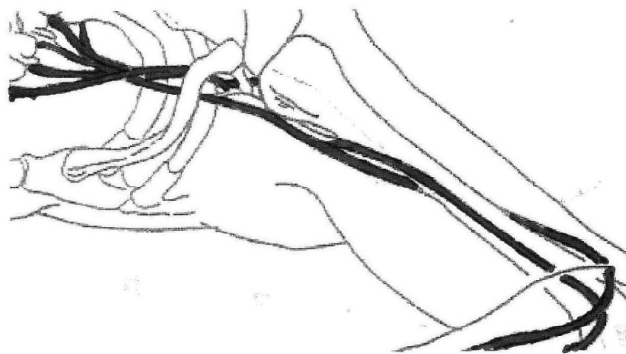


Figure 2: Brachial plexus stretch and nerve compressions between clavicle, rib cage and head of humerus [11].

- (the "Budapest Criteria") for Complex Regional Pain Syndrome. *Pain* 2010; 150(2): 268-74.
<http://dx.doi.org/10.1016/j.pain.2010.04.030>
- [6] Webster K. Peripheral nerve injuries and positioning for general anaesthesia. *Anaesthesia Tutorial of the Week*, 7 May 2012. Online article <http://www.frca.co.uk/Documents/258%20Peripheral%20Nerve%20Injuries%20and%20Positioning%20for%20Anaesthesia.pdf> (accessed 13 October 2016).
- [7] Kamel I, Barnette R. Positioning patients for spine surgery: Avoiding uncommon position-related complications. *World J Orthop* 2014 18; 5(4): 425-43.
- [8] De Passe JM, Palumbo MA, Haque M, Ebersson CP, Daniels AH. Complications associated with prone positioning in elective spinal surgery. *World J Orthop* 2015; 18; 6(3): 351-9.
- [9] Bernini PM, Simeone FA. Reflex sympathetic dystrophy associated with low lumbar disc herniation. *Spine (Phila Pa 1976)* 1981; 6(2): 180-4.
<http://dx.doi.org/10.1097/00007632-198103000-00014>
- [10] Weisz GM, Houang M, Bogduk N. Complex regional pain syndrome associated with cervical disc protrusion and foraminotomy. *Pain Med* 2010; 11(9): 1348-51.
<http://dx.doi.org/10.1111/j.1526-4637.2010.00925.x>
- [11] Sharma AD, Parmley CL, Sreeram G, Grocott HP. Peripheral nerve injuries during cardiac surgery: risk factors, diagnosis, prognosis, and prevention. *Anesth Analg* 2000; 91(6): 1358-69.
<http://dx.doi.org/10.1097/0000539-200012000-00010>

Received on 22-09-2016

Accepted on 14-10-2016

Published on 22-10-2016

<http://dx.doi.org/10.15379/2413-7324.2016.03.01>

© 2016 George M. Weisz; Licensee Cosmos Scholars Publishing House.

This is an open access article licensed under the terms of the Creative Commons Attribution Non-Commercial License

[\(http://creativecommons.org/licenses/by-nc/3.0/\)](http://creativecommons.org/licenses/by-nc/3.0/), which permits unrestricted, non-commercial use, distribution and reproduction in any medium, provided the work is properly cited.