

Cortico-Subcortical Metabolic Changes in Aging Brain: A ^{18}F FDG PET/CT Study

Agostino Chiaravalloti^{1,*}, Paolo Abbatiello¹, Ferdinando Calabria², Barbara Palumbo³, Alessandro Martorana⁴ and Orazio Schillaci^{1,2}

¹Department of Biomedicine and Prevention, University Tor Vergata, Rome, Italy

²IRCCS Neuromed, Pozzilli, Italy

³Department of Surgical and Biomedical Sciences, University of Perugia, Perugia, Italy

⁴Department of Neurosciences, University Tor Vergata, Rome, Italy

Abstract: *Aim:* to investigate the effects of aging on brain glucose consumption on a population of healthy subjects.

Materials and methods: 102 chemotherapy-naïve subjects (56 men, 46 women; mean age 57 ± 16 years old; age range 20-89 years) undergoing a whole body ^{18}F FDG PET/CT and found to be completely negative for various diseases in both PET/CT and contrast enhanced CT (performed contextually to PET/CT scan) were enrolled in the study. Age-related changes in brain ^{18}F -FDG uptake were analysed by statistical parametric mapping (SPM8).

Results: aging is related to a reduction of brain glucose consumption in right medial frontal gyrus (BA9) and anterior cingulate cortex (BA32) and to an increased ^{18}F -FDG uptake in right sub-cortical structures (lentiform nucleus, claustrum) and in cerebellum bilaterally.

Conclusions: The results of our study suggest that a reduced functioning of ACC and medial PFC occur in the elderly. An increased activation of the cerebellum, lentiform nucleus and claustrum may represent a compensatory mechanism, possibly involved in cognitive decline.

Keywords: Aging brain, Claustrum, Cingulate cortex, Prefrontal cortex, Cerebellum, PET/CT.

INTRODUCTION

A decrease in the volume of the brain is a common finding in post-mortem studies. In a postmortem stereological study of the human neocortex of 94 normal subjects, ranging from 19–93 years, a 10% global neuron loss in gray matter (GM) was recorded with age, showing no regional differences [1]. As far as white matter (WM) is concerned, a volume reduction and a ventricular enlargement in the aging brain has been repeatedly reported [2]. As a neuroimaging correlate, several Magnetic Resonance (MR) investigations have reported widespread age-related changes in GM and WM, particularly pronounced in the prefrontal region [3]. A cross-sectional study of 200 healthy adults aged 20–80 years reported 3–5% linear shrinkage per decade in the lateral and orbital prefrontal cortical regions, prefrontal WM, somatosensory cortex, and motor cortex [4].

The relationships between age and cerebral glucose metabolism have been repeatedly examined

using 2-deoxy-2-(^{18}F) fluoro-D-glucose (^{18}F -FDG) Positron Emission Tomography/Computed Tomography (PET/CT). The main finding is a reduced glucose consumption in the brain of the elderly. In particular few studies, mainly based on a qualitative image analysis, have not observed any age-dependent changes [5, 6] while the most of the published studies (usually performed with dedicated software that are able to improve the diagnostic accuracy [7]) show an age-dependent decline in glucose metabolism, especially in the ventral and dorsal lateral prefrontal/inferior frontal cortex, in the anterior cingulate cortex, in medial prefrontal areas and in precentral and perisylvian areas. Decreased metabolism is also reported in the caudate nuclei and the (superior) lateral temporal cortex [8-11]. Other studies found reduction of blood flow in the previously mentioned cortical regions as well [12].

To the best of our knowledge, few studies have been carried out in order to investigate an age-related increased brain glucose consumption. In their recently published study Shen *et al.* found increased glucose consumption in several sub cortical areas as the right lentiform nucleus, in the left thalamus, in the left paracentral lobule, in the right middle frontal gyrus and in the right precuneus [13]; hence the detection of age

*Address correspondence to this author at the Department of Biomedicine and Prevention, University Tor Vergata, Viale Oxford 81 00133 Rome, Italy; Tel.: +39 0620902418; Fax: +39 0620902469; E-mail: agostino.chiaravalloti@gmail.com

related areas of increased glucose consumption remains an unusual pattern.

The aim of our study was to investigate, in a large cohort of volunteers, the impact of aging on brain glucose consumption both in term of decreased or increased age-related ^{18}F -FDG brain uptake.

MATERIALS AND METHODS

Subjects

102 chemotherapy-naïve subjects (56 men, 46 women; mean age 57 ± 16 years old; age range 20-89 years) undergoing a whole body ^{18}F FDG PET/CT and found to be completely negative for various diseases in both PET/CT and contrast enhanced CT (performed contextually to PET/CT scan, see below) were enrolled in the study [14]. Of them, 96 were right handed and 6 left handed. A clinical examination was conducted by an experienced neurologist (A.M.) and Mini Mental State Examination (MMSE) did not reveal any cognitive deficit in all the subjects examined (a score greater than or equal to 27 points (out of 30) is considered normal) [15].

Subjects with diabetes, other oncologic or HIV history, neurological and psychiatric or mood disorders, history of surgery, radiation, trauma to the brain were excluded from the study. Moreover, we did not consider all the patients in treatment with drugs that could interfere with ^{18}F -FDG uptake and distribution in the brain [16]. No patient showed liver or renal suffering neither was pregnant or breastfeeding. Informed consent was obtained in all cases from the patients themselves in accordance with the Declaration of Helsinki. This study was approved by the local Ethics Committee.

Image Acquisition

The PET/CT system Discovery ST16 (GE Medical Systems, TN, USA) has been used to assess ^{18}F -FDG distribution in our study. The system combines a high-speed ultra 16-detector-row (912 detectors per row) CT unit and a PET scanner with 10080 bismuth germanate (BGO) crystals in 24 rings. Axial FWHM 1 cm radius 5,2 mm in 3D mode, axial FOV 157 mm. All the subjects fasted for at least 5 h before ^{18}F -FDG i.v. injection; serum glucose level was ≤ 120 mg/ml in all of them. All the subjects in our study were injected with 3 MBq/Kg (210–350 MBq) of ^{18}F -FDG i.v. and hydrated with 500 ml of i.v. saline sodium chloride (NaCl) 0.9%.

^{18}F -FDG was injected in a dedicated room for each subject with lights off. All the subjects were required to remain in resting conditions and eyes closed prior PET/CT scan. Brain PET/CT scan was performed placing patient's head in a dedicated support before whole body PET/CT examination. A low-ampere CT scan of the head for attenuation correction (40 mA; 120Kv) was performed before PET image acquisition. The duration of brain PET image set acquisition was 15 minutes in all the patients [16-18].

After whole body ^{18}F -FDG PET/CT examination, in the same exam session, a co-registered ceCT scan (120–140 kV, automatic milliamperage (limit 330–350mA), thickness 3.750 mm reconstructed at 1.25 mm, acquisition mode 27.50/1.375:1, gantry rotation time 0.6 s, large FOV, matrix 512×512) was carried out with i.v. administration of nonionic iodinated contrast material (100–120 ml, 370 mg/ml, 420 mg/kg at 3 ml/s), obtaining two successive stacks of scans. The first comprised the upper abdomen with a 30-s delay from the injection onset; the second extended from the neck to the pelvis with a 60-s delay. Brain ceCT was also obtained 3 minutes after i.v. contrast administration [19].

Image Processing

All the images have been acquired in a 3D-mode standard technique in a 256×256 matrix. Reconstruction has been performed using the 3-dimensional reconstruction method of ordered-subsets expectation maximization (OSEM) with 20 subsets and with 4 iterations.

^{18}F -FDG PET data have been subjected to affine and non-linear spatial normalization into the MNI space. The spatially normalized set of images were then smoothed with a 8-12 mm isotropic Gaussian filter to blur for individual variations in gyral anatomy and to increase the signal-to-noise ratio. Images have been globally normalized to 50 using proportional scaling to remove confounding effects to global cerebral glucose consumption changes, with a masking threshold of 0.8. The resulting statistical parametric maps, SPM [t], have been transformed into normal distribution (SPM [z]) unit. Correction of SPM coordinates to match the Talairach coordinates was achieved by the subroutine implemented by Matthew Brett (<http://www.mrc-cbu.cam.ac.uk/Imaging>). Brodmann areas (BAs) have been then identified at a range of 0 to 3 mm from the corrected Talairach coordinates of the SPM output isocentres, after importing the corrected coordinates,

by Talairach client (<http://www.talairach.org/index.html>). Following on Bennett *et al.* [20] argument, SPM t-maps have been thresholded at $p < 0.05$, corrected for multiple comparisons with the False Discovery Rate (FDR) option at voxel level and at $p < 0.01$ corrected for multiple comparison at cluster level.

STATISTICAL ANALYSIS

Relationships between brain ¹⁸F-FDG uptake and age have been analyzed using statistical parametric mapping (SPM8, Wellcome Department of Cognitive Neurology, London, UK) implemented in Matlab 6.5 (Mathworks, Natick, Massachusset, USA). MMSE did not reveal any cognitive impairment in our series (see below). Nevertheless we observed a slightly higher score in young subject and, also if this difference did not reach the statistical significance (see below), we used MMSE score together with handedness as a covariate in regression analysis. Only those clusters containing more than 1000 (5x5x5 voxels, *i.e.* 11x11x11 mm) contiguous voxels have been accepted as significant. The voxel-based analyses have been

performed using a ‘regression analysis’ design model. The age regression factors have been assessed. In SPM maps, we searched the brain areas with a significant correlation using a statistical threshold of $P=0:01$, family wise error (FWE)-corrected for the problem of multiple comparisons, with an extent threshold of 1000 voxels.

Linear regression analysis has been used in order to investigate the relationship between MMSE and age.

RESULTS

MMSE score was > 27 in all the subjects examined (mean value 29 ± 1). As shown in Table 1 and Figure 1, aging is related to a reduction of brain glucose consumption in right Brodmann area (BA) 9 (medial frontal gyrus) and anterior cingulate cortex (ACC,BA32) and to an increased ¹⁸F-FDG uptake in right sub-cortical structures (lentiform nucleus, claustrum) and in cerebellum bilaterally (Table 2, Figure 2). We did not find any significant relationship between age and MMSE score ($r^2 = 0.05522$; $P = 0.1615$).

Table 1: Linear Regression Analysis Showing the Age-Related Areas of Reduced ¹⁸F FDG Brain Uptake

Analysis	Cluster Level					Voxel Level		
	Cluster p(FWE-corr)	Cluster p(FDR-corr)	Cluster extent	Cortical Region	Z score of maximum	Talairach coordinates	Cortical region	BA
Negative correlation	0.00	0.00	3068	Right frontal lobe	6.81	4,52,20	Medial frontal gyrus	9
				Right frontal lobe	6.55	2,44,16	Medial frontal gyrus	9
				Right limbic lobe	6.41	2,30,32	Cingulate gyrus	32

*In the ‘cluster level’ section on left, the number of voxels, the corrected P value of significance and the cortical region where the voxel is found, are all reported for each significant cluster. In the ‘voxel level’ section, all of the coordinates of the correlation sites (with the Z-score of the maximum correlation point), the corresponding cortical region and BA are reported for each significant cluster. L, left; R, right; BA, Brodmann’s area. In the case that the maximum correlation is achieved outside the grey matter, the nearest grey matter (within a range of 5mm) is indicated with the corresponding BA

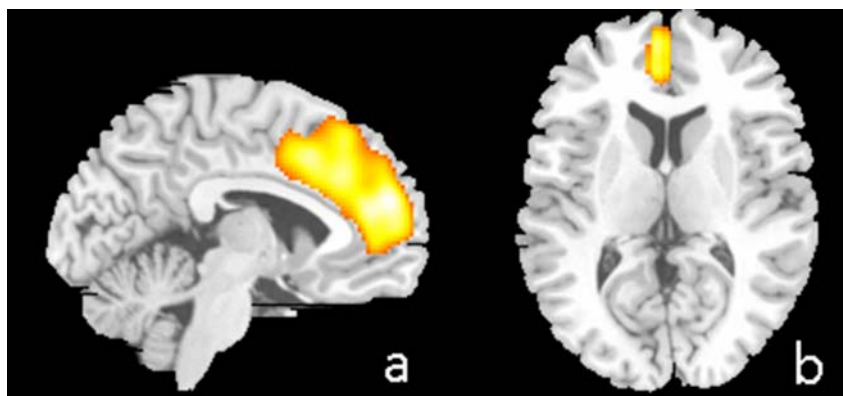


Figure 1: T1 MR superimposition showing age-related lower ¹⁸F-FDG uptake in right medial frontal gyrus and anterior cingulate cortex. (a): sagittal view; (b) axial view. Threshold $P < 0.001$ (corrected for multiple comparisons at the voxel level). Coordinate and regional details are presented in Table 1. ¹⁸F-FDG, 2-deoxy-2- [¹⁸F]fluoro-D-glucose.

Table 2: Linear Regression Analysis Showing the Age-Related Areas of Increased ^{18}F FDG Brain Uptake

Analysis	Cluster Level					Voxel Level	
	Cluster p(FWE-corr)	Cluster p(FDR-corr)	Cluster extent	Cortical Region	Z score of maximum	Talairach coordinates	Cortical region
Positive correlation	0.00	0.00	1147	Right cerebrum	7.50	22,-16,4	Lentiform nucleus
				Right cerebrum	7.46	18,-12,-4	Lentiform nucleus
				Right cerebrum	5.56	28,4,18	Clastrum
	0.00	0.00	1774	Left cerebellum	7.05	-22,-66,-44	Inferior semi-lunar lobule
				Right cerebellum	5.32	-8,-38,-38	Cerebellar tonsil
	0.00	0.00	1138	Right cerebellum	6.37	22,-68,-42	Inferior semi-lunar lobule
				Right cerebellum	6.20	26,-56,-44	Cerebellar tonsil
				Right cerebellum	6.00	18,-62,-46	Inferior semi-lunar lobule

*In the 'cluster level' section on left, the number of voxels, the corrected P value of significance and the cortical region where the voxel is found, are all reported for each significant cluster. In the 'voxel level' section, all of the coordinates of the correlation sites (with the Z-score of the maximum correlation point), the corresponding sub cortical region is reported for each significant cluster. L, left; R, right.

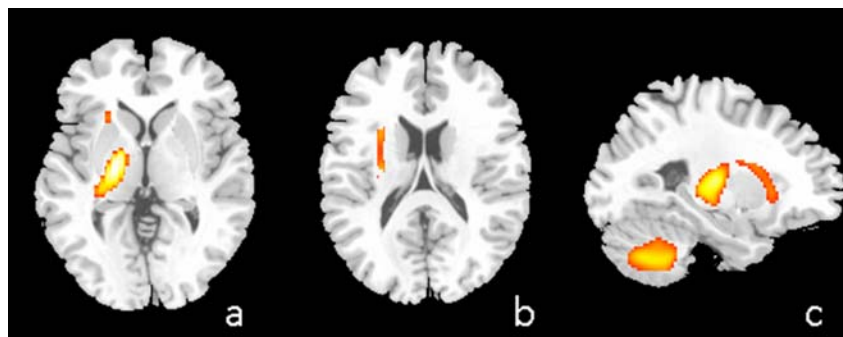


Figure 2: T1 MR superimposition showing age-related increased ^{18}F -FDG uptake in right lentiform nucleus (a), in the right claustrum (b) and in the cerebellum (c). Threshold $P < 0.001$ (corrected for multiple comparisons at the voxel level). Coordinate and regional details are presented in Table 2. ^{18}F -FDG, 2-deoxy-2- [^{18}F]fluoro-D-glucose.

DISCUSSION

One of the main findings of our study is an age-related reduction of glucose consumption in right prefrontal cortex (PFC) and ACC (BA9 and 32) as shown in Table 2 and Figure 1. Cerebral glucose metabolism is mainly related to glucose consumption in neural cells due to synaptic activity [21], hence the reduced glucose consumption observed is consistent with an age related dysfunction in BA9 and BA32. Our findings are in agreement with several investigators reporting an age-related reduction in synaptic density or in synaptic count in the human cerebral cortex, and such reductions have most consistently been reported in the frontal neocortex [22-24].

While, mainly due to postmortem and *in vivo* studies, it is well known that brains of older adults to

have lower volumes of gray matter than the brains of younger adults [25-26], it is still matter of debate why the changes in regional volume are not uniform. It has been shown that some regions as the PFC, show significant changes in volume, while other regions mainly involved with sensory processing (*i.e.* the occipital cortex) are relatively unaffected by normal aging [26-27]. In PFC and average volume loss of approximately 5% per decade after the age of 20 has been estimated [4].

Several works functional studies performed in human demonstrated that the mid-dorsolateral frontal cortex, which comprises cytoarchitectonic BA 46 and 9, plays a critical role in the performance of non-spatial self-ordered working memory tasks [28] and a recently published study by Campbell *et al.* has shown that

older adults present weaker connectivity in the dorso-medial PFC subsystems and stronger connectivity than younger adults in the dorsal PCC subsystem which included areas involved in cognitive control [29]. These latter findings are interesting since support prior evidence that the connectivity of default mode network (a network of brain regions that are active when the individual is not focused on the outside world and the brain is at wakeful rest) is particularly vulnerable to age, whereas connectivity involving cognitive control regions is relatively maintained suggesting an age difference in the integrated activity among brain networks that can have implications for cognition in older adults [29]. Of interest, behavioural studies revealed that older adults perform nearly as well as younger subjects on maintenance tasks, but age-related declines are observed during tasks requiring online manipulation of information [30]. The finding of a reduced glucose consumption in PFC in our study cohort is in agreement with studies showing declines of working memory performance in older adults often supported by neuroimaging findings of concomitant age-related changes in prefrontal activation [31-32].

An age-related reduction of brain glucose consumption in ACC is well known [33]. In their study performed on 46 subjects, Pardo *et al.* reported a reduction of glucose consumption in three medial regions: ACC; the subgenual cingulate cortex/basal forebrain and the dorsomedial thalamus. The authors concluded that the metabolic pattern observed may represent a functional correlate of a cortical atrophy detectable in MR studies [33]. Another possible explanation of a reduced brain glucose consumption in BA 32 can be sought in the active role of this structure in the working memory process, being this structure actively involved during memory tasks [34]. Again, the results of the previously mentioned studies concerning behavioural and imaging changes in older subjects as compared to younger may explain the age-related reduced cortical activity in BA32 in our study cohort.

These assumptions are for the time being speculative, as the present study was limited to functional findings and aimed at evaluating the possibility of any age-related brain alterations. Hence, its main limitation is the lack of a deep neuropsychological evaluation of higher cognitive domains. It will be necessary for future studies to include longitudinal assessments of neuropsychological performance before the administration of systemic therapies, as well as an appropriate follow-up.

In disagreement with other similar report in this field our findings show an increased rather than a decreased ¹⁸F-FDG uptake in several sub-cortical areas, mainly in the cerebellum (Table 2, Figure 2). Several studies show that cerebellar volume declines with age (mainly due to Purkinje cell loss) [35]. Volumetric MRI studies found a significant volume loss in the cerebellum with age, especially in the vermis [36]. Although uncommon, the findings shown in Table 2 and Figure 2 findings are not surprising. Scarmeas *et al.* suggested that the age-related increase of metabolism in some regions may be interpreted to compensate for the regions of metabolism decline to cope with the decrease of brain function in a memory condition [37]. The striatum is heavily involved in dopaminergic circuits connecting to the PFC; moreover it is now clear that the site of termination of cerebellar efferent is not restricted to the thalamus [38], that there is physiological evidence that the activity of neurons in selected regions of the cerebellum is related more to cognitive aspects of performance [39] and that cerebellar lesions can result in cognitive as well as motor deficits [40]. As far as the claustrum is concerned, the function of this structure remains still mostly unknown. Connectivity studies have shown that the claustrum plays a strong role in communication between the two hemispheres of the brain, specifically between cortical regions controlling attention [41]. Though the precise role of these interhemispheric circuits is not yet understood, it is possible that one goal is to create a common timescale between the two hemispheres, to achieve a seamless unity of attention/consciousness between processing in each hemisphere [41].

On the basis of these scientific evidences, the over-activation of the sub cortical structures shown in Figure 2 may represent a compensatory mechanism, possibly involved in cognitive decline. In this respect the lack of a neuropsychological evaluation of the population examined is an evident limitation of the study but encourages further studies in this direction.

CONCLUSIONS

The results of our study suggest that a reduced functioning of ACC and medial PFC occur in elderly. On the other hand, our data suggest an increased activation of several subcortical structures, mainly in the cerebellum that may represent a compensatory mechanism, possibly involved in cognitive decline.

REFERENCES

- [1] Pakkenberg B, Gundersen HJ. Neocortical neuron number in humans: effect of sex and age. *J Comp Neurol.* 1997; 384:312-20.
- [2] Piguet O, Double KL, Kril JJ, Harasty J, Macdonald V, McRitchie DA, et al. White matter loss in healthy ageing: a postmortem analysis. *Neurobiol Aging.* 2009;30:1288-95.
- [3] Rettmann ME, Kraut MA, Prince JL, Resnick SM. Cross-sectional and longitudinal analyses of anatomical sulcal changes associated with aging. *Cereb Cortex.* 2006;16:1584-94.
- [4] Raz N, Gunning-Dixon F, Head D, Rodrigue KM, Williamson A, Acker JD. Aging, sexual dimorphism, and hemispheric asymmetry of the cerebral cortex: replicability of regional differences in volume. *Neurobiol Aging.* 2004;25:377-96.
- [5] Hawkins RA, Mazziotta JC, Phelps ME, Huang SC, Kuhl DE, Carson RE, et al. Cerebral glucose metabolism as a function of age in man: influence of the rate constants in the fluorodeoxyglucose method. *J Cereb Blood Flow Metab.* 1983;3:250-3.
- [6] de Leon MJ, George AE, Ferris SH, Christman DR, Fowler JS, Gentes CI, et al. Positron emission tomography and computed tomography assessments of the aging human brain. *J Comput Assist Tomogr.* 1984;8:88-94.
- [7] Chiaravalloti A, Schillaci O. 18F-FDG and amyloid PET imaging in Alzheimer's disease. *J Alzheimers Dis.* 2012;29:13-5. doi:10.3233/JAD-2012-129000.
- [8] Salmon E, Maquet P, Sadzot B, Degueldre C, Lemaire C, Franck G. Decrease of frontal metabolism demonstrated by positron emission tomography in a population of healthy elderly volunteers. *Acta Neurol Belg.* 1991;91:288-95.
- [9] Petit-Taboué MC, Landeau B, Desson JF, Desgranges B, Baron JC. Effects of healthy aging on the regional cerebral metabolic rate of glucose assessed with statistical parametric mapping. *Neuroimage.* 1998;7:176-84.
- [10] Herholz K, Salmon E, Perani D, Baron JC, Holthoff V, Frolich L, et al. Discrimination between Alzheimer dementia and controls by automated analysis of multicenter FDG PET. *Neuroimage.* 2002;17:302-16.
- [11] Hsieh TC, Lin WY, Ding HJ, Sun SS, Wu YC, Yen KY, et al. Sex- and age-related differences in brain FDG metabolism of healthy adults: an SPM analysis. *J Neuroimaging.* 2012;22:21-7.
- [12] Aanerud J, Borghammer P, Chakravarty MM, Vang K, Rodell AB, Jonsdottir KY, et al. Brain energy metabolism and blood flow differences in healthy aging. *J Cereb Blood Flow Metab.* 2012;32:1177-87.
- [13] Shen X, Liu H, Hu Z, Hu H, Shi P. The relationship between cerebral glucose metabolism and age: report of a large brain PET data set. *PLoS One.* 2012;7:20.
- [14] Cistaro A, Valentini MC, Chiò A, Nobili F, Calvo A, Moglia C, et al. Positron Emission Tomography discriminates bulbar and spinal onset in Amyotrophic Lateral Sclerosis. *Eur J Nuc Med Mol Imaging.* 2011;39:251-9.
- [15] Folstein MF, Folstein SE, McHugh PR. "Mini-mental state". A practical method for grading the cognitive state of patients for the clinician. *J Psychiatr Res.* 1975;12:189-98.
- [16] Chiaravalloti A, Pagani M, Di Pietro B, Danieli R, Tavolozza M, Travascio L, et al. Is cerebral glucose metabolism affected by chemotherapy in patients with Hodgkin's lymphoma? *Nucl Med Commun.* 2013;34:57-63.
- [17] Schillaci O, Chiaravalloti A, Travascio L, Floris R, Simonetti G. F-FDG PET/MR in herpes simplex virus encephalitis: A case study. *Rev Esp Med Nucl Imagen Mol.* 2014;2:00183-2.
- [18] Alessandrini M, Pagani M, Napolitano B, Micarelli A, Candidi M, Bruno E, et al. Early and phasic cortical metabolic changes in vestibular neuritis onset. *PLoS One.* 2013;8:7.
- [19] Chiaravalloti A, Danieli R, Abbatiello P, Di Pietro B, Travascio L, Cantonetti M, et al. Factors affecting intrapatient liver and mediastinal blood pool F-FDG standardized uptake value changes during ABVD chemotherapy in Hodgkin's lymphoma. *Eur J Nucl Med Mol Imaging.* 2014;22:22.
- [20] Bennett CM, Wolford GL, Miller MB. The principled control of false 483 positives in neuroimaging. *Soc Cogn Affect Neurosci.* 2009;22:2233-9.
- [21] Kadekaro M, Crane AM, Sokoloff L. Differential effects of electrical stimulation of sciatic nerve on metabolic activity in spinal cord and dorsal root ganglion in the rat. *Proc Natl Acad Sci U S A.* 1985;82:6010-3.
- [22] Scheibel ME, Lindsay RD, Tomiyasu U, Scheibel AB. Progressive dendritic changes in aging human cortex. *Exp Neurol.* 1975;47:392-403.
- [23] Liu X, Erikson C, Brun A. Cortical synaptic changes and gliosis in normal aging, Alzheimer's disease and frontal lobe degeneration. *Dementia.* 1996;7:128-34.
- [24] Terry RD, DeTeresa R, Hansen LA. Neocortical cell counts in normal human adult aging. *Ann Neurol.* 1987;21:530-9.
- [25] Haug H, Eggers R. Morphometry of the human cortex cerebri and corpus striatum during aging. *Neurobiol Aging.* 1991;12:336-8.
- [26] Resnick SM, Pham DL, Kraut MA, Zonderman AB, Davatzikos C. Longitudinal magnetic resonance imaging studies of older adults: a shrinking brain. *J Neurosci.* 2003;23:3295-301.
- [27] Raz N, Lindenberger U, Rodrigue KM, Kennedy KM, Head D, Williamson A, et al. Regional brain changes in aging healthy adults: general trends, individual differences and modifiers. *Cereb Cortex.* 2005;15:1676-89.
- [28] Petrides M, Alivisatos B, Evans AC, Meyer E. Dissociation of human mid-dorsolateral from posterior dorsolateral frontal cortex in memory processing. *Proc Natl Acad Sci U S A.* 1993;90:873-7.
- [29] Campbell KL, Grigg O, Saverino C, Churchill N, Grady CL. Age differences in the intrinsic functional connectivity of default network subsystems. *Front Aging Neurosci.* 2013;5.
- [30] Gregoire J, Van der Linden M. Effects of age on forward and backward digit spans. *Aging Neuropsych Cogn.* 1997;4:140.
- [31] Cabeza R, Daselaar SM, Dolcos F, Prince SE, Budde M, Nyberg L. Task-independent and task-specific age effects on brain activity during working memory, visual attention and episodic retrieval. *Cereb Cortex.* 2004;14:364-75.
- [32] Rypma B, Prabhakaran V, Desmond JE, Gabrieli JD. Age differences in prefrontal cortical activity in working memory. *Psychol Aging.* 2001;16:371-84.
- [33] Pardo JV, Lee JT, Sheikh SA, Surerus-Johnson C, Shah H, Munch KR, et al. Where the Brain Grows Old: Decline in Anterior Cingulate and Medial Prefrontal Function with Normal Aging. *Neuroimage.* 2007;35:1231-7.
- [34] Lenartowicz A, McIntosh AR. The role of anterior cingulate cortex in working memory is shaped by functional connectivity. *J Cogn Neurosci.* 2005;17:1026-42.
- [35] Andersen BB, Gundersen HJ, Pakkenberg B. Aging of the human cerebellum: a stereological study. *J Comp Neurol.* 2003;466:356-65.
- [36] Luft AR, Skalej M, Schulz JB, Welte D, Kolb R, Burk K, et al. Patterns of age-related shrinkage in cerebellum and brainstem observed *in vivo* using three-dimensional MRI volumetry. *Cereb Cortex.* 1999;9:712-21.
- [37] Scarmeas N, Zarahn E, Anderson KE, Hilton J, Flynn J, Van Heertum RL, et al. Cognitive reserve modulates functional brain responses during memory tasks: a PET study in healthy young and elderly subjects. *Neuroimage.* 2003;19:1215-27.
- [38] Sakai ST, Inase M, Tanji J. Comparison of cerebellothalamic and pallidothalamic projections in the monkey (*Macaca fuscata*): a double anterograde labeling study. *J Comp Neurol.* 1996;368:215-28.

- [39] Middleton FA, Strick PL. Dentate output channels: motor and cognitive components. *Prog Brain Res.* 1997;114:553-66.
- [40] Schmahmann JD, Sherman JC. The cerebellar cognitive affective syndrome. *Brain.* 1998;121:561-79.
- [41] Smith JB, Alloway KD. Functional specificity of claustrum connections in the rat: interhemispheric communication between specific parts of motor cortex. *J Neurosci.* 2010;30:16832-44.

Received on 29-04-2014

Accepted on 12-05-2014

Published on 12-08-2014

© 2014 Chiaravalloti *et al.*; Licensee Cosmos Scholars Publishing House.

This is an open access article licensed under the terms of the Creative Commons Attribution Non-Commercial License (<http://creativecommons.org/licenses/by-nc/3.0/>), which permits unrestricted, non-commercial use, distribution and reproduction in any medium, provided the work is properly cited.