

# Detection of Renal Vein and Inferior Vena Cava Thrombosis from Renal Cell Carcinoma by F-18 FDG PET/CT in Two Patients

Koramadai Karuppusamy Kamaleshwaran\*, Chakraborty Dhritiman, Bhattacharya Anish and Mittal Bhagwant Rai

*Department of Nuclear Medicine and PET/CT, Postgraduate Institute of Medical Education & Research (PGIMER), Chandigarh-160012, India*

**Abstract:** Tumour thrombosis is a relatively rare complication of solid cancers, with occult inferior vena cava(IVC) tumour thrombosis having a reported incidence rate of 0.11%. Renal cell carcinoma(RCC) has a propensity to extend as tumour thrombus into the renal vein and IVC. The preoperative assessment for the presence and extent of renal vein and IVC tumour thrombus is important for planning appropriate surgical resection. There are reports having described the diagnosis of tumour thrombosis by Fluorine-18 fluorodeoxyglucose positron emission tomography and Computed tomography (F-18 FDG PET/CT). We present two cases, one with right RCC showing renal vein and IVC tumour invasion and another left RCC with renal vein, IVC and hepatic vein thrombosis detected using FDG PET/CT.

**Keywords:** RCC, FDG PET/CT, Tumour thrombus, IVC.

## INTRODUCTION

Tumour thrombus is one of the rare complications of renal cell carcinoma (RCC), Wilm's tumour, testicular tumour, adrenal cortical carcinoma, lymphoma, pancreatic cancer, osteosarcoma, Ewing's sarcoma and hepatocellular carcinoma [1]. RCC is an aggressive neoplasm with potential dissemination to the renal veins and IVC in 24% and 12% of all cases, respectively [2]. In a few instances, RCC venous extension may go beyond the IVC, reaching the hepatic vein and even right atrium. RCC venous involvement carries a serious outcome prognosis and necessitates an in-depth imaging evaluation and staging before surgery and thrombectomy [3]. The diagnosis is usually made accidentally during staging investigations. Recent introduction of FDG PET/CT technology has revolutionized by fusing functional and anatomical criteria for staging of most cancers, thus allowing accurate anatomical localization of tumour spread and providing the ability to differentiate between tumour and blood thrombus [4].

## CASE 1

60 yr old male presented with pain in left flank, loss of weight for 3 weeks. He underwent Contrast enhanced CT abdomen for suspicion of RCC which revealed left renal mass with thrombosis in left renal vein and IVC. FDG PET/CT was performed for staging and differentiating tumour thrombus and bland

thrombus. Diffuse FDG uptake extending from the left kidney medially and superiorly to the level of the diaphragm corresponded with IVC abnormalities on CT. FDG uptake on PET/CT supported the presence of tumour thrombus in the left renal vein and IVC. The patient underwent a thoraco-abdominal nephrectomy, with RCC and thrombus in the left hepatic vein and IVC confirmed during surgery.

## CASE 2

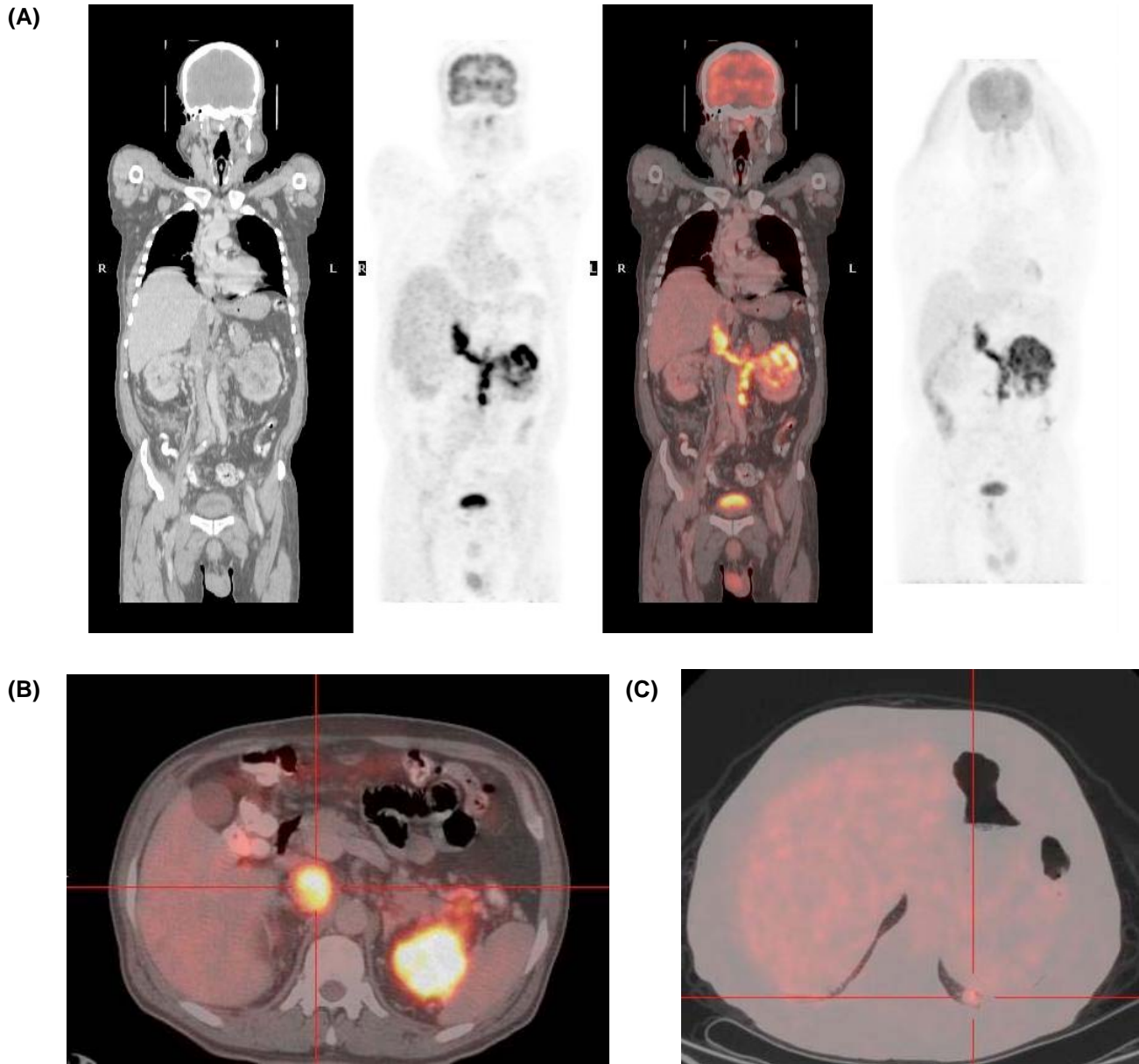
71 yrs old male presented with left flank pain for 1 week. He underwent Contrast enhanced CT abdomen which revealed lobulated hypodense lesion at the upper pole of left kidney with enlarged IVC and left renal vein suggestive of thrombosis. He was referred for FDG PET/CT for initial staging which showed intense FDG uptake in the upper pole of left kidney with extending medially and superiorly to the level of the diaphragm and in the liver which supported the diagnosis of left renal vein, IVC and unsuspected right hepatic vein thrombosis. He underwent nephrectomy with tumour thrombus removal in IVC and hepatic vein.

## DISCUSSION

Venous thromboembolism (VTE) is a well-recognized and relatively frequent complication of malignancy. Tumour thrombosis, in contrast, is a rare complication of solid cancers such as colon, pancreas, hepatocellular carcinoma and RCC, and has also been described in lymphoma and sarcoma [4]. The correct diagnosis of tumour thrombosis and its differentiation from VTE can alter patient management and prevent unnecessary long-term anticoagulation treatment. RCC

\*Address correspondence to this author at the Department of Nuclear Medicine and PET/CT, Postgraduate Institute of Medical Education & Research (PGIMER), Chandigarh-160012, India; Tel: 0091-172-2756730; Fax: 0091-172-2744401; E-mail: dr.kamaleshwar@gmail.com

Case 1.



**Figure 1.** Coronal CT, PET, Fused FDG PET/CT and Maximum intensity projection (MIP) images.

(A) after intravenous administration of 10 mCi of F-18 FDG demonstrate a rim of enhanced FDG uptake surrounding a photopenic mass in the upper part right kidney. Additional activity extending medially and superiorly to the level of the diaphragm.

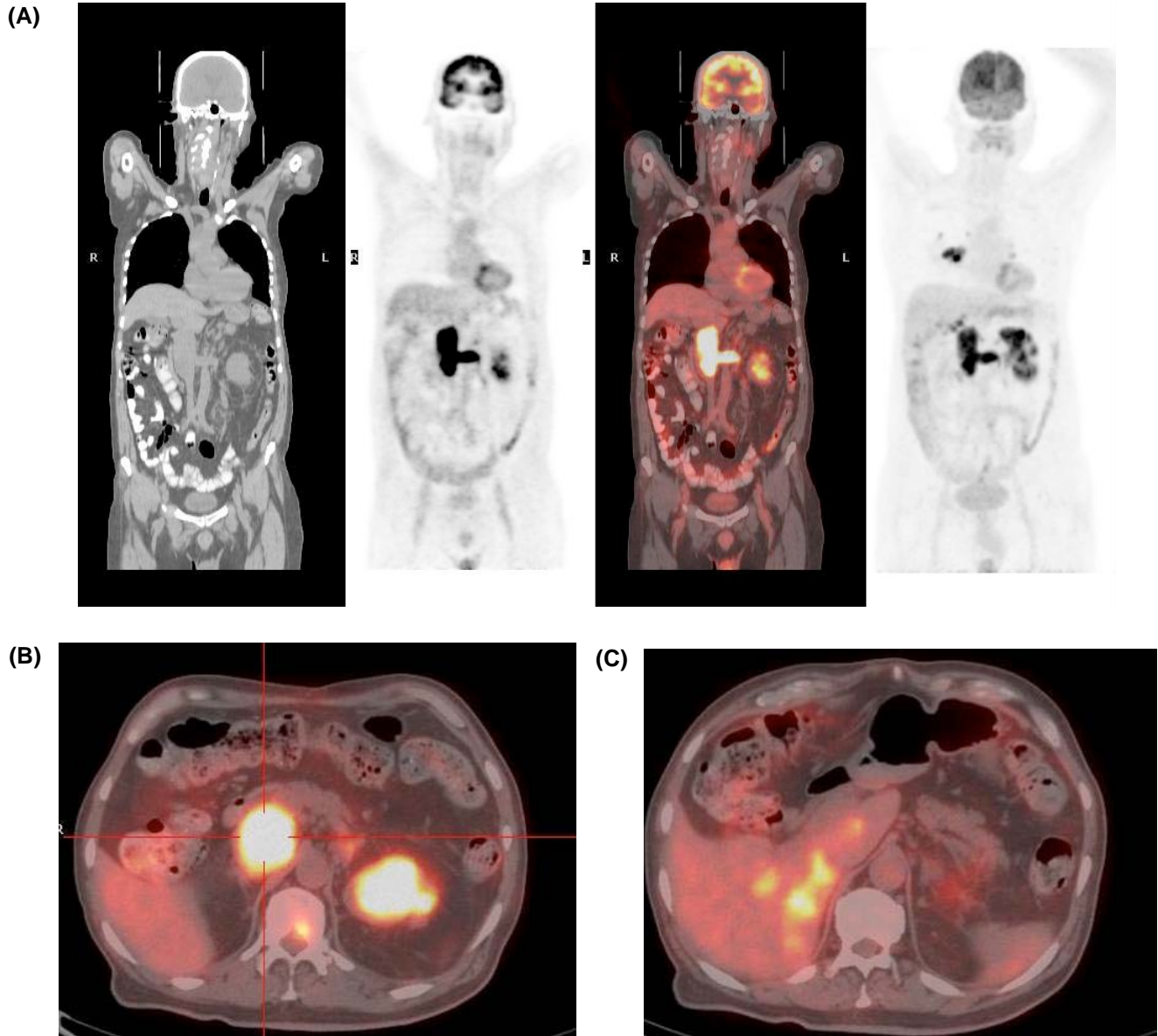
Axial images (B) from Fused FDG PET/CT demonstrate enhanced FDG uptake in a dilated segment of the inferior vena cava. The enhanced FDG activity on PET/CT with maximum standardized uptake value (SUVmax) of 21 with heterogeneous material in a dilated inferior vena cava, suggesting tumour thrombus.

Axial images (C) from fused FDG PET/CT demonstrate another focus of increased uptake to the unsuspected nodule in the left lower lobe of lung suggestive of metastasis.

is an aggressive neoplasm with potential dissemination to the renal veins and IVC in 24% and 12% of all cases, respectively [5]. Accurate tumour staging in patients with RCC is essential before surgical management. Extension of tumour thrombus into the

renal vein or IVC is a known complication of RCC with significant prognostic and therapeutic implications. Thrombus extension above the diaphragm and into the right atrium may require thoracotomy and resection of affected vena cava segments in addition to

Case 2.



**Figure 2.** Coronal CT, PET, Fused FDG PET/CT and Maximum intensity projection (MIP) images (A) demonstrate intense FDG uptake in the upper pole of left kidney. Additional activity extending medially and superiorly to the level of the diaphragm and into liver is also seen. Another focus is noted in right hilar region suggestive of mediastinal nodal metastasis.

Axial images (B) from fused FDG PET/CT demonstrate intense FDG uptake in a dilated segment of the IVC. FDG activity on FDG PET/CT with maximum standardized uptake value (SUVmax) of 34 corresponds to CT findings of dilated left renal vein and IVC suggesting tumour thrombus. Also vertebral uptake showing bone metastasis.

Axial images (C) of fused PET/CT shows FDG uptake with maximum standardized uptake value (SUVmax) of 24 in the liver which corresponds to the right hepatic vein suggestive of thrombosis.

nephrectomy [6]. Patients with RCC may also be hypercoagulable and develop bland caval thrombus that may not require caval resection or thrombectomy. Distinguishing between these 2 entities is not usually possible with enhanced computerized tomography (CT) or magnetic resonance imaging [7].

FDG PET/CT imaging is limited in the identification of primary urologic neoplasms resulting from the proximity of physiological radiotracer uptake in the normal genitourinary system. However, FDG PET/CT is capable of detecting regional and distant urologic metastases presenting with a better target-to-background signal ratio away from physiological foci of

F-18 FDG accumulation [8]. Only sporadic reports have described the diagnosis of tumour thrombosis by positron emission tomography with 18F-fluorodeoxyglucose [9,10]. Positive FDG PET/CT demonstration of venous tumour thrombus has been previously reported in IVC related to RCC [11] Although only limited data exist in the literature, it appears that 18F-FDG-PET scans can be used to accurately differentiate between septic and aseptic deep vein thrombosis [12]. Septic lesions have increased uptake of 18-FDG, whereas aseptic deep vein thromboses have been reported to exhibit normal biodistribution of the agent. These findings were the basis for the assumption that FDG imaging by PET/CT may differentiate between tumour thrombosis and VTE as well. Davidson *et al.* [13] described Accuracy of FDG PET/CT to differentiate between tumour thrombosis and benign VTE was 100% in a small study. Sharma *et al.* [14] recently described 24 patients with tumour thrombus of different etiology and concluded that the mean maximum standardized uptake value (SUVmax) was 3.2 (range: 2.3-4.6; median: 3.3) in the benign thrombosis group and was 6.0 (range: 2.3- 13.8; median: 3.3) in the tumour thrombosis group and FDG PET-CT can detect active tumour thrombosis and is helpful in differentiating it from benign thrombus. Our patients had SUVmax of 21 and 34 which help in accurately differentiate tumour thrombus.

## CONCLUSION

FDG PET/CT accurately differentiated tumour thrombosis from benign venous thrombi in our patients. FDG PET/CT appears to be beneficial in the diagnosis of occult tumour thrombosis and may be used as a non-invasive tool to characterize suspicious thrombotic lesions, both above and below the diaphragm. By furthering the diagnosis and recognition of tumour thrombi by PET/CT may consequently improve patient management. These case serves as a reminder that special attention should always be paid to the IVC and adjoining venous drainage pathways for abnormal FDG activity, particularly when imaging RCC, as the

diagnosis of venous tumour thrombus has important clinical ramifications.

## REFERENCES

- [1] Baron JA, Gridley G, Weiderpass E *et al.* Venous thromboembolism and cancer. *Lancet* 1998;351:1077-1080.
- [2] Zisman A, Wieder JA, Pantuck AJ, *et al.* Renal cell carcinoma with tumor thrombus extension: biology, role of nephrectomy and response to immunotherapy. *J Urol.* 2003; 169:909.
- [3] Gupta NP, Ansari MS, Khaitan A, *et al.* Impact of imaging and thrombus level in management of renal cell carcinoma extending to veins. *Urol Int.* 2004; 72:129.
- [4] Lai P, Bomanji JB, Mahmood S *et al.* Detection of tumour thrombus by 18F-FDG-PET/CT imaging. *Eur J Cancer Prev* 2007; 16: 90-94.
- [5] Sizemore AW, Jacobs MP, Mantil JC *et al.* FDG uptake in inferior vena cava tumor thrombus from renal cell carcinoma on positron emission tomography. *Clin Nucl Med* 2007; 32(4): 309-311.
- [6] Vaidya A, Ciancio G, Soloway M. Surgical techniques for treating a renal neoplasm invading the inferior vena cava. *J Urol.* 2003;169:435-444.
- [7] Hallscheidt PJ, Fink C, Haferkamp A, *et al.* Preoperative staging of renal cell carcinoma with inferior vena cava thrombus using multidetector CT and MRI: prospective study with histopathological correlation. *J Comput Assist Tomogr.* 2005; 29:64-68.
- [8] Kang DE, White RLJ, Zuger JH, *et al.* Clinical use of fluorodeoxyglucose F 18 positron emission tomography for detection of renal cell carcinoma. *J Urol.* 2004; 171:1806 - 1809.
- [9] Nguyen BD. Pancreatic neuroendocrine tumor with portal vein tumor thrombus: PET demonstration. *Clin Nucl Med* 2005; 30(9): 628-629.
- [10] Gupta P, Kramer EL, Ponzio F. FDG uptake in tumor thrombus in inferior vena cava from rectal cancer on positron emission tomography. *Clin Nucl Med* 2005; 30(5): 342-343.
- [11] Hain SF, Gleadle J, Maisey MN. F-18 fluorodeoxyglucose PET in the diagnosis of vascular invasion in renal cell carcinoma. *Clin Nucl Med.* 1999; 24:819.
- [12] Do B, M ari C, Biswal S *et al.* Diagnosis of aseptic deep venous thrombosis of the upper extremity in a cancer patient using fluorine-18 fluorodeoxyglucose positron emission tomography/computerized tomography (FDG PET-CT) *Ann Nucl M ed.* 2006; 20:151-155.
- [13] Davidson T, Goitein O, Avigdor A, *et al.* 18F- FDG-PET/CT for the diagnosis of tumor thrombosis. *IMAJ.* 2009; 11:69 -73.
- [14] Sharma P, Kumar R, Jeph S, Karunanithi S *et al.* 18F-FDG PET-CT in the diagnosis of tumor thrombus: can it be differentiated from benign thrombus? *Nucl Med Commun.* 2011 Sep; 32 (9): 782-788.