

Protective Effects of Aqueous Extract of *Allium Sativum* (Garlic) On the Histomorphology and Biochemical Parameters of Lead -Induced Cerebellar Injury on the Adult Male Wistar Rats

Augustine U Agu¹, Samuel C Chime^{2*}, Kelechi Duru³, Stephanie I Abah⁴, Kpokuechukwu C Ogonnadi⁵, Augustus U Ugwu⁶

^{1,2,3,4,5,6}Department of Anatomy, Faculty of Basic Medical Sciences, University of Nigeria, Enugu Campus; E-mail: drchukwudi@gmail.com

Abstracts: The study was aimed at evaluating the effects of an aqueous extract of *Allium sativum* on the biochemical parameters and histo-architecture of lead-induced cerebella damage in male Wistar rats. Sixteen male rats were procured for the study. They were divided into 4 groups, with 4 rats in each group. Group 1 (Control group) received only food and water, those in group 2 were given lead at the dosage of 120 mg/kg body weight. Group 3 received lead at the dosage of 120 mg/kg body weight and the extract at 300 mg/kg body weight while those in group 4 were given lead at the dosage of 120 mg/kg and 500 mg/kg body weight of the extract. The extracts were administered orally for 21 days. Blood samples were collected for biochemical evaluation. The rats were sacrificed, and their cerebella were harvested for histo-morphological studies. The levels of Superoxide dismutase (22.49 ± 1.21) and Malondialdehyde (1.17 ± 0.092) were normal in group 1. There was significant derangement in their levels in group 2, Superoxide dismutase (9.83 ± 0.93) and Malondialdehyde (11.42 ± 1.82). In groups 3 and 4, the levels of Superoxide dismutase increased towards the levels of the control group (12.81 ± 1.13 , 16.06 ± 0.29), while those of Malondialdehyde also decreased towards the levels of the control group (6.49 ± 0.57 , 3.12 ± 0.36). The histo-architecture of the cerebella in group 1, appeared normal, those in group 2 showed traumatic encephalopathy of the granular cell layer. In groups 3 and 4, there was mild tissue traumatic encephalopathy. The extract of *A. sativum* showed a significant protective effect on the biochemical parameters and histo-architecture of lead-induced cerebella damage in adult male Wistar rats.

Keywords: Cerebella Protection, Lead Acetate, Allium Sativum.

1. INTRODUCTION

Lead is a heavy metal and occurs naturally. It is common in the environment, primarily from human activities such as mining, manufacturing, and burning fossil fuels [1]. It has continued to pose health hazards in some States in Nigeria and many other parts of the world. Exposure and intoxication are usually through eating and drinking contaminated food and water and by inhalation. It affects virtually every organ and system in the body; the bones, muscles, livers, kidneys, haematopoietic system, gastrointestinal system, and central nervous system [2,3].

Lead passes through the blood-brain barrier (BBB) rapidly. Its levels in the brain do not decrease as fast as in the blood because it has a relatively slow elimination time in the brain [4]. Once in the brain, lead causes damage to the prefrontal cortex, cerebellum, and hippocampus, through oxidative stress mechanism occurring on two different pathways; via the generation of reactive oxygen species (ROS), such as hydroperoxides (HO), singlet oxygen, and hydrogen peroxide (H₂O₂), and by inactivation of the antioxidant reserves [5,6]

The cerebellum, which is a part of the general brain mass is commonly called the "small brain". It is basically saddled with the responsibility of maintaining equilibrium and control of body movements [2]. In conjunction with other components of the brain, are the major communication network in the human body. Their functions are strongly dependent on the maintenance of its structural integrity and metabolic processes. They are metabolically active even at rest and utilize about 20% of the total oxygen intake by the lungs [3]. This percentage increases substantially when the brain is active. This high utilization of oxygen, however, has some biological consequences [7]. Although oxygen is important for the survival of neurons and glial cells, it also indirectly contributes to their destruction and death overtime [3]. This is because a small percentage of oxygen that enters the cells is metabolized to derivatives that gradually erode and destroy essential molecules [8]. These destructive derivatives of oxygen are free radicals or ROS [9]. When this oxidative stress goes uncontrolled, can cause lipid peroxidation,

which results in oxidative damage to cells, tissues, and organs [10]. One of the end products of lipid peroxidation is malondialdehyde (MDA) [11]. Superoxide dismutase (SOD) and glutathione (GSH) are antioxidants that play a role in supporting cellular function by fighting against ROS; hence, they form the first line of defense [12].

Allium Sativum, popularly known as garlic is a member of the family of Liliaceae and a species of the onion genus, *allium* [1]. Garlic is like an onion made up of bulbs called cloves. It is generally used as a food spice as well as a therapeutic agent in both conventional and present-day medication [13]. It contains sulphur, phosphorus, potassium, and zinc ions, moderate amounts of selenium, vitamin A, vitamin C, and small amounts of calcium, magnesium, sodium, iron, and B complex vitamins and allicin, a compound to trap free radicals [1,13-15]. Traditional medical practitioners have considered garlic as an excellent medicinal plant that has a lot of therapeutic potential. Garlic is used as an anti-hypertension, anti-rheumatic, and stimulant, and in the treatment of various ailments such as asthma, diabetes, cold, paralysis, forgetfulness, tremor, and chronic fever [16]. It has been found that garlic lowers blood cholesterol levels and restores reproductive hormones [17].

This study was aimed at evaluating the effects of an aqueous extract of *Allium sativum* on the histo-morphology and biochemical parameters of lead-induced cerebella injury in male Wistar rats.

2. MATERIALS AND METHOD

2.1. Plant Procurement and Authentication

Fresh *A. Sativum* bulbs were purchased from Ogbete main market in Enugu State and were authenticated at the Plant Sciences and Biotechnology Department at the University of Nigeria, Nsukka, with Voucher number UNH436.

2.2. Extract Preparation

The *A. Sativum* bulbs were separated, peeled, and washed thoroughly with distilled water. After drying in a shed, the clean *A. Sativum* cloves were ground with an electric grinder. The powdered form, weighing 3785.322 grams was poured into an airtight container. Three liters (3L) of distilled water was added and stirred for 2 hours and then allowed to stand for 72 hours. The mixture was sieved with a muslin cloth and further filtered with Whatman's filter paper size No. 1, to obtain a clear filtrate. The filtrate was placed in a hot water bath at the temperature of 80°C to remove the water and get a crude concentrate (Extract). The weight of the extract was 345.76 grams, and the percentage yield was 9.13 grams.

2.3. Procurement of Chemical and Lead Acetate Preparation

Lead acetate was purchased from a reputable pharmacy at Ogbete main market, Enugu State. High dose: 20% (120mg/kg body weight) of the LD50 (600mg/kg body weight) of the lead acetate was dissolved in distilled water for each of the adult Wistar rats according to their average body weight.

2.4. Ethical Approval

This was obtained from the College of Medicine Research Ethics Committee, University of Nigeria, Enugu Campus, with protocol number: 058/7/2022.

2.5. Experimental Animals

Sixteen adult male Wistar rats (weighing 180-200g) were obtained from the animal house of the Department of Pharmacology and Toxicology, University of Nigeria, Nsukka. They were housed in a ventilated cage in the animal house of the Department of Anatomy, University of Nigeria Enugu Campus. The rats were allowed easy access to food (chukun finisher) and water ad libitum. The animals were maintained under 12 hours of light and dark cycles and were allowed to acclimatize for 2 weeks prior to the experiment.

2.6. Stock Solution Preparation and Extract Administration

The stock solution of the extract was prepared with distilled water as the vehicle. The extract was soluble in distilled water upon vigorous shaking. The stock solution was prepared by dissolving 4.4 gram of extract with 80mls of distilled water. The preparation was done every four days and was stored in an airtight bottle, kept in a refrigerator at 4°C after daily use. The appropriate dosage for each group of animals was calculated based on their body weight. The administration was done orally using a cannula (the needle removed) fixed to a 10ml syringe.

2.7. Experimental Design

After acclimatization, the rats were divided into 4 groups of 4 rats each.

Group 1 (normal control) was given distilled water and feed ad libitum.

Group 2 (negative control) was given 120 mg/kg body weight of lead acetate without any extract.

Group 3 (treatment group - low dose) received 300 mg/kg body weight of the aqueous extract from the 1st to 21st day, and 120 mg/kg body weight of lead acetate daily from 15th to 21st day.

Group 4 (treatment group - high dose) received 500 mg/kg body weight of the aqueous extract from the 1st to 21st day, and 120 mg/kg body weight of lead acetate daily from 15th to 21st day.

2.8. Sacrifice of Animals

Twenty-four hours after the last administration of the extracts, blood samples were obtained from the animals through orbital puncture using a capillary tube and emptied into a plane tube for biochemical analysis. Thereafter, the rats were sacrificed using cervical dislocation. A mild incision was made on the head. The cerebellum was dissected out and then fixed in freshly prepared 10% formal saline solution in duly labeled, plastic containers.

2.9. Biochemical Analysis

2.9.1. Determination of SOD

The SOD activity in supernatant was measured by the method described by Arthur and Boyne [18]. The supernatant (500 ul) was added to 0.800 ml of carbonate buffer (100 mM, PH 10.2) and 100 ul of epinephrine (3 Mm). The change in absorbance of each sample was then recorded at 480 nm in a spectrophotometer for 2 min at an interval of 15 seconds. Parallel blank and standard were run for determination of SOD activity. One unit of SOD is the amount of enzyme needed to produce 50% inhibition of epinephrine auto-oxidation.

2.9.2. Determination of MDA

The level of Lipid peroxides was estimated by the Thiobarbituric acid reaction method described by Walin *et al.*, [19]. Sodium dodecyl sulphate (SDS) (8.1%), Acetic acid (20%; PH 3.5), and Thiobarbituric acid (TBA) (0.8%). n-butanol/Pyridine mixture (15:1, v/v) were used as the reagents

To 0.2 ml of the test sample, 0.2 ml of SDS, 1.5 ml of acetic acid, and 1.5 ml of TBA were added. The mixture was completed to 4 ml by adding water to it and then heated in a water bath at 95°C for 60 minutes. After cooling, 1 ml of water and 5 ml of n-butanol/pyridine mixture were added and shaken vigorously. After centrifugation for 10 minutes at 4000 rpm, the organic layer was taken, and its absorbance was read at 532 nm. The MDA was measured as millimoles of MDA per gram of wet tissue.

2.10. Histological Analysis

The fixed tissues were processed for microscopic examination using standard protocol [20]. The fixed cerebella were dehydrated in different grades of alcohol (70–95%). Clearing was done through 2 changes of xylene for 2 hours each, and infiltrating with 2 changes of paraffin wax for 2 hours. The sections were cut at 5 μ m using a rotary microtome. Staining was done with hematoxylin and eosin.

2.11. Statistical Analysis

The data were analyzed using statistical package for social science (SPSS), version 23. The results were shown as mean \pm Standard Deviation. One-way ANOVA was used to compare the results between the various groups and the significant level was set at $p > 0.05$.

3. RESULTS

3.1. Biochemical Result

Table 1: Mean and SD of the antioxidant biomarkers in the various groups


Animal grouping	SOD (μ L) Mean \pm SD	MDA (mg/dL) Mean \pm SD
Group 1 (Normal Control)	22.49 \pm 1.21 ^{bcd}	1.17 \pm 0.09 ^{bc}
Group 2 (Negative Control)	9.83 \pm 0.93 ^{acd}	11.42 \pm 1.82 ^{acd}
Group 3 (Low dose extract + Lead)	12.81 \pm 1.13 ^{abd}	6.49 \pm 0.57 ^{abd}
Group 4 (High dose extract + Lead)	16.06 \pm 1.287 ^{abc}	3.12 \pm 0.36 ^{bc}
P-value	0.00	0.00

Values are Mean \pm SD; ($P < 0.05$) = Statistically significant

a= Significant when compared with the normal control (1), **b=** Significant when compared with the Negative control (2), **c=** Significant when compared with the low dose of extract (3), and **d=** Significant when compared with the high dose of extract (4).

As shown in Table 1, The levels of SOD were normal in group 1 (22.47 \pm 1.21). The value significantly decreased in group 2 (9.83 \pm 0.93). With the extract treatment, the levels of SOD increased, and the increase was more in group 4 (16.06 \pm 1.287). The table also showed that the mean level of the MDA in the normal control group was normal (1.17 \pm 0.09) while that of group 2, significantly increased (11.42 \pm 1.82). With the extract treatment, the derangement was returned to near normal, especially with a high dose (3.12 \pm 0.36).

3.2. Histological Result

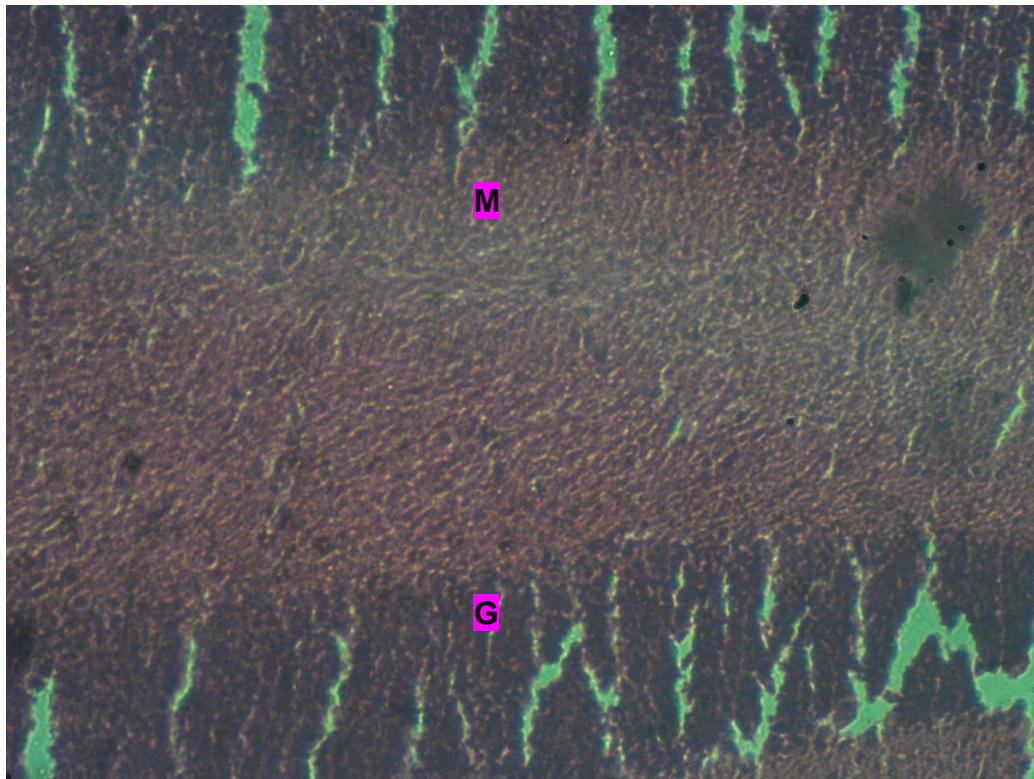


G- Granular layer, M- Medulla, ML- Molecular layer, H & E. X200

M

Plate 1: Photomicrograph of the cerebellum in Group 1 (control).


The photomicrograph of the cerebellum presented in plate 1 shows that the general cyto-architecture appears normal.



G- Granular layer, M- Medulla H & E. X200

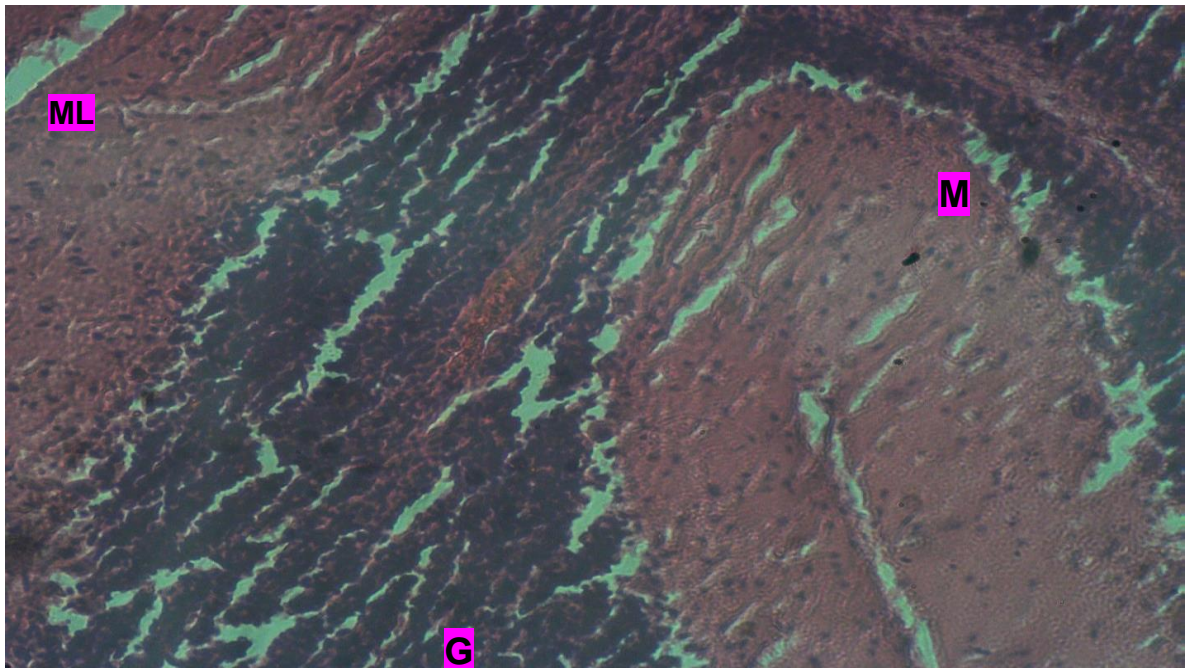
Plate 2: Photomicrograph of the cerebellum in Group 2 (lead only).

The photomicrograph of the cerebellum presented in plate 2 shows the general cyto-architecture with traumatic encephalopathy of the granular cell layer.



G- Granular layer, M- Medulla, ML- Molecular layer. H & E. X200

Plate 3: Photomicrograph of the cerebellum in Group 3 (lead plus low dose of extract). The photomicrograph of the cerebellum presented in plate 3 shows the general cyto-architecture with mild tissue traumatic encephalopathy.



G- Granular layer, M- Medulla, ML- Molecular layer. H & E. X200

Plate 4: Photomicrograph of the cerebellum in Group 4 (lead plus high dose of extract). The photomicrograph shows the general cyto-architecture with mild traumatic encephalopathy.

4. DISCUSSION

This study showed that the SOD activity was significantly decreased in group 2 when compared with that of group 1, the level of MDA also increased significantly in comparison with the level in group 1 (table 1). These implied that there was an induction of oxidative stress by the lead acetate. Our findings are in tandem with the results of Hatice et al., who noted that lead acetate induces neurotoxicity in animal models [21]. There were statistically significant differences between the levels of both SOD and MDA in groups 3 and 4 that received low and high doses of the extracts respectively when compared to those of group 2. This implied that the aqueous garlic extract has a protective effect on lead-induced cerebellar damage. The probable mechanism of action of the extract is its ability to exert its antioxidant action by removing reactive oxygen species, enhancing the cellular antioxidants like reduced SOD of vascular endothelial cells, and enhancement of oxidant enzyme activities and regulation of the Nrf2-ARE pathway [16]. Our findings corroborated with those of Hamza et al., [3] who reported that aqueous garlic extract had a protective effect on lead-induced cerebellar damage.

Our histological results revealed that the cerebellum of the rats in the control group (Group 1), showed normal cytoarchitecture with clearly defined three layers; an outer Molecular layer, an inner Granular layer, and an intermediate Medullar layer as shown in Plate 1. The cerebellum of the rats exposed to Lead acetate (Group 2) showed traumatic encephalopathy of the granular cell layer of the cerebellum. This traumatic granular encephalopathy in the histological photomicrograph is consistent with the previous findings which showed changes in the cerebellum following lead exposure [5]. The cerebellum of the rats exposed to lead acetate and treated with low and high doses of aqueous garlic extract (groups 3 and 4) showed mild tissue encephalopathy of the cerebella layer. This also implied that the aqueous garlic extract has some protective effect on the cerebella damage induced by lead acetate. Our finding is consistent with those of (Saleh et al., [2], Hamza et al.,[3]. We also noted that the effects observed in both the low and high doses of the aqueous garlic extract were very similar, which suggests that the effects were not dose-dependent.

CONCLUSIONS

The aqueous garlic extract showed a protective effect on the lead acetate-induced cerebella damage in male Wistar rats as evidenced by the restoration of the deranged levels of both SOD and MDA.

This was also substantiated by the ability of the aqueous garlic extract to reduce the traumatic encephalopathy to the granular cells of the cerebellum caused by Lead acetate to mild traumatic encephalopathy.

Recommendation

We recommend that further studies should be done on this to identify and isolate the particular phytochemical(s) that are responsible for the protective effect of the aqueous garlic extract on the cerebella damage.

REFERENCES

- [1]. Ajayi GO, Adeniyi TT, Babayemi DO. (2020). Hepatoprotective and some haematological effects of *Allium sativum* and vitamin C in lead-exposed Wistar rats. *Afr J Infect Dis Res.* 2020; 7(3):001-004
- [2]. Saleh HA, Abd El-Aziz GS, Mustafa HN, Saleh AHA, Mal AO, Deifalla AHS, *et al.*, Protective effect of garlic extract against maternal and foetal cerebellar damage induced by lead administration during pregnancy in rats. *Folia Morphol.*2018; 77 (1): 1–15
- [3]. Hamza, G.A, Ibegbu, A.O, Buraimoh, A.A. Evaluation of The Effects of Aqueous Garlic Extract on Lead-Induced Changes on Cerebellum Of Wistar Rats. *Afr. J. Cell. Path.* 2017; 8:9-14.
- [4]. Collins MF, Hrdina PD, Whittle E, Singhal RL. Lead in blood-brain regions of rats chronically exposed to low doses of the metal. *Toxicol. Appl. Pharmacol.*1982; 65:314-332.
- [5]. Pardeep S and Bimla N. Lead intoxication: Histological and Oxidative Damage in Rat Cerebrum and Cerebellum. *J. Trace Elem. Exp. Med.* 2004; 17:45-53.
- [6]. El-Sokkary G.H, Kamel E.S, and Reijer R.J. Prophylactic effects of melatonin in reducing lead-induced neurotoxicity in the rat. *Cell. Mol. Biol. Lett.* 2003; 8:461-470.
- [7]. Shukla V, Mishra SK, Pant HC. Oxidative stress in neurodegeneration. *Adv Pharmacol Sci.* 2011; 572634, 13.

- [8]. Reiter R, Lucien J, Manchester C, Dun X. Neurotoxins: Free radical mechanisms and melatonin protection. *Curr Neuropharmacol.* 2010; 8(3): 194- 210.
- [9]. Volka M, Morris H, Cronim MT. Metals, toxicity, and oxidative stress. *Curr. Med. Chem.*2005. 12(10):1161-208.
- [10]. Ayala A, Muñoz MF, Argüelles S, et al., Lipid peroxidation, metabolism, and signaling mechanisms of malondialdehyde and 4-Hydroxy-2-Nonenal. *Oxid Med Cell Longev.* 2014; (5), 1–31.
- [11]. Agu A, Dike U, Chime S, et al., Protective effect of ethanolic leaf extract of *amaranthus arboreus* on indomethacin-induced gastric ulcer in adult male wister rats. *J. med. pharm. allied sci.*2023; 12(2): 5745–5753.
- [12]. Younus H. Therapeutic potentials of superoxide dismutase. *Int. J. Health Sci.* 2018; 12(3): 88–93.
- [13]. Iram F, Batool S, Shameem S, Aslam I, Batool S, Shaheen M, *et al.*, Effect of aqueous garlic (*Allium sativum*) extract against di-(2-ethylhexyl) phthalate induced reproductive toxicity in male mice. *Andrologia*, 2022; 1-13.
- [14]. Lanzotti V, Scala F, Bonanomi G. (2014). Compounds from allium species with cytotoxic and antimicrobial activity. *Phytochem Rev.* 2014; 13(4): 769–791.
- [15]. El- Demerdash FM, Yousef MI, El-Naga NI. (2005). Biochemical study on onion and garlic in alloxan-induced diabetic rats. *Food Chem. Toxicol.* 2014; 43: 57-63.
- [16]. Shang AO, Shi-Yu C, Xiao-Yu X, Ren-You G, Guo-Yi T, Corke H, *et al.*, Bioactive Compounds and Biological Functions of Garlic (*Allium sativum* L.). *Foods.* 2019; 8: 246
- [17]. Olusanya VO, Rasaanq NO, Ojemekele O. Ameliorative effects of aqueous extracts of ginger and garlic on *Hibiscus sabdariffa*-induced testicular damage in male Wistar rats. *Egypt. Pharm.J.* 2018; 17(1): 21.
- [18]. Arthur JR, Boyne R, 1985. Superoxide dismutase and glutathione peroxidase activities in neutrophils from selenium- and copper-deficient cattle. *Life Sci.* 1985; 36: 1569–1575.
- [19]. Walin B, Rosengren B, Shertzer HG, et al., Lipoprotein oxidation and measurement of thiobarbituric acid-reacting substance formation in a single microliter plate: its use for the evaluation of antioxidants. *Anal. Biochem.*1993; 208(1): 10–15.
- [20]. Obikili EN, Nwosu EO, 2006. *Manual of Practical Histology*, 1st ed., Enugu, Nigeria, University of Nigeria Press. 2006; 1–4.
- [21]. Hatice B, Suna K, Hatice K, Apaydin F G. The Effects on antioxidant enzyme systems in rat brain tissues of lead nitrate and mercury chloride. *Gazi Univ. J. Sci.* 2015; 28(2):169-174.

DOI: <https://doi.org/10.15379/ijmst.v10i2.2851>

This is an open access article licensed under the terms of the Creative Commons Attribution Non-Commercial License (<http://creativecommons.org/licenses/by-nc/3.0/>), which permits unrestricted, non-commercial use, distribution and reproduction in any medium, provided the work is properly cited.