

Morphological State of Intestinal Failure in Experimental Peritonitis and Correction

Adilbekova B. Dilorom^{1*}, Nazarova B. Malokhat², Djumaniyazova M. Gulsara³, Kuranbaeva B. Sevara⁴, Nuruzova A. Zukhra⁵

¹Associate professor, Department of Anatomy and Clinical Anatomy, Tashkent medical academy, Farobiy street-2, Tashkent, Uzbekistan. E-mail: dilorom.adilbekova65@gmail.com, <https://orcid.org/0000-0003-0788-6951>

²PhD, Senior lecturer, Department of Pediatrics and advanced nursing, Urganch branch of Tashkent medical academy, 220100, Al-Xorazmiy st 28. Urgench city, Uzbekistan.

³Assistant, Department of Pediatrics and advanced nursing, Urganch branch of Tashkent medical academy, 220100, Al-Xorazmiy st 28. Urgench city, Uzbekistan.

⁴Assistant, Department of Anatomy, Urganch branch of Tashkent medical academy, 220100, Al-Xorazmiy st 28. Urgench city, Uzbekistan.

⁵Professor, Head of Department of the Microbiology, Virology and Immunology, Tashkent medical academy, Farobiy street-2, Tashkent, Uzbekistan. <https://orcid.org/0000-0002-6188-8723>

Abstracts: Our studies show that pathomorphological changes in the small intestine in acute experimental peritonitis are characterized by dystrophic, inflammatory-destructive and vascular disorders in the vascular tissue structures of the small intestine wall. In the pathogenesis of damage to the small intestine, deep inflammatory and destructive changes in the vessels of the microhemocirculatory bed, which subsequently lead to disruption of cell trophism, tissue hypoxia, damage to cellular elements, disruption of cellular metabolism, deficiency of energy and plastic materials, accumulation of perverted metabolic products in cells and tissues, are of great importance. The use of the "Zerotox" enterosorbent in the treatment complex for the treatment of endogenous intoxication and toxemia had a positive effect on the morphofunctional status of the small intestine, on the clinical course of the disease, on the composition of the intestinal microflora, indicators of local immunological protection, improved clinical and laboratory signs of endogenous intoxication, reduced the recovery period bowel function, reduced the number of postoperative complications.

Keywords: Acute Experimental Peritonitis, Enterosorbent, Small Intestine, Vessels, Tissue Structures.

1. INTRODUCTION

Intestinal insufficiency occupies a leading place among all complications of acute surgical pathologies of the abdominal organs, its mortality is high (from 15% to 40%) and does not tend to decrease [1], [2], [5], [6], [10]. Given the fact that the intestine is the main source of intoxication, intestinal failure syndrome is currently considered as a disease of the entire digestive tract with the occurrence of multiple organ changes [4], [3], [7], [8], [9]. The severity, prevalence, severity of pathomorphological disorders in the vascular tissue structures of the small intestine determine the severity of the intestinal failure syndrome in acute surgical diseases of the abdominal organs. In the literature available to us, we did not find detailed information on the nature and extent of pathomorphological changes in the small intestine in acute surgical diseases of the abdominal organs. In this regard, the study of this issue is an urgent problem for both clinical and fundamental medicine.

2. STUDY PROBLEM AND QUESTIONS

The purpose of the study was to study and evaluate morphological changes in the vascular tissue structures of the small intestine wall in acute experimental peritonitis and in the conditions of their correction.

3. METHOD AND PROCEDURES

The object of the study was the materials of the small intestine of rats seized on days 1, 2, 3 and 4, 5 of the experimental model of peritonitis (experimental group - 50 rats). Peritonitis was induced by introducing into the abdominal cavity a filtered 2% suspension of autocal in the amount of 350 mg/kg, no later than 20 minutes after preparation under ether anesthesia. The control group consisted of 40 rats, they were injected with saline into the abdominal cavity.

To avoid damage to the internal organs during the introduction of fecal suspension into the abdominal cavity, the animals were placed vertically, with the caudal end up. To achieve the goal and the tasks set, general morphological, electron microscopic research methods were used. All studies were conducted in accordance with the International Guidelines for Biomedical Research Involving Animals (1985, 1989). The morphological data obtained during the study were subjected to statistical processing on a Pentium-IV personal computer using the Microsoft Office Excel-2012 software package, including the use of built-in statistical processing functions. Differences satisfying $P \leq 0.05$ were considered significant.

4. STUDY RESULTS AND DISCUSSION

White laboratory rats were used in the experiments. The animals were divided into 2 groups: the control group - animals with experimental peritonitis, which were treated by the traditional method without enterosorbent; 2nd group - animals, in addition to the traditional method of treatment, 3 hours after the simulation of experimental peritonitis, enterosorbent "Zerotox" was intragastrically injected.

In 1-2 hours after the simulation, the first clinical signs of peritonitis were observed in experimental rats without correction of peritonitis: the animals were restless, refused to eat, there was tension in the abdomen. After 6-12 hours, the animals became inactive, lethargic, grouped in the corner of the cage, lethargic, apathetic to food, frequent shallow breathing was noted, the coat became disheveled. A day later, the abdomen was sharply swollen, during laparotomy, an accumulation of 1.5-2 ml of serous-hemorrhagic fluid was determined in all parts of the abdomen. The sheets of the peritoneum and the mesentery of the small intestine were dull, rough, there was vasodilation, punctate hemorrhages and inhibition of intestinal motility.

A morphological study of histological preparations of the small intestine of animals in the control group revealed that the intestinal wall was edematous, loosened, and infiltrated. In the mucous membrane there is swelling, infiltration with mononuclear cells. In the epithelial cells of the mucous membrane, moderately pronounced dystrophic changes were detected. The stroma of villi and crypts is edematous, infiltrated, loosened. In the tops of the villi, desquamation of the epithelial layer is determined, leading to the formation of microerosion. The height of the villi and crypts, the total number of epithelial cells and the number of mitotically dividing cells are reduced compared with the control animals. An increase in the proportion of swollen goblet cells is noted (see Table 1).

Electron microscopically in the cytoplasm of enterocytes, fine-grained granules and transparent vacuoles are detected. Some cells are enlarged in size, are in a state of pronounced cytoplasmic edema with displacement of the nuclei to the apical edge of the cell.

In the submucosal layer, edema, loosening, and infiltration with mononuclear cells are noted. In the muscular membrane there is a pronounced edema, infiltration by mononuclear cells of the connective tissue layers. In the serous membrane of the intestinal wall, subserous edema, swelling, loosening and subtotal desquamation of mesothelial cells are also determined.

Correction of the disease of peritonitis in experimental animals was carried out 3 hours after the moment of peritonitis modeling (daily session of intragastric administration of an enterosorbent solution at the rate of 3.2 mg/100 g of weight). At the opening of the abdominal cavity at the end of day 1, 0.5-1.5 ml of serous-hemorrhagic fluid was found in the abdominal cavity. The sheets of the peritoneum are dull, their stickiness was preserved, the loops of the small intestine were unevenly expanded. The vessels of the mesentery were plethoric. Liquid chyme

and gas bubbles were found in the lumen of the small intestine. Intestinal peristalsis is reduced, but preserved. The animals were decapitated on the 1st, 2nd, 3rd, and 4th days after modeling experimental peritonitis and correction.

Microscopic examination of histopreparations of the small intestine of experimental animals with correction with the enterosorbent "Zerotoks", by the end of 1 day showed that the general plan of the structure of all layers of the small intestine wall was not disturbed. However, there is edema and lympho- and histiocytic infiltration of all layers of the intestinal wall. The morphometric parameters of the villi slightly differed from those of the control group, but in some places they were somewhat deformed in the distal direction of the intestine. The epithelial lining is continuous. Cells are somewhat flattened. Among the epithelial cells, a large number of secreted, swollen goblet cells are revealed. The stroma of the villi is edematous, diffusely infiltrated with mononuclear cells. Vessels of villi and crypts are dilated and full-blooded. In the vessels of the submucosal layer, microextrovasates and plasmorrhagia are detected in places. In the vessels of the venous section, stagnation is observed. In the seromuscular membrane, edema and infiltration with mononuclear cells and focal small hemorrhages in the subserous layers of the intestinal wall are detected. All morphological and morphometric indicators of the vascular tissue structures of the small intestine differed slightly from those of the control group and significantly differed from those of the group of animals that did not receive the Zerotox enterosorbent.

Thus, already by the end of the first day of the experiment in animals receiving enteral detoxification therapy as an enterosorbent "Zerotoks", positive changes were noted in the morphofunctional state of the small intestine.

The study of animals on the 3rd day of the disease showed a gradual resolution of all morphological and morphometric parameters of the wall of the small intestine (table 1). All layers of the intestinal wall are well contoured, histoarchitecture is not disturbed. There was a decrease in the severity of destructive changes in epithelial cells and lamina propria. The number of villi with desquamation of enterocytes decreased. Mucosal villi were moderately deformed, but retained their height. In the lamina propria of the mucosa and submucosa, destructive processes, such as erosion and microextravasates, decreased. Morphometric studies have shown a marked increase in the mitotic activity of cells compared with the indices of animals in the control group. These cells were mixed towards the top of the villi and gradually replaced the desquamated areas of the epithelium. At the same time, interstitial edema persisted in places, inflammatory-dystrophic changes in tissue structures in varying degrees of severity, which indicated the presence of structural damage.

Single microerosive areas are detected in places, but in many areas the epithelial cover of the mucosa is not disturbed. A slight edema of the stroma of the villi persists (Fig. 1.). The number of goblet cells is reduced. compared with animals, without correction with enterosorbent.

Table 1: Morphological parameters of tissue structures of the small intestine wall in experimental peritonitis with enterosorbent correction, M±m

Indicators	control	1 day	2 day	3 day	4 day
Mucosal thickness, µm	620,7±15,6	625,3±19,8	625,0±20,4	645,5±26,9	650,3±29,5**
Villus height, µm	416,4±9,8	400,9±16,9	394,3±13,9*	387,6±10,6	387,5±17,8
Crypt depth, µm	201,0±7,9	190,0±7,1	183,1±6,42,5	182,4±7,2	180,0±6,8*
The number of epithelial cells on one side of the longitudinal section of the villi	89,9±2,5	58,0±1,80***	56,1±2,0***	56,9±1,5***	55,4±2,0***
Number of mitoses (per 1000 cells]	22,1±0,5	20,3±0,7*	19,5±0,7***	17,4±0,8***	16,0±0,6***
Relative number of goblet cells per villus (per 100 cells]	15,5±0,5	20,8±0,6***	24,2±0,8***	25,0±0,8***	27,3±1,3***
Thickness of the serous-muscular membrane, microns	145,0±5,1	150,3±5,2	158,1±6,7	160,3±4,9	163,6±6,2*

Note:- differences relative to control are significant (* - P<0,05, ** - P<0,01, *** - P<0,001)

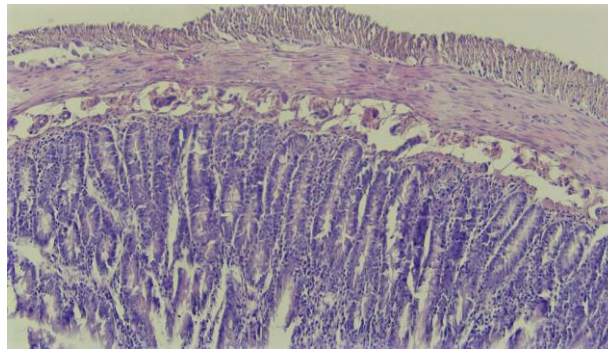


Fig. 1. The general plan of the structure of the wall of the small intestine on the 3rd day of correction. Only single microerosive areas are detected in places (1), often the epithelial cover is not disturbed. Slight edema of the stroma of the villi persists (2). Hematoxylin-eosin staining. 20×10.

There were no visible changes in the muscular layer. In the outer muscular membrane of the intestine, edema and divergence of myocyte bundles decreased. Mesothelial cells of the serous membrane are in the form of flattened cells with a hyperchromic nucleus. Foci of newly formed mesothelial cells appear. Edema of mesotheliocytes and connective tissue structures is noted. The subserous connective tissue is loosened, slightly infiltrated with mononuclear cells, the MCR vessels are without any special changes. The positive effect of detoxification with enterosorbent was also reflected in the morphological state of the microvessels of the small intestine wall. There was a decrease in spasm of arterial vessels, while maintaining a moderate plethora of venous and edema of the vessel walls. As a result, blood flow was restored in most microcirculation vessels. Intraorganic microvessels of the small intestine wall tended to gradual leveling of inflammatory-reactive processes (Fig. 2). Signs of vasculitis were found in some small vessels.

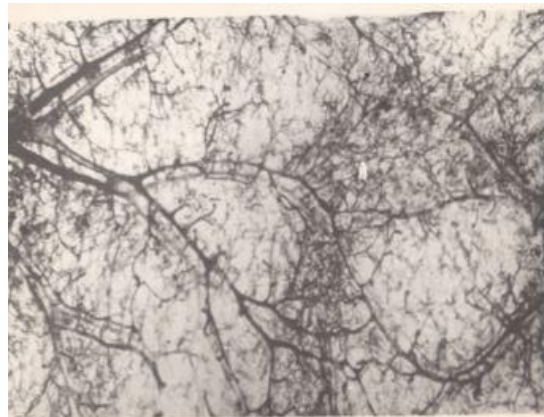

Fig.2. Blood vessels of the submucosa of the small intestine wall on the 4th day of experimental peritonitis correction. 1 - main artery; 2 - main vein; 3 - arteriole; 4 - capillary network. Pouring vessels with the mass of Gerota. 8×7.

On the 5th day of the experiment, when opening the abdominal cavity, there were no fibrinous overlays. Microscopic examination of histopreparations of the small intestine showed that all layers of the intestinal wall are well contoured, the histoarchitecture of tissue structures is not disturbed. In the mucous membrane and in the stroma of the villi, a slight edema and loosening are revealed, in the submucosal layer - an accumulation of fibroblasts, indicating the presence of reparative processes. All morphological and morphometric parameters of MCR microvessels tended to approach those of control animals (Table 2).

There was a resolution of spasm of arterial vessels, only locally in isolated places uneven blood-filled vessels were detected. The stabilization of the permeability of the walls of the vessels was evidenced by a decrease in interstitial edema, exudation phenomena and a decrease in the severity of perivascular cell infiltration.

Table 2: Morphometric parameters of microvessels of the mucous membrane of the small intestine wall in experimental peritonitis with enterosorbent correction, M±m

Indicators	control	1 day	2 day	3 day	4 day
Diameter of the inner lumen of arterioles, microns	26,2±0,31	21,5±1,6**	20,5±1,6***	20,0±1,7***	19,4±2,0***
Capillary lumen diameter, µm	7,2±0,23	5,8±0,4**	5,7±0,4***	5,6±0,5***	5,7±0,6***
Postcapillary lumen diameter, µm	13,1±0,20	17,3±1,3*	18,4±1,5**	19,0±1,5***	19,7±2,1***
Venule lumen diameter, µm	25,0±0,15	27,5±0,9**	28,4±0,3***	28,8±0,3***	30,2±0,6***
Density of distribution of mucosal vessels in. units	395,5±5,8	374,4±17,4*	354,6±18,3*	334,4±17,3**	285,6±19,2**

Note: - differences relative to control are significant (* - $P<0,05$, ** - $P<0,01$, *** - $P<0,001$)

Thus, enterosorbent detoxification in the treatment of intestinal failure syndrome provided positive dynamics of the morphofunctional status of the vascular tissue structures of the small intestine. Correction of progressive endogenous intoxication and toxemia with the Zerotox enterosorbent after 3 hours of experimental modeling of acute diffuse peritonitis led to positive changes by the end of 1 day of the experiment, which were still not observed in animals with peritonitis without correction. The gradual restoration of the morphological state of the vascular tissue structures of the small intestine provided adequate metabolism at the cellular level and a relatively rapid restoration of all disturbed processes by the end of the 5th day of the experiment. Thus, by the end of the 5th day of the experiment, all morphometric parameters and the qualitative state of the intestinal wall indicated a gradual return to normal.

CONCLUSION

1. Intestinal insufficiency in experimental peritonitis is characterized by vascular, inflammatory, destructive and degenerative disorders in the vascular tissue structures of the small intestine.

2. At the heart of pathomorphological disorders in peritonitis are deep vascular disorders, as evidenced by edema and swelling and high variability of the walls, expansion, plethora of venous vessels, microthrombosis, impaired permeability of vessel walls, multiple extravasations, a decrease in the distribution density of vessels in the microhemocirculatory bed.

3. All these processes were accompanied by a violation of trophism in the intestinal wall, tissue hypoxia, damage to cellular elements, a violation of cellular metabolism, a deficiency in energy and plastic materials, and the accumulation of perverted metabolic products in cells and tissues.

4. Enterosorbent "Zerotoks", in the complex therapy of patients with severe SCI, is a powerful tool for the treatment of endogenous intoxication and toxemia, has a positive effect on the morphofunctional status of the small intestine and on the clinical course of the postoperative period, on the composition of the intestinal microflora and indicators of local immunological protection, improved clinical and laboratory signs of endogenous intoxication, reduced the period of recovery of bowel function by 2.1 days, reduced the number of postoperative complications by 20.2% and mortality of patients by 6.3%

5. A deep understanding of the pathogenesis of morphological disorders of this condition determines in the future the conduct of targeted, evidence-based, highly effective complex therapy.

REFERENCES

- [1] Abdurazzakhov Kh. S., Adilbekova D. B. Pathomorphology of the small intestine in experimental peritonitis // Materials of the international scientific and practical conference - Samarkand, 2021. -pp.8.
- [2] Dibirov, M.D. Dependence of stress-damages of the mucous membranes of the upper gastrointestinal tract in peritonitis and pancreatitis on microcirculatory disorders // Infections in Surgery. - 2017. - No. 2. - pp.31-33.
- [3] Takha Khamza Dib, Allniazi Alaa Eddin, Amakhanov Albert Kokhremanovich, Inyutin Alexander Sergeevich Features of the course of enteral insufficiency syndrome in patients with generalized peritonitis // Kazan Med. magazine. -2015. No. 4. –pp.489-493
- [4] Ilchenko F. N., Bagirov N. V., Buglak N. P. Evaluation of the severity of enteral insufficiency syndrome and its correction using enteral therapy in patients with generalized peritonitis // Med. vestn. south of Russia. - 2017. - No. 2. - pp. 45-46.
- [5] Mironov A. V. Intestinal insufficiency syndrome with widespread peritonitis: diagnosis and methods of enteral correction: Abstract of the thesis. dis. ... cand. honey. Sciences. - M., 2011. - 23.
- [6] Stepanyan A. T., Uryadov S. E. et al. Perioperative correction of intestinal insufficiency syndrome in the prevention of postoperative peritonitis // Sovrem. problems of science and education. - 2017. - No. 4. - pp. 14-22.
- [7] Uryadov S. E., Stepanyan A. T., Stekolnikov N. Yu. Comparative pathogenetic aspects of the development of intestinal failure syndrome in acute intestinal obstruction and peritonitis in the experiment // Fundament. research. - 2014. - No. 10. - pp. 185-188.
- [8] D.B. Adilbekova ,S.R. Baymakov, Kh.S. Abdurazzakov. Morphological aspects intestinal Insufficiency in experimental peritonitis //American journal of Medicine and Medical Sciences 2021, 11(9):658-661/ DOI: 10.5923ajmms 20211109.11
- [9] Schulz K. Cytokine and radical inhibition in septic intestinal barrier failure // J. Surg. Res. – 2015. – Vol. 193. – pp. 831-840.
- [10] Shan C.X. Influence of laparoscopy vs. laparotomy on bacterial translocation and systemic inflammatory responses in a porcine model with peritonitis // J. Invest. Surg. – 2014. – Vol. 27.– pp. 73-80.

DOI: <https://doi.org/10.15379/ijmst.v10i2.2835>

This is an open access article licensed under the terms of the Creative Commons Attribution Non-Commercial License (<http://creativecommons.org/licenses/by-nc/3.0/>), which permits unrestricted, non-commercial use, distribution and reproduction in any medium, provided the work is properly cited.