

Hesperetin Alleviate Renal Ischemia-Reperfusion Injury in Male Mice Model by Suppressing Inflammation & Oxidative Stress Pathway

Widad Abd AL-Jabbar^{1*}, Shereen M. Mekkey², Ameer S Sahib³, Ghadah Ali Al-Oudah⁴

^{1,2,3,4}Al-Mustaqbal University College, Babylon, Hilla, Iraq Widad Abd AL-Jabbar / Pharmacology and therapeutics, Dept. of Pharmacy, Al-Mustaqbal University College, Babylon, Hilla, Iraq; E-mail: wedadalzameli@gmail.com

Abstracts: Reports indicate that renal injury or damage results in high mortality. *Aim:* To evaluate the beneficial aspects of hesperetin in treating kidney injury in male mice caused by ischemia-reperfusion (IR). *Materials and Method:* Twenty-eight male Swiss Albino mice with weight range of 35–38 g at 12–16 weeks old were gathered into 4 groups; each group had seven mice, as follows: group I (sham group) undergone all research surgical techniques, with the exception of the use of vascular clamps for occlusion and reperfusion on the pedicles. group II (IR group) was subjected to reperfusion and ischemia. group III (DMSO group), Hesperetin's solvent is (DMSO)dimethyl sulfoxide was subjected to intraperitoneal injection of 1.5 mg/kg of DMSO 30 min prior to the exposure to renal IR processes under anesthesia. group IV (hesperetin treated group) was subjected to intraperitoneal injection of 50 mg/kg of hesperetin 30 min before being subjected to IR procedures while sedated. Mice underwent euthanization, and then a blood sample from the heart was taken to measure the levels of urea, creatinine, MDA, and glutathione peroxidase (GPx) in the serum. Bilateral nephrectomy was performed and the kidney sample underwent homogenization so that the tissue markers can be measured (IL1 and IL6). A part of the kidney sample was placed in paraffin blocks with a 10% formalin solution, and prepared for histological examination. *Results:* The results demonstrated that the average (mean) tissue levels of (IL1, IL6, and MDA), also the mean serum concentration of (urea and creatinine) and the histopathological changes scores compared to the sham group, increased significantly ($P < 0.05$) in the IR group, while the activity of glutathione peroxidase ($P < 0.05$) was reduced compared with other groups. In the hesperetin treated group, the mean levels of IL1, IL6, and MDA as well as the mean urea and creatinine levels in the blood underwent significant ($P < 0.05$) reduction. Similarly, the histopathological changes scores were decreased, while the glutathione peroxidase ($P < 0.05$) activity was higher compare with other groups Hesperetin reduces kidney injury caused by ischemia and reperfusion through their pleiotropic effects by modulating the inflammation pathway and oxidative activity.

Keywords: Renal Ischemia / Reperfusion Injury / Hesperetin / Glutathione peroxidase (GPx).

1. INTRODUCTION

The primary factor that contributes to acute damage or injury to the kidney is the ischemia reperfusion injury (IRI). If it is not treated, it leads to high morbidity as well as high mortality [1]. Ischemia-reperfusion injury (IRI) results from a sudden short-term stoppage of blood flow to a specific organ. Ischemia-induced hypoxia causes tissue damage, reactive oxygen species (ROS), necrosis of the tubular epithelium, and inflammatory reactions. [2]. Despite the fact that the pathophysiology of IRI remains unclear, some vital processes that result in kidney failure are reported [3]. In kidney that has undergone ischemia and reoxygenation, Acute kidney failure, inflammation, and cell death are all caused by detrimental cellular responses that are sparked by the production of ROS during the reperfusion phase. [4]. Ischemia yields mediators, such as cytokines that promote inflammation. Interleukin-1 (IL-1) plays a major part in numerous acute inflammation processes. By using anti-inflammatory agent, the attenuation of ischemic reperfusion injury is achieved [5]. Interleukin-6 (IL-6) causes a more serious immune and inflammation response, in addition to having a number of vital physiological roles. It has been shown that dysregulated IL-6 is associated with some inflammation and autoimmune diseases in addition to metabolic abnormalities [6]. Excess free radicals attack healthy cells by damaging their membranes [7]. If malondialdehyde (MDA) level is high, it means that the oxidative stress level is dangerous. MDA test is used to regularly monitor the free radical activity in the body [8]. Glutathione (GSH) refers to an endogenous antioxidant that is present in fungi, animals and plants. It offers protection to cells through the neutralization of hydrogen peroxide. IR damage or injury is worse than that caused by only ischemia. This is because of the rapid increase in ROS, which results in endothelial and organ dysfunction in several clinical conditions [9]. Hesperetin belongs to a group of compounds called bioflavonoids.

They are a kind of plant pigment that is usually present in citrus fruits. Hesperetin is present in tangerines, oranges, lemons and grapefruits; in addition, it is obtainable in the form of supplement. Hesperetin has antioxidant and anti-inflammatory effects [10]. It is a popular flavanone glycoside that has exhibited significant antiviral, analgesic, anti-inflammatory, anticancer, antioxidant, and antifungal behavior. After a kidney transplant, ischemia-reperfusion (IR) injury is a severe issue. Moreover, inflammatory responses to IR worsen the kidney injury that has resulted [11].

2. MATERIEL AND METHODS

2.1. Preparation of Hesperetin

Hesperetin (Sigma-Aldrich, USA) was prepared for intraperitoneal injection, the drug powder was dissolved in DMSO (Sigma-Aldrich). USA).

2.2. Experimental Classes

Twenty-eight male Swiss Albino mice weighting 35–38 grams at 12–16 weeks were included in this study. The mice were subjected to a 12-hour cycle of light and darkness. at room temperature ($22 \pm 2^\circ\text{C}$). After 2 weeks of adaptation, they were grouped into 4 groups on a random basis; each group contained 7 mice. All of the study's surgical procedures were performed on group I (the sham group), with the exception of vascular occlusion and reperfusion. group III (DMSO group) was subjected to intraperitoneal injection of 1.5 mg/kg of DMSO 30 min prior to the exposure to IR processes under anesthesia [12]. Group IV (hesperetin treated group) was subjected to intraperitoneal injection of 50 mg/kg of hesperetin 30 min prior to exposure to IR processes under anesthesia [12].

2.3. Anesthesia

2% xylazine hydrochloride (10 mg/kg) was administrated intraperitoneally with 50 mg/kg ketamine hydrochloride (10%) [13].

2.4. EXPERIMENTAL PROTOCOL

All mice were laid on their backs, and their limbs and tails were positioned in a way that ensures appropriate breathing. They were covered with sterile gauze. A clipper was used to remove the hairs of the mice. Using a 70% alcohol swab, the surgical area was cleaned, and along the abdomen, a 1-1.5 cm midline incision was created. The renal pedicle was then exposed by pushing the kidneys from the wound using sterile cotton swabs. After 30 minutes, the kidneys were released from the clamps and placed back inside the abdominal cavity. which was closed in two layers to start reperfusion. After two hours, the animals were euthanized. Blood was aspirated for analysis, and renal tissue was collected for tissue measurement and histological analysis [14].

2.5. Blood sampling

In a plane tube, the blood was put, and it was left to clot at 37 OC. Subsequently, a 15-minute, 3000 rpm centrifugation process was performed for determination of blood urea, serum creatinine, MDA and glutathione peroxidase.

2.6. Tissue Sampling For Elisa

Protease inhibitor cocktail using a high intensity liquid processor with 1:10 (w/v) phosphate buffered saline was used for homogenization of kidney tissue [15]. Centrifugation was done on the homogenized product for 20 minutes at 3000 rpm [14]. Supernatant was separated for measuring the IL1 and IL6 levels by ELISA using an ELISA kit according to manufactures techniques.

2.7. Histopathological Analysis

The paraffin blocks containing 10% formalin were filled with the kidney sample. Hematoxylin and Eosin (H&E) is used to stain the samples after that, all this was done as per the standard protocol. Thereafter, the degree of tissue

damage was assessed by a pathologist, who was blind to the processes of the experiment. The score (0) represents normal, score (1) represents <25% of the damage of the tubules, score (2) represents 25%–50% of damage of the tubules, and score (3) represents >51% of damage of the tubules [16].

3. Statistical analysis

The data was analyzed by using version 24 of SPSS software, A tukey post hoc test and one way analysis of variance (ANOVA) were used to compare the normal distribution with the quantitative variables. The research results presented as mean ± standard deviation, and a *P* value of <0.05 was considered significant.

4. RESULTS

4.1. Effect of Renal IR on renal function test (urea and creatinine)

The mean serum levels of urea and creatinine in IR group's The IR group's, were significantly higher than those of the control group (*p* < 0.05). The mean serum levels of urea and creatinine did not significantly differ between the DMSO and IR groups. When compared to the DMSO group, hesperetin group had significantly decreased serum amounts of urea and creatinine (*p* < 0.05). Figure 1 & 2.

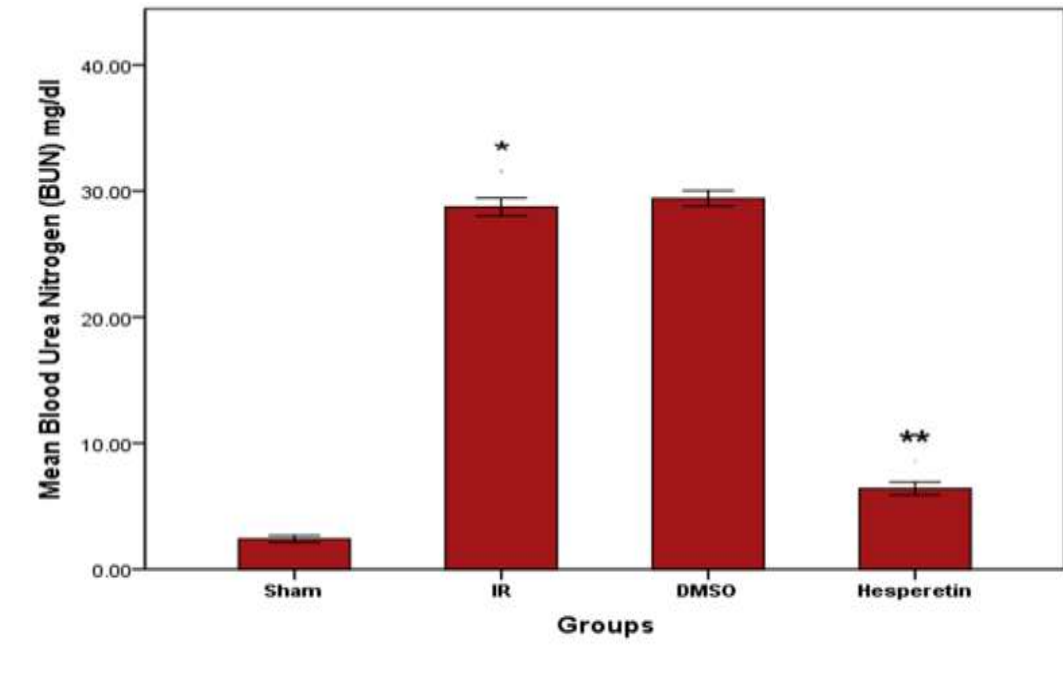


Figure 1: Blood urea nitrogen expressed as a mean ± standard deviation in all research groups (* significant versus sham; **significant versus DMSO; *p*<0.05.)

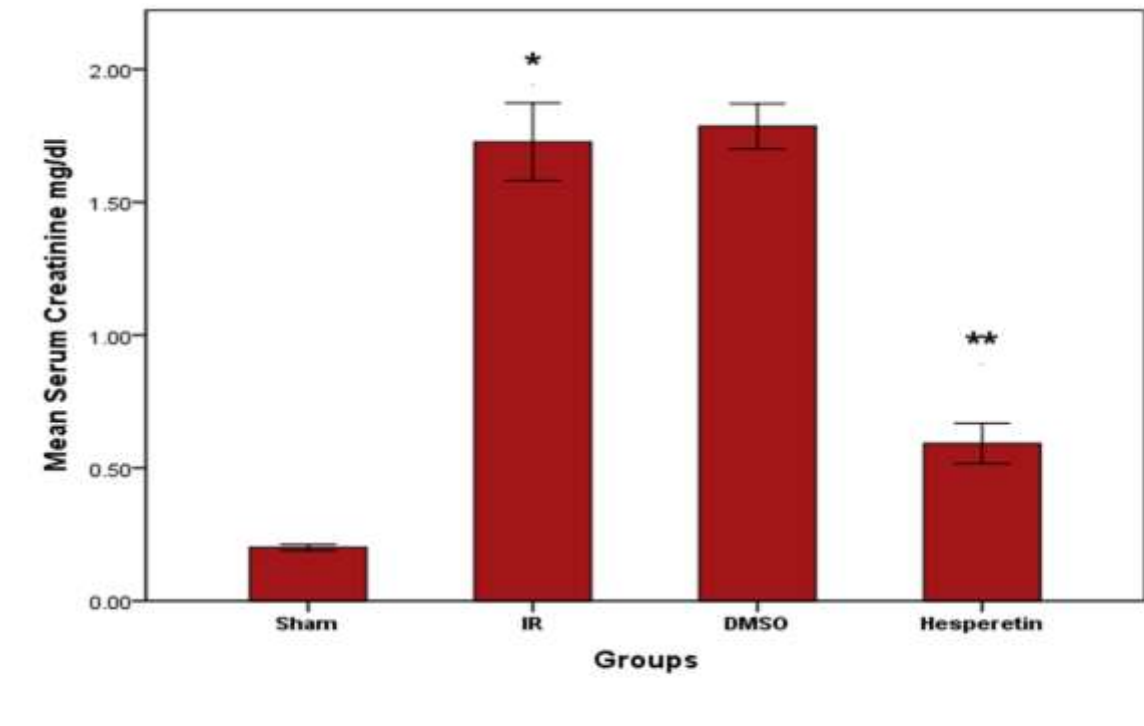


Figure 2: Serum creatinine levels expressed as mean \pm standard deviation in all research groups (* significant versus sham; **significant versus DMSO; $p < 0.05$.)

4.2. Effect of Renal IR on inflammatory markers (IL-1 and IL-6)

The mean tissue levels of IL-1 and IL-6 in the IR groups were significantly higher ($p < 0.05$) than that of sham group. No significant difference between DMSO and IR groups for IL-1 and IL6 levels. In comparison to the DMSO group, the group that received hesperetin had significantly reduced tissue IL-1 and IL-6 concentrations. ($p < 0.05$). Figure 3&4.

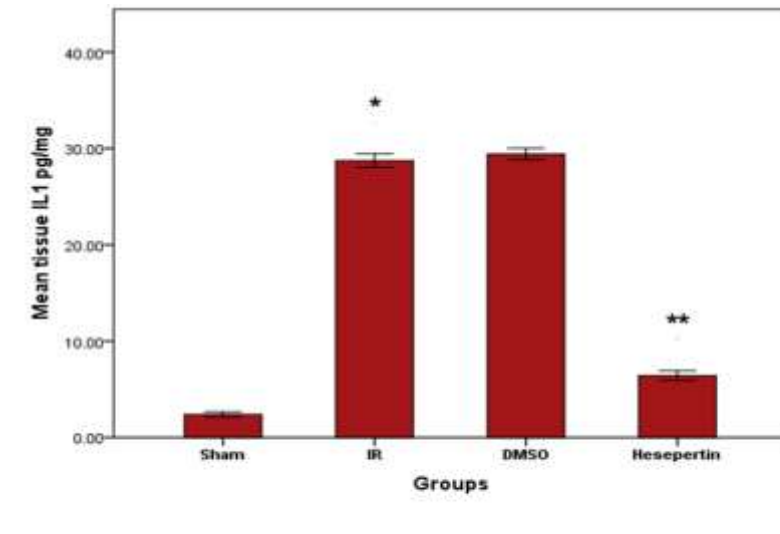


Figure 3: IL-1 tissue levels in all research groups expressed as mean± standard deviation (* significant versus sham; **significant versus DMSO; $p < 0.05$).

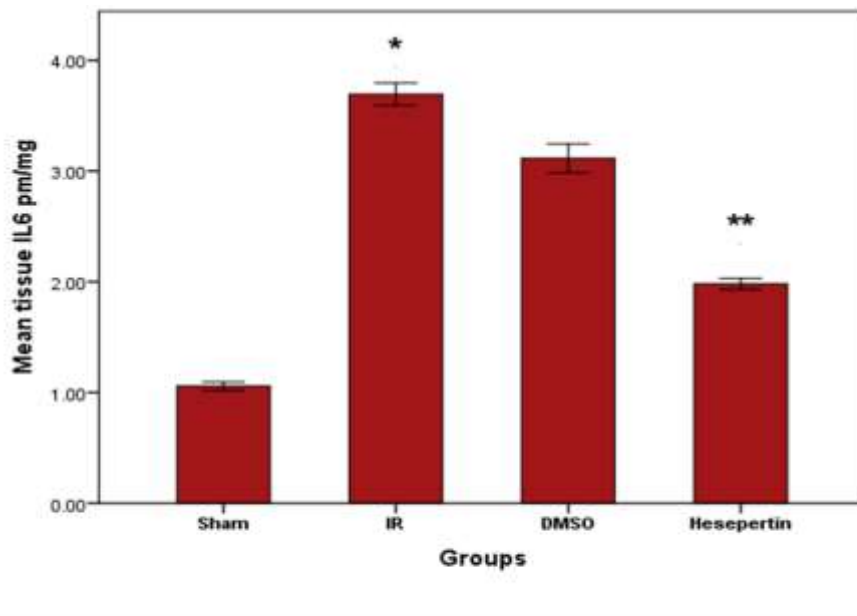


Figure 4: Mean tissue levels of IL-6 in the four experimental groups (* significant versus sham; **significant versus DMSO; $p < 0.05$).

4.3. Effect of Renal IR on MDA

A significant difference ($p < 0.05$) in MDA level between IR and sham groups, there was insignificant difference between the DMSO and the IR group for the level of MDA. The hespertin treated group showed a significantly lower serum MDA level than that of the DMSO group ($p < 0.05$). Figures 5.

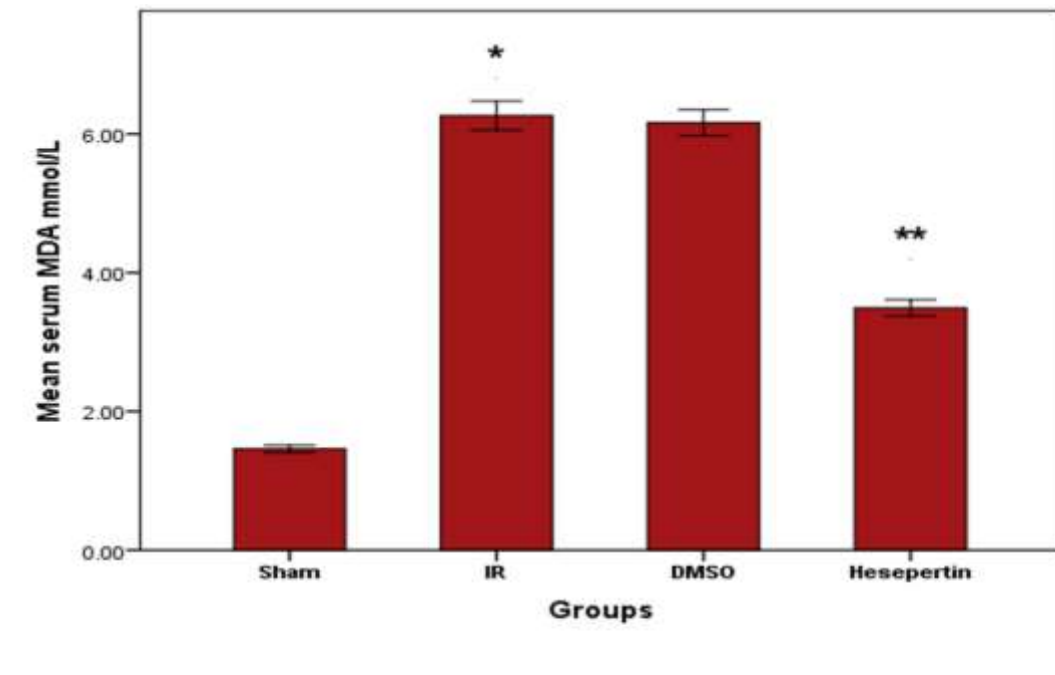


Figure 5: MDA serum level in all experimental groups expressed as mean \pm standard deviation (* significant versus sham; **significant versus DMSO; $p < 0.05$).

4.4. Effect of Renal IR on GPx

Mean blood level of GPx in the IR group was significantly lower ($p < 0.05$) than that of sham group. Regarding the mean serum level of GPx, an insignificant difference exists between the DMSO and the IR group. The hespertin treated group showed a significantly higher serum GPx concentration than that of the DMSO group ($p < 0.05$). Figures 6.

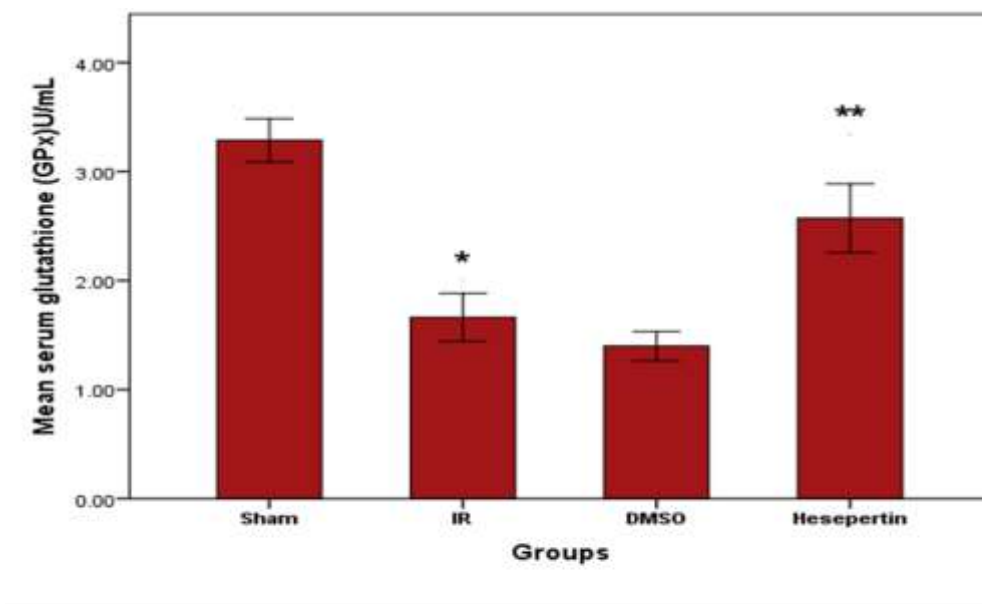


Figure 6: Mean serum level of GPx in the four experimental groups (* significant versus sham; **significant versus DMSO; $p < 0.05$).

4.5. Effects of Hesperetin treatment on Renal Histology after IRI in mouse kidney

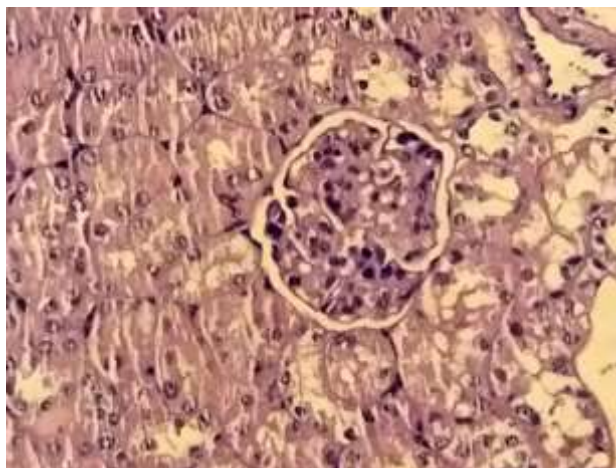


Figure 7: Histological analysis of the sham group failed to show any renal morphological changes; mouse kidney stained with H&E

Note: H&E means hematoxylin and eosin

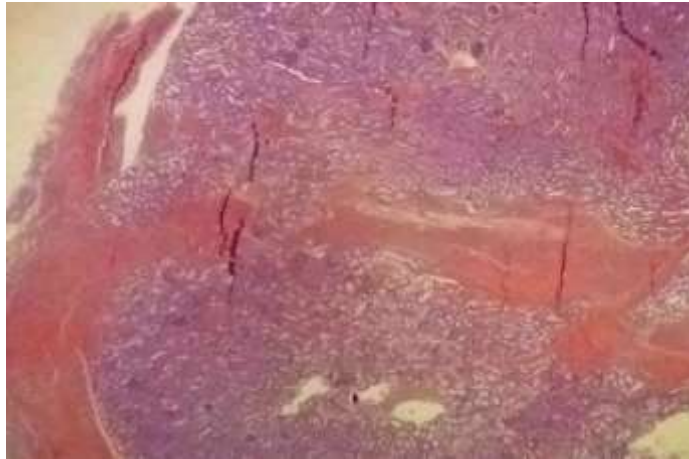


Figure 8: Histological examination of the IR group revealed tubular epithelium necrosis, degeneration, and glomerular fibrosis; mouse kidney stained with H&E.

H&E = hematoxylin and eosin.

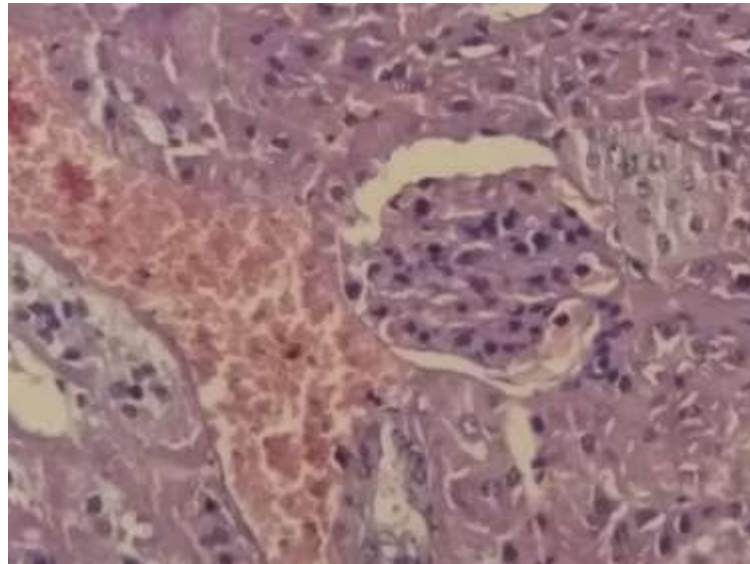


Figure 9: Histological examination of the DMSO group demonstrated proximal convoluted tubules with feathery degeneration and areas of interstitial hemorrhage; mouse kidney stained with H&E

H&E =hematoxylin and eosin.

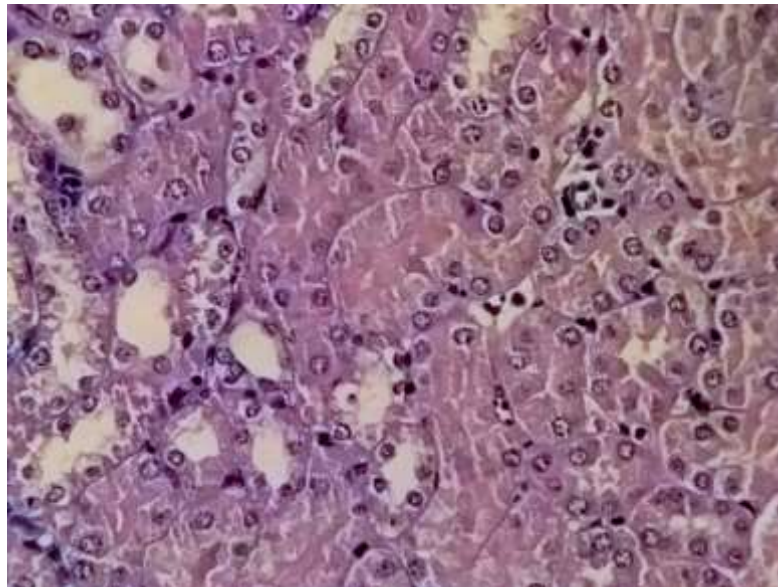


Figure 10: Histological examination of the hesperetin Histological treated group demonstrated normal proximal convoluted tubules with moderate congestion of glomerular capillary blood vessels; mouse kidney stained with H&E

H&E = hematoxylin and eosin.

5. Discussion

5.1. Effect of renal ischemia-reperfusion on renal function test; blood urea nitrogen (BUN) and serum creatinine

Due to kidney ischemia and reperfusion injury, renal function tests (BUN and serum creatinine) in the IR group significantly increased ($p < 0.05$) when compared to sham group. Liang et al. [17] showed that the increasing serum urea and creatinine levels after reperfusion injury is attributed to the damage of the glomerular filtration membrane.

5.2. Effect Of Renal Ischemia-Reperfusion On Inflammatory Cytokines (IL-1 And IL-6)

In the IR group, the tissue levels of IL-1 and IL-6 were significantly higher than that of sham group as a result of kidney ischemia and reperfusion injury ($p < 0.05$). In a mouse model of kidney IRI, Hu et al. [18] showed that the expression level of IL-1 was considerably higher in the IR group than in the sham group. According to Kreiner et al. [19], rats with diabetes, chronic renal illness, and cardiovascular disease had IR injury that activated IL-6 signaling.

5.3. Effect of renal ischemia-reperfusion on MDA and GPx

Based on this study's findings, kidney ischemia-reperfusion significantly reduced glutathione GPx and raised MDA in contrast to the sham-control groups ($P < 0.05$). According to Yousefi et al. [20], the products of lipid peroxidation and protein oxidation exhibited a clear increase, while the levels of GSH showed a marked decrease.

5.4. Effect of Renal IR On Kidney Parenchyma

According to histological analysis of the kidney sections for ischemia-reperfusion group, there were a lot of apoptotic positive cells and damage with significant nuclear pyknosis, cellular cytoplasmic vacuolation, and vascular congestion. According to past studies, isolated pancreas tissue from rats with ischemia showed a considerable rise in tissue damage score, necrosis, apoptosis, MDA, and catalase enzyme activity, which is consistent with our findings. Deterioration of islets functions was caused by bilateral kidney ischemia for 45 min. This may be due to

limited antioxidant activity and lipid peroxidation induction in pancreatic tissues [21]. There was a statistically significant difference between the IR group and the control group ($P < 0.05$).

5.5. Effect of Hesperitin on Renal Function Test (Urea & Creatinine)

The outcome revealed that hesperitin (50 mg/kg) 30 minute before the induction of ischemia caused significantly lower serum level of urea and creatinine in comparison to those in the IR group. According to Chen et al. [22] hesperitin can cause significant alleviation of cisplatin-related nephrotoxicity, BUN and serum creatinine. The above results affirm that hesperetin could be a protective agent against nephrotoxicity induced by cisplatin. Also, according to the study, serum creatinine & In comparison to the hesperitin group, in cisplatin group, the blood urea level was significantly higher ($p < 0.05$).

5.6. Effect of Hesperitin on Inflammatory Cytokines (IL-1 & IL-6)

The results show that using hesperitin (50 mg/kg) 30 minutes before inducing ischemia resulted in significant reduction in tissue levels of IL-1 and IL-6 compared with those in the IR group. The study by Fu et al. [23] observed that hesperidin inhibited IL-1 and IL-6 stimulated inflammation in human osteoarthritis chondrocytes. Hesperidin also caused the inhibition of inflammation responses in IL-1 β -stimulated human chondrocytes, probably by preventing Nuclear Factor kappa-B (NF-Kb) signaling pathway activation [24].

5.7. Effect of Hesperitin on MDA and GPx

Based on few studies, hesperitin inhibits free radical formation and pathways of inflammation by triggering the nuclear factor erythroid 2-related factor/protein kinase B signaling pathway. [25]. depend on our findings, kidney ischemia-reperfusion caused a significant reduction in GPx and increment in MDA related to the sham group ($P < 0.05$). Salimnejad et al. [26] showed that the products of lipid peroxidation and protein oxidation showed clear increase, while the levels of GSH exhibited significant reduction.

5.8. Effect of Hesperetin on Renal Parenchyma

Histopathological evaluation indicated that hesperitin alleviated IR-induced kidney injury in mice. Treatment of mice with hesperetin significantly reduced renal injury ($P < 0.05$) in comparison to the IR group [27]. Histopathological examination of the mouse kidney tissue showed swelling and cystic renal tubule; dilatation with interstitial inflammation were apparent when contrast with the sham group. The improvement in renal histology in the hesperetin treated group is related to antioxidant and anti-inflammatory effects.

CONCLUSIONS

Hesperetin treatment of mice with kidney damage caused by ischemia and reperfusion alleviated systemic and kidney-specific inflammatory and oxidative stress responses, It suggests that hesperetin could be improved to be as a novel medication in acute renal ischemia-reperfusion treatment.

REFERENCES

- [1] Ding, M., Tolbert, E., Birkenbach, M., Gohh, R., Akhlaghi, F. and Ghonem, N.S., 2021. Treprostinil reduces mitochondrial injury during rat renal ischemia-reperfusion injury. *Biomedicine & Pharmacotherapy*, 141, p.111912.
- [2] Hasanein, P., Rahdar, A., Barani, M., Bains, F. and Yari, S., 2021. Oil-in-water microemulsion encapsulation of antagonist drugs prevents renal ischemia-reperfusion injury in rats. *Applied Sciences*, 11(3), p.1264.
- [3] Godarzi, S.M., Gorji, A.V., Gholizadeh, B., Mard, S.A. and Mansouri, E., 2020. Antioxidant effect of p-coumaric acid on interleukin 1- β and tumor necrosis factor- α in rats with renal ischemic reperfusion. *Nefrologia*, 40(3), pp.311-319.
- [4] Malek, M. and Nematbakhsh, M., 2015. Renal ischemia/reperfusion injury; from pathophysiology to treatment. *Journal of renal injury prevention*, 4(2), p.20.
- [5] M. Tavafi, H.R. Sameni, A. Tamjidipour, A. Hasanvand, H. Ashoory (2016) Antioxidant effect of rosmarinic acid against renal ischemia reperfusion injury in rat; a histopathological study *Ann Res Antioxid*, 1, p. e24
- [6] Su, H., Lei, C.T. and Zhang, C., 2017. Interleukin-6 signaling pathway and its role in kidney disease: an update. *Frontiers in immunology*, 8, 419

p.405.

- [7] Matejovic, M.; Ince, C.; Chawla, L.S.; Blantz, R.; Molitoris, B.A.; Rosner, M.H.; Okusa, M.D.; Kellum, J.A.; Ronco, C. Renal Hemodynamics in AKI: In Search of New Treatment Targets. *J. Am. Soc. Nephrol.* 2016, 27, 49–58.
- [8] Cherian, D.A., Peter, T., Narayanan, A., Madhavan, S.S., Achammada, S. and Vynat, G.P., 2019. Malondialdehyde as a marker of oxidative stress in periodontitis patients. *Journal of pharmacy & bioallied sciences*, 11(Suppl 2), p.S297.
- [9] Park, E.J., Dusabimana, T., Je, J., Jeong, K., Yun, S.P., Kim, H.J., Kim, H. and Park, S.W., 2020. Honokiol protects the kidney from renal ischemia and reperfusion injury by upregulating the glutathione biosynthetic enzymes. *Biomedicines*, 8(9), p.352.
- [10] Meng, X., Wei, M., Wang, D., Qu, X., Zhang, K., Zhang, N. and Li, X., 2020. The protective effect of hesperidin against renal ischemia-reperfusion injury involves the TLR-4/NF- κ B/iNOS pathway in rats. *Physiology International*, 107(1), pp.82-91.
- [11] Park, W.S., Park, M.S., Kang, S.W., Jin, S.A., Jeon, Y., Hwang, J. and Kim, S.K., 2019, October. Hesperidin shows protective effects on renal function in ischemia-induced acute kidney injury (Sprague-Dawley rats). In *Transplantation Proceedings* (Vol. 51, No. 8, pp. 2838-2841). Elsevier.
- [12] Takhtfooladi HA, Mortazavi P, Asghari A, Moayer F, 2022. Effects of Hesperetin on the Serum Superoxide Dismutase, Glutathione Peroxidase, and Malondialdehyde Levels and Renal-Histopathological Alterations Following Skeletal Muscle Ischemia Reperfusion in Male Rats. *Crescent Journal of Medical and Biological Sciences*.;9(1).
- [13] Abd-Jabbar W, Hadi NR, Ameer Ghafil FA, Abdulkadhim H, Mahbuba W, Abdul Khaleq MA, Fatima G. 2019 NEPHROPROTECTIVE EFFECTS OF QUERCETIN IN RENAL ISCHEMIA REPERFUSION INJURY IN MICE. *Systematic Reviews in Pharmacy*. Jan 1;10(1).
- [14] ABD AL-JABBAR WI, ABDULKADHIM H, MAHBOBA W, FATIMA G. Potential Activity of Naringenin against Renal Ischemia Reperfusion Injury in Male mice. *International Journal of Pharmaceutical Research*. 2019 Oct;11(4).
- [15] Basile, D. P., Donohoe, D., Roethe, K., & Osborn, J. L. (2018). Renal ischemic injury results in permanent damage to peritubular capillaries and influences long-term function. *American Journal of Physiology-Renal Physiology*.
- [16] -Xu, F., Wu, M., Lu, X., Zhang, H., Shi, L., Xi, Y., Zhou, H., Wang, J., Miao, L., Gong, D.W. and Cui, W., 2022. Effect of Fc-Elabela-21 on renal ischemia/reperfusion injury in mice: Mediation of anti-apoptotic effect via Akt phosphorylation. *Peptides*, 147, p.170682.
- [17] Liang, C., Zhu, J., Miao, C., Wang, S., Zhang, L., Li, P., et al (2017). Protective effects of the segmental renal artery clamping technique on ischemia-reperfusion injury in db/db diabetic mice. *BioMed research international*, 2017.
- [18] Hu, X., Xu, Y., Zhang, Z., Tang, Z., Zhang, J., Luo, Y., Deng, W., Dong, Z., Zhao, Y. and Na, N., 2021. TSC1 Affects the Process of Renal Ischemia-Reperfusion Injury by Controlling Macrophage Polarization. *Frontiers in immunology*, 12, p.637335.
- [19] Kreiner, F.F., Kraaijenhof, J.M., von Herrath, M., Hovingh, G.K.K. and von Scholten, B.J., 2022. Interleukin 6 in diabetes, chronic kidney disease, and cardiovascular disease: mechanisms and therapeutic perspectives. *Expert Review of Clinical Immunology*, 18(4), pp.377-389.
- [20] Yousefi, H., Ahmadiasl, N., Salimnejad, R., Bagheri, E., Roshangar, L. and Alihemmati, A., 2019. Effects of renal ischemia-reperfusion on biochemical factors and histopathological alterations in the liver of male rats. *Physiology and Pharmacology*, 23(1), pp.44-50.
- [21] Hussein A, Abd-Elkhabir A, Abozahra A, Baiomy A, Ashamallah SA, Sheashaa HA, et al. 2014 Pancreatic injury secondary to renal ischemia/reperfusion (i/r) injury: possible role of oxidative stress. *Physiological Research*;
- [22] Chen, X., Wei, W., Li, Y., Huang, J. and Ci, X., 2019. Hesperetin relieves cisplatin-induced acute kidney injury by mitigating oxidative stress, inflammation and apoptosis. *Chemico-biological interactions*, 308, pp.269-278.
- [23] Fu, Z., Chen, Z., Xie, Q., Lei, H. and Xiang, S., 2018. Hesperidin protects against IL-1 β -induced inflammation in human osteoarthritis chondrocytes. *Experimental and Therapeutic Medicine*, 16(4), pp.3721-3727.
- [24] Dai T, Shi K, Chen G, Shen Y and Pan T: Malvidin attenuates pain and inflammation in rats with osteoarthritis by suppressing NF- κ B signaling pathway. *Inflamm Res*. 66:1075–1084. 2017.
- [25] Poetini MR, Araujo SM, Trindade de Paula M, Bortolotto VC, Meichtry LB, Polet de Almeida F, Jesse CR, Kunz SN and Prigol M: Hesperidin attenuates iron-induced oxidative damage and dopamine depletion in *Drosophila melanogaster* model of Parkinson's disease. *Chem Biol Interact*. 279:177–186. 2018
- [26] Salimnejad R, Soleimani Rad J, Mohammad Nejad D, Roshangar L. 2018 Effect of ghrelin on total antioxidant capacity, lipid peroxidation, sperm parameters and fertility in mice against oxidative damage caused by cyclophosphamide. *Andrologia*; 50: e12883.
- [27] Mohamadian, M., Parsamanesh, N., Chiti, H., Sathyapalan, T. and Sahebkar, A., 2022. Protective effects of curcumin on ischemia/reperfusion injury. *Phytotherapy Research*.

DOI: <https://doi.org/10.15379/ijmst.v10i3.1549>

This is an open access article licensed under the terms of the Creative Commons Attribution Non-Commercial License (<http://creativecommons.org/licenses/by-nc/3.0/>), which permits unrestricted, non-commercial use, distribution and reproduction in any medium, provided the work is properly cited.