

Diagnostic Value of US and CT in an Unusual Case of Asymptomatic Intrauterine Gossypiboma

George Hadjidekov^{1,*}, Dayana Yankova¹, Maria Yankova² and Dorina Asenova²

¹Department of Radiology, University Hospital "Lozenets, Sofia 1407, Bulgaria

²Department of Obstetrics and Gynaecology, University Hospital "Lozenets, Sofia 1407, Bulgaria

Abstract: Foreign-body material such as surgical sponge, accidentally retained in the human body, is termed gossypiboma or textiloma. This may result in foreign-body reaction with severe surgical complications if left unknown. Computed tomography (CT) and ultrasound (US) are preferred methods for detection of gossypibomas. The radiologic features on CT are characteristic whatever in any location – spongiform mass with gas bubbles, low-density mass with a thin enhancing capsule and calcified depositions along the network architecture of a surgical sponge. US also provides a typical appearance of hypoechoic or anechoic mass with distal loss of signal. Surgical removal is mandatory considering the amount of possible complications. We present a case of rare localization of asymptomatic intrauterine gossypiboma and discuss the common US and CT features of this infrequent entity.

Keywords: Retained foreign body (RFB), Cesarean procedure, Surgical sponge, Gossypiboma, Uterus, Computed Tomography, Ultrasound.

INTRODUCTION

A "gossypiboma", also called "textiloma" or "cottonoid", refers to a foreign object, mainly mass of cotton matrix or a sponge, that is left behind in a body cavity during an operation. It is not an uncommon entity or surgical complication. The etymology of the word "gossypiboma" is derived from Latin "gossypium", which means cotton, and the Swahili word "boma", meaning place of concealment, referring to a retained sponge in the surgical bed or cavity [1]. The resulting foreign-body occurs mainly following emergency operations, prolonged surgeries, abundant hemorrhage, change of personnel during the course of the operation or inexperienced staff [2, 10]. US and CT are preferred methods for detection of lost/left foreign materials.

CASE PRESENTATION

A 27 -year-old woman with first, full term pregnancy was admitted in obstetrics department with active labor contractions. Due to complications during second stage of labor, emergency Cesarean section was executed. The BMI of the patient was normal to upper – limit – 30. During surgery, there was an unexpected bleeding and an extra sets of sponges were used. After the urgency was over a missing cotton matrix was suspected,

followed by revision of the abdominal cavity and intraoperative X-Ray examination. There were suspicious but unclear signs from X-Ray for a material in pelvic area, but it was not found during the revision of the abdominal and pelvic cavities. On postoperative ultrasound examination a wavy, hyper-echoic structure with pronounced posterior acoustic shadowing was in favor of retained sponge within the uterine cavity (Figure 1). CT scan confirmed the diagnosis (figure 2). Trans-cervical hysteroscopy and removal of the retained foreign body - a missed sponge, had been performed. Post-procedural course was uneventful. Postoperative period was uncomplicated without any pelvic discomfort. Vital signs were normal and routine lab data was normal. The patient was discharged without complications.

IMAGING FEATURES

Gossypibomas can present various imaging characteristics.

Ultrasound Examination

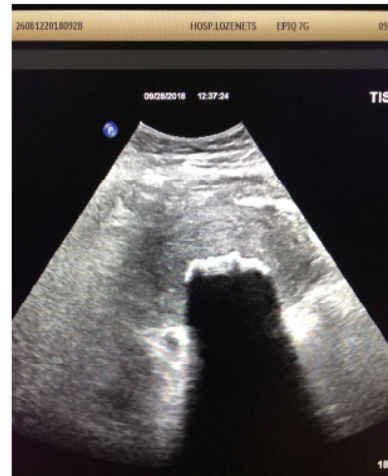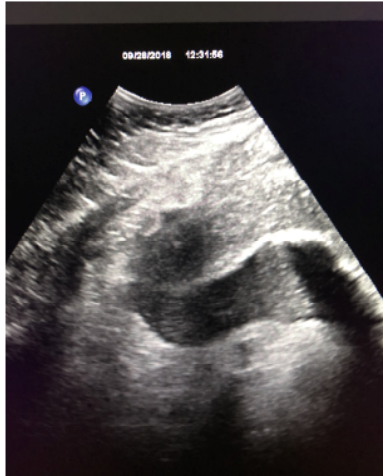
The typical appearance is well-defined mass with hyper-reflective echo, hypo-echoic rim and massive posterior acoustic shadowing. Sonographic characteristics of retained foreign bodies (RFB) can be either cystic or solid type. The cystic lesion may present a wavy echogenic structure within and the solid one is mainly a complex hetero-echoic mass, both with acoustic shadowing due to calcified areas or air pockets [10].

*Address correspondence to this author at the Department of Radiology, University Hospital "Lozenetz" 1,Koziak str. Sofia 1407, Bulgaria;
Tel: +359 898 797612;
E-mail: jordiman76@yahoo.com

CT Examination

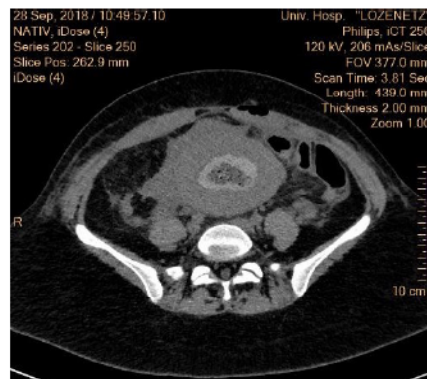
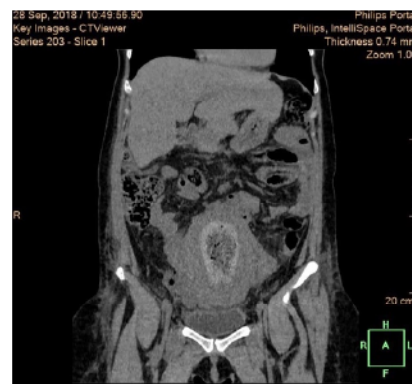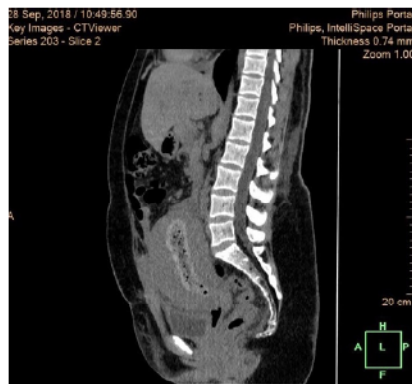The pathognomonic key features on CT scan are mottled, bubbly gas shadows of a heterogeneous, low density mass with a thick peripheral rim. The most

characteristic CT appearance of textiloma is the spongiform pattern with gas bubbles [5]. Specific features could be helpful to precise the type of the retained material and are mentioned in the discussion below.



US Examination

Figure 1: Sonography reveals a wavy, hyperechoic structure within the uterus from the fundus protruding to the uterine neck. A marked dense posterior acoustic shadowing is present.



CT Examination

Figure 2: Non-contrast CT scan shows well circumscribed pelvic low density lesion about 9 x 7 x 8 cm in maximum dimensions. It shows heterogeneous gas-containing non-specific appearance with multiple air bubbles (spongiform appearance), without any hyperdense markers. It is positioned entirely intrauterine localized adherent to the uterine fundus.

DISCUSSION

Gossypibomas are frequently diagnosed in the intraabdominal cavity. Moreover, they can also be encountered in the thorax [3, 4], extremities [5], central nervous system [6] and breast. Clinical onset and presentation may vary from immediate postoperative period to several decades after surgery [7]. Gossypibomas can cause two types of responses in the body: exudative and aseptic fibrous reactions. Aseptic gossypibomas can form adhesions, encapsulation and eventually granuloma formation. Exudative gossypibomas, however, usually occur early in the postoperative period and may involve secondary bacterial contamination, which can result in various fistulas. The main differential diagnosis and major mimicker is a tumor, that could lead to unwarranted invasive diagnostic procedures or extensive extirpative surgery, resulting in further complications [8, 9].

CT is the method of choice for assessing of the presence of foreign tissue and the extent of the associated inflammatory reaction. According to our experience CT is a valuable technique in cases of gossypiboma. The method has advantages in cases of more complex, US "hidden" regions, due to the better anatomical visualization and to the better spatial resolution. Although identification of the type of retained material could be challenging, there are some features suggesting concrete objects. Linear densities with a peculiar infolding or whorled configuration suggest a towel [4, 10]. Sponges and gel foam tablets resembles low-attenuation masses with multiple gas bubbles [5, 10]. Wall calcifications are easily distinguished on CT as a dense peripheral ring.

Depending on the type of the pathological response gossypibomas may lead to various complications from encapsulation and localization in fibrous reaction to extrusion of the foreign material in case of exudative reaction [10]. The latter could migrate into cavities or into the vagina, rectum or intestinal lumen [11], causing obstruction [12], malabsorption or intestinal hemorrhage [11], even expulsion by defecation [10].

To our knowledge, no other cases of asymptomatic intrauterine gossypibomas following recent Cesarean section are reported in academic researches. One report presents a gossypiboma following Cesarean section which led to abscess and uterine wound dehiscence in a female who underwent an emergency Cesarean section four months earlier [13].

Prevention of gossypiboma is better than treatment [14]. Surgical sponges could have radiopaque markers or not. In our case the radiogram there is no radiopaque marker, which doesn't exclude foreign body material. The current use of textile surgical materials soaked with radiopaque markers that are easily detectable by the intra-operative radiological shifting when an incorrect count is suspected is a good method of prevention [15]. In conditions of emergency it is possible to have a wrong or extra count sponges as it was in our case [16]. Other conditions such as number of surgeons and change of surgical team during the operation, massive hemorrhage represents additional risk for this complication. A patient-related risk factor is the obesity. Obese patients have a huge intraperitoneal space where sponges may be lost and this may increase the technical obstacles of the operation [17]. The BMI of our patient was upper-limit.

Finally, the gossypiboma in its entity is an iatrogenic injury, if remain unknown and thus can have some aspects related to medical ethics in patient care.

CONCLUSION

Gossypiboma is not an uncommon entity and the radiologist should be familiar with the common and unusual imaging appearances in order to make a correct diagnosis in the appropriate clinical setting. In cases of suspicion of loose or leftover foreign body materials and unclear radiological findings one should be aware to perform further imaging examinations even in asymptomatic patients. CT scanning is the diagnostic modality of first choice to prove or to rule out the presence of retained foreign body. Moreover, this situation could lead to iatrogenic injury and could have possible impact to medical ethics in patient care. In order to avoid that, all the Radiology methods should be undertaken during the surgery and immediately after the intervention if needed, as in our particular case.

REFERENCES

- [1] Sun HS, Chen SL, Kuo CC, *et al.* Gossypiboma-retained surgical sponge. *J Chin Med Assoc* 2007; 70(11): 511-3. [https://doi.org/10.1016/S1726-4901\(08\)70051-0](https://doi.org/10.1016/S1726-4901(08)70051-0)
- [2] Özsoy Z, Okan I, Daldal E, *et al.* Laparoscopic removal of gossypiboma. *Case Rep Surg* 2015; 2015: 317240. <https://doi.org/10.1155/2015/317240>
- [3] Yilmaz Durmaz D, Yilmaz BK, Yıldız O, Bas Y. A rare cause of chronic cough: Intrathoracic gossypiboma. *Iran J Radiol* 2014; 11(2): e13933. <https://doi.org/10.5812/iranradiol.13933>
- [4] Parienty RA, Pradle J, Lepreux JH. Computed tomography of sponges retained after laparotomy. *J Comput Assist Tomogr* 1981; 5: 187-89. <https://doi.org/10.1097/00004728-198104000-00008>

- [5] Rabie ME, Hosni MH, Al Safty A, *et al.* Gossypiboma revisited: A never ending issue. *Int J Surg Case Rep.* 2016; 19: 87-91.
<https://doi.org/10.1016/j.ijscr.2015.12.032>
- [6] Ebner F, Tolly E, Tritthart H. Uncommon intraspinal space occupying lesion (foreign-body granuloma) in the lumbosacral region. *Neuroradiology* 1985; 27: 354-56.
<https://doi.org/10.1007/BF00339572>
- [7] Ribalta T, McCutcheon IE, Neto AG, *et al.* Textiloma (gossypiboma) mimicking recurrent intracranial tumor. *Arch Pathol Lab Med* 2004; 128: 749-58.
- [8] Lee DH. Inflammatory gossypiboma in young female athlete. *J Exerc Rehabil* 2015; 11(4): 236-38.
<https://doi.org/10.12965/jer.150227>
- [9] Eken H, Soy Turk M, Balci G. Gossypiboma mimicking a mesenchymal tumor: A report of a rare case. *Am J Case Rep* 2016; 17: 27-30.
<https://doi.org/10.12659/AJCR.896717>
- [10] Gayatri P and Bright T. A pictorial review of the many faces of gossypiboma – observation in 6 cases. *Pol J Radio.* 2017; 82: 418-21.
<https://doi.org/10.12659/PJR.900745>
- [11] Lata I, Kapoor D, Sahu S. Gossypiboma, a rare cause of acute abdomen: A case report and review of literature. *Int J Crit Illn Inj Sci* 2011; 1(2): 157-60.
<https://doi.org/10.4103/2229-5151.84805>
- [12] Kataria S, Garg M, Marwah S, Sethi D. Postoperative adhesive intestinal obstruction from gossypiboma. *Ann Med Health Sci Res* 2012; 2(2): 206-8.
<https://doi.org/10.4103/2141-9248.105677>
- [13] Usta TA, Yildirim D, Ozyurek SE, Gundogdu EC. Conservative treatment of a gossypiboma causing uterine wound dehiscence. *Case Rep Obstet Gynecol* 2013; 2013: 578027.
<https://doi.org/10.1155/2013/578027>
- [14] Dane C, Yayla M, Dane Banu. A foreign body (gossypiboma) in pregnancy: first report of a case. *Gynecological Surgery* 2006; 3(2): 130-31.
<https://doi.org/10.1007/s10397-006-0181-5>
- [15] Rajagopal A, Martin J. Gossypiboma -"a surgeon's legacy": report of a case and review of the literature. *Dis Colon Rectum* 2002; 45: 119-20.
<https://doi.org/10.1007/s10350-004-6124-1>
- [16] Gawande AA, Studdert DM, Orav EJ, Brennan TA, Zinner MJ. Risk factors for retained instruments and sponges after surgery. *N Engl J Med* 2003; 348(3): 229-35
<https://doi.org/10.1056/NEJMsa021721>
- [17] Ulucay T, Dizdar MG, SunayYavuz M, Asirdizer M. The importance of medico-legal evaluation in a case with intraabdominal gossypiboma. *Forensic Sci Int* 2010; 198(1-3): e15-8. doi:10.1016/j.forsciint.2010.01.013. Epub 2010 Feb 16.

Received on 20-11-2018

Accepted on 07-12-2018

Published on 13-12-2018

<http://dx.doi.org/10.15379/2408-9761.2018.05.03.01>© 2018 Hadjidekov *et al.*; Licensee Cosmos Scholars Publishing House.

This is an open access article licensed under the terms of the Creative Commons Attribution Non-Commercial License

(http://creativecommons.org/licenses/by-nc/3.0/), which permits unrestricted, non-commercial use, distribution and reproduction in any medium, provided the work is properly cited.