

Concepts and Thoughts about Modern Uterine Intramural and Subserosal Myomectomy

Andrea Tinelli^{1,2,*}

¹Department of Gynecology and Obstetrics, Division of Experimental Endoscopic Surgery, Imaging, Minimally Invasive Therapy and Technology, Vito Fazzi Hospital, Lecce, Italy

²International Translational Medicine and Biomodelling Research Group, Department of Applied Mathematics, Moscow Institute of Physics and Technology (MIPT), State University, Moscow, Russia

Abstract: Myomectomy is the main conservative uterine operation of modern gynecology, as the percentage of patient with myomas is ever increasing. In the last century, this operation was performed by “open” technique, then, with the advent of minimally invasive technologies, it is passed to the endoscopic method. Thus, hysteroscopy and laparoscopy, until the modern robotically assisted surgery were introduced or the removal of uterine myomas. Many of the concepts of traditional surgery, in light of modern scientific evidences, were revisited, since the myomectomy have been evaluated from the morphological-functional side. Therefore, with the forthcoming endocrinal biological discoveries, myomectomy has slowly changed the technical and surgical planning. Many limits have been widely surpassed, up to the possibility of applying this method even in older women, over 45 in which is critical of the uterus preservation for assisted procreation. In the last century, considering to perform a myomectomy in a 45-47 year old woman with myomas was an unlikely thought; nowadays, with the methods of assisted reproductive technique, many reproductive limits have been largely overcome, until the menopausal pregnancy. This clinical opinion is based on biologic anatomical morphological evidences, which allowed knowing better the consequences of uterine myomectomy within the capabilities of the uterus after myomectomy.

Keywords: Myoma, Fibroid, Myomectomy, Laparoscopy, Robotic, Myoma pseudocapsule, Neurovascular bundle, Cesarean myomectomy, Pregnancy, Complication, Uterine rupture.

INTRODUCTION

Uterine myomectomy is a surgical technique that has evolved over the years, with the improvement of technology and surgical methods. Much progress has been made in the field of minimally invasive surgery, but still many steps will have to improve patients' surgical outcome after myomectomy. Myoma is the most common gynecological disease, compromising the uterine reproductive function and causing many troublesome symptoms. The uterus, for its uniqueness, must be always spared, especially in case of intramural and subserosal myomas, to avoid the definitive loss of reproductive chances. Moreover, the increasing age of first pregnancy, presupposes to face with myomas in pregnancy with greater frequency, as well as the ability to perform myomectomy also over 40-45 years, in order to preserve the organ for an assisted reproductive technique (ART). If in the past, patients with fibroids over forty-five years' had few chances to become pregnant, now many women remain pregnant after ART, even in menopause, over fifty. This socio-demographic changes led the ethical and deontological

problem of conservative surgery over forty-five years. Fibromatous uterus removal at 45 years', nowadays, could create a subsequent medical legal litigation, since the ART gives good chances of pregnancy (Figure 1), even after 50' years.

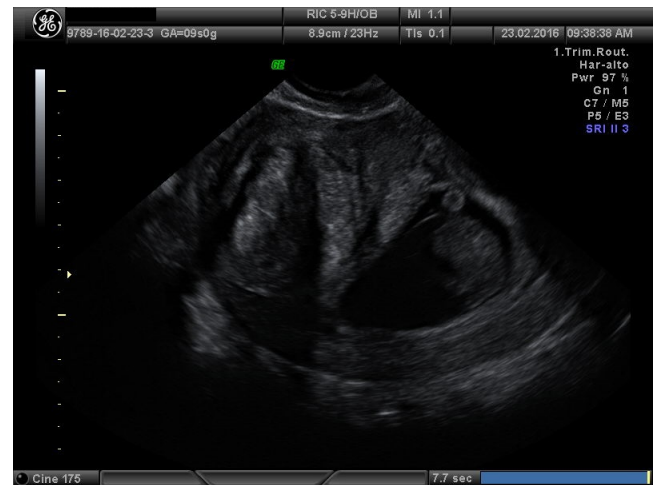

Figure 1: An ultrasonographic scan of a pregnant of 43 years' old at 9 weeks with a 5 cm myoma.

ANATOMIC FINDINGS: BASIC CONCEPTS

Myoma or fibroid may be either solitary or multiple, demonstrates three distinctive growth patterns, according to their anatomical localization. They may be

*Address correspondence to this author at the Department of Gynecology and Obstetrics, Division of Experimental Endoscopic Surgery, Imaging, Minimally Invasive Therapy and Technology, Vito Fazzi Hospital, Lecce, Italy; Tel: +393392074078; Fax: +390832661500; E-mail: andreatinelli@gmail.com

intramural (localized within the myometrium), subserous (externally positioned, extending to the serosa), submucous (protruding into uterine cavity) and pedunculated, extending through cervical canal or into abdominal cavity. Intramural fibroids are the most common myoma type, followed by subserous fibroids. Submucosal fibroids occur least frequently, although they often cause symptoms at a very early stage. Subserous and submucosal fibroids can also be pedunculated [1].

The myometrium is predominantly made of smooth muscle cells surrounded by a rich network of blood and lymphatic vessels and fibroid are benign neoplasms that arise into myometrium. They are composed of disordered fascicles of smooth muscle cells with variable amount of fibrous tissue. During its growth, myoma compresses the surrounding tissue, causing formation of a pseudocapsule, encapsulating the myoma (Figure 2) [2].

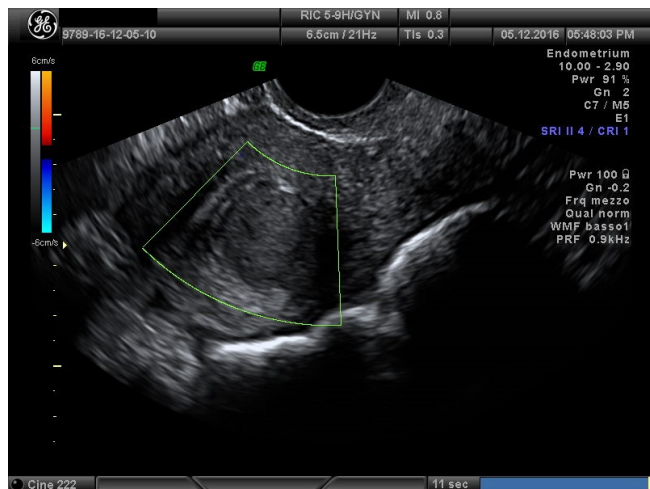


Figure 2: An ultrasonographic scan of intramural myoma in trapezoidal area, surrounded by a white ring, the pseudocapsule.

The mechanical properties of myomas are a key factor that can contribute to their growth. While myomas are more rigid, pseudocapsule is more elastic, due to lower content of extracellular matrix, which allows uterine adaptation to the myoma growth. Hence, myoma induces displacement on the peripheral myometrium by its growth, without destructive action, since the integrity and contractility of uterine structure is maintained [3].

Biological genesis of the pseudocapsule is not well known yet, although literature data have documented that the pseudocapsule originates from myometrium surrounding myoma [2]. So far, it appears to be a

myometrium protective structure possibly enhancing regenerative mechanisms [4].

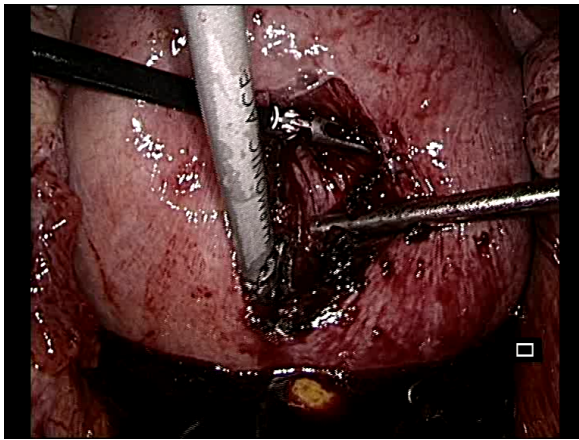
Fox *et al.* [4], investigated myoma specimens by means of ultrastructural microscopy. Those researches found an anatomical structure distinct from normal myometrium, asserting that myomas have a clear outline and forming a pseudocapsule made of compressed muscle fibers, which surrounds myomas. Malvasi *et al.* [5] investigated the ultrastructural features of subserous and intramural myomas using visualization by transmission electron microscopy. The authors described the fine ultrastructural details of the pseudocapsule cells, which showed the features of smooth muscle cells similar to the myometrium. This confirmed the concept that the pseudocapsule is part of the myometrium compressed by the myoma [2].

Ito *et al.* [6] performed a histopathology evaluation of the myoma and its pseudocapsule. By microstructural studies of the architecture of the myometrium and the extra-cellular matrix in the presence of myomas. Authors found that the myoma is anchored to the pseudocapsule by connective bridges, but lacks its own true vascular pedicle. This is one of the main mistakes made by surgeons when they seek the vascular pedicle. Not only the vascular pedicle does not exist, but also it is useless to try to find it in the myometrium as obviously wrong surgical technique. When myomectomy started, it must hit its target to achieve the cleavage plane between myoma and myometrium, to preserve either tissue surrounding fibroid or scar formation, with positive impact on reproductive outcome [7].

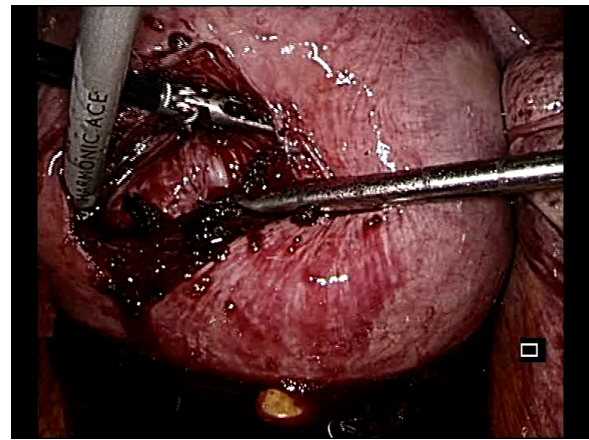
This clinical opinion focuses on intramural and subserosal myomas, where is necessary to operate directly on the uterus, incising the serosa and myometrium.

Step 1: Hysterotomy and Myoma Enucleation

The first step of myomectomy is the visceral peritoneum incision, followed by hysterotomy to arrive to myoma, highlighting the cleavage plane between myoma and myometrium, the pseudocapsule (Figures 3 A and B). This passage is the most delicate of the operation and it should be done quickly, with appropriateness and safety. Myomectomy should be by intracapsular method, using the physio pathological concepts and solutions in cleavage plane interception, to avoid bleeding (Figures 4 A-C).

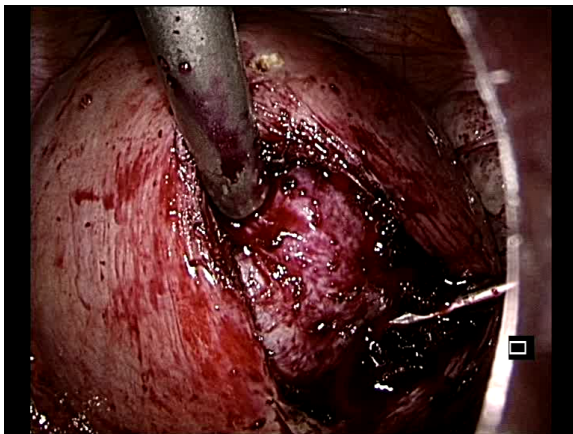


(A)

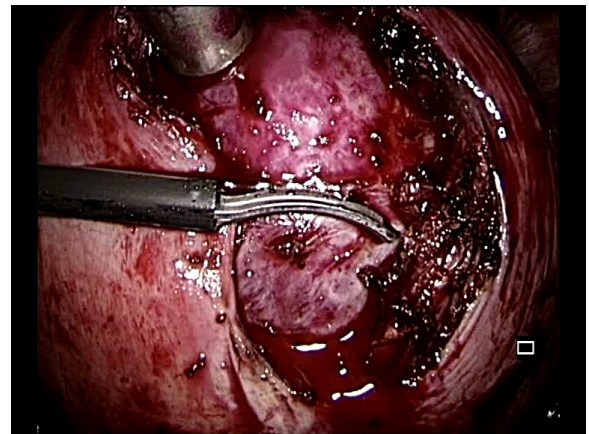


(B)

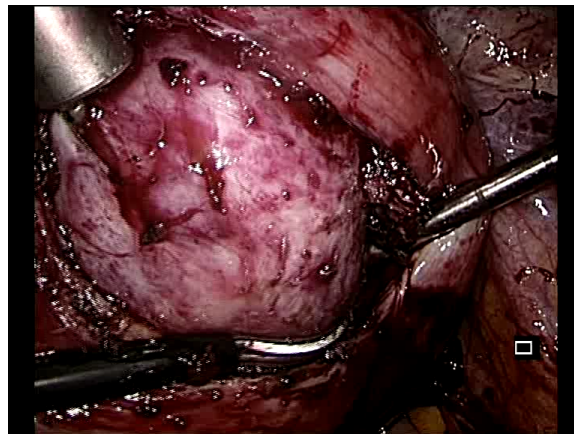
Figures 3 A and B: Laparoscopic myomectomy. The first step of intramural / subserosal myomectomy is the visceral peritoneum incision, followed by hysterotomy to arrive to myoma (A), highlighting the cleavage plane between myoma and myometrium, the pseudocapsule (B).



(a)



(b)



(c)

Figures 4 A-C: Laparoscopic myomectomy should be by intracapsular method: a) clamping myoma by hook or clamps; b) cutting the fibro-vascular connective pseudocapsule bridges, which anchor myoma to myometrium; c) exposing in a manner as detailed as possible the myoma for its enucleation.

All surgeons should always avoid, for example, to open the fibroid in two part and use the myoma surface

to dissect myoma from its pseudocapsule, to better spare it. It only massively bleeds.

The technique of modern laparoscopic, robotic or laparotomic myomectomy is similar to **shish kebab cutting** or **orange peel cleaning**, gently removing the filaments from the beans.

In this way, the surgeon selectively coagulates all the small vessels that are contained in pseudocapsule and that vascularize the fibroids (Figures 5 A-D). The surgeon progressively cut off the surface in contact with the myoma, cutting only the fibrovascular bundle surrounding myoma, enucleating the myoma from the myometrium, as safely and less bleeding as possible [8].

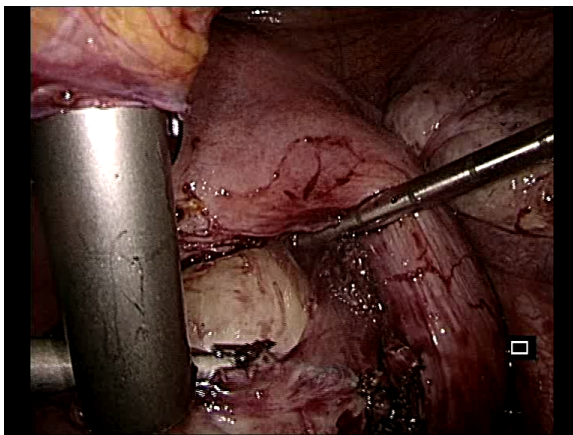
Step 2: Hysterorrhaphy

Suturing of myometrium after myomectomy has always been thought as a very complex surgical problem. On the contrary, it always falls within the

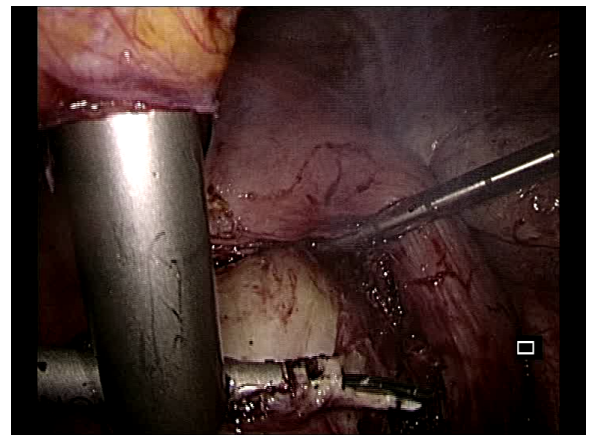
concept of anatomical myometrium, myoma and pseudocapsule. After removal of the myoma (in the manner described above), by the intracapsular myomectomy [9], the myometrium should not bleed excessively.

After myoma enucleating sparing pseudocapsule, surgeon should perform an adequate hysterorrhaphy (Figure 6), following some basic concepts:

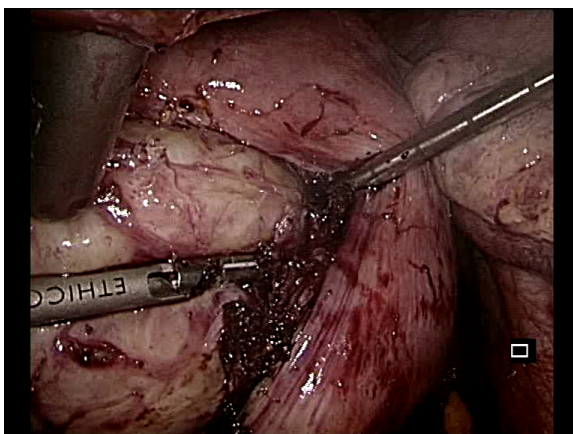
- Myometrial suturing should be with shrewdness, to avoid the large myoma fovea spaces and blood collection inside (damaging the healing process).
- Not too many stitches on myometrium, since it should be nota hemostatic suture, but a plastic suture (as in case of ovarian suturing after ovarian endometrioma removal, where it needs



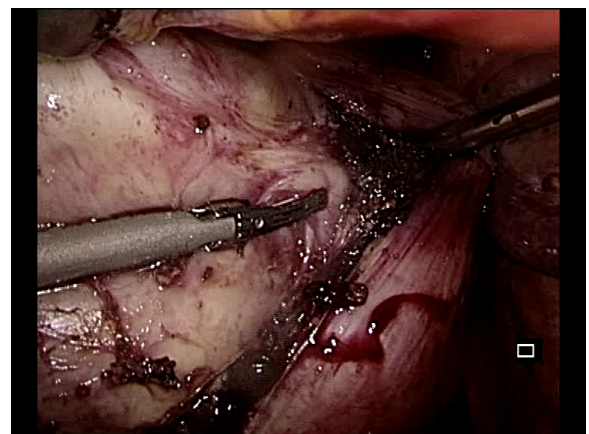
(A)



(B)

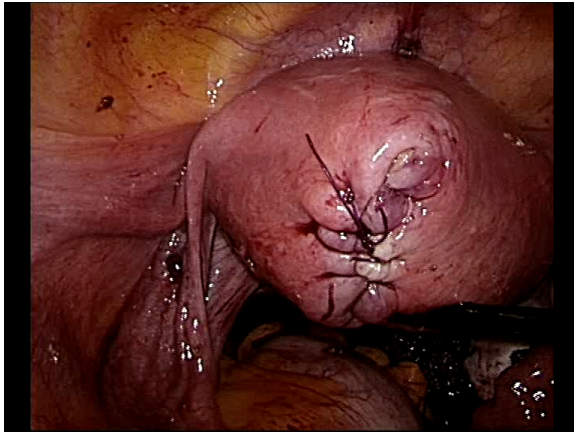


(C)

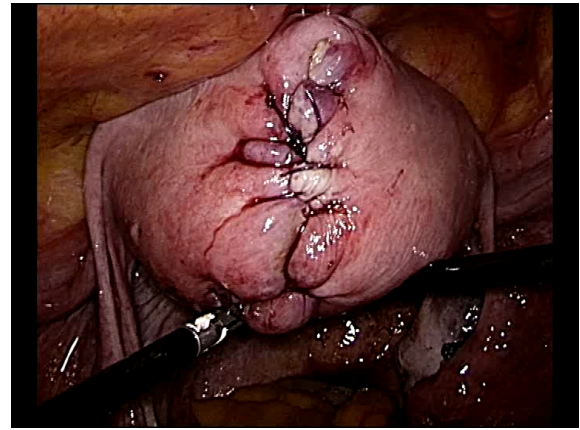


(D)

Figures 5 A-D: Once surgeon find the cleavage plane between myoma and myometrium, the pseudocapsule, myoma should be enucleated by a similar method to shish kebab cutting or orange peel cleaning, as gently removing the filaments from the beans. Surgeon selectively coagulates all the small vessels (fibro-vascular connective pseudocapsule bridges) contained in pseudocapsule, that vascularize the fibroids and anchors it to myometrium.



(A)



(B)

Figures 6 A and B: Hysterorrhaphy after intracapsular myomectomy. Myometrial suturing should be avoiding the myometriaempty spaces with blood collection inside, avoiding too many stitches on myometrium, and they should be adequately applied without excessive force in tie, avoiding: tissue ischemia, hypoxia, necrosis and intramuscular foreign body reaction.

to be spared the functional ovarian tissue and follicles).

- The stiches can be of many kinds (conventional, monofilament, braided wires, barbed) but they should be adequately applied without excessive force in tie, avoiding: tissue ischemia, hypoxia, necrosis and intramuscular foreign body reaction.
- By physiological CO₂ effects, after some minutes later on uterine myorrhaphy, the functional bleeding of the incised visceral peritoneum stops also for the CO₂ pro-coagulant effect [8].
- It should be avoided drains into pelvis after myomectomy (ineffective and harmful for post-operative adhesions) [10]

The same passages are suggested also in cesarean myomectomy, since it was already proved its efficacy in literature by a surgical trial [2].

BLEEDING PROBLEMS DURING MYOMECTOMY: HOW TO SOLVE THEM?

Generally, the achievement of the fibrovascular bundle of pseudocapsule surface is quite easy in every myomectomy. Upon reaching the myomasurface after hysterotomy, the surgeon catches myoma by surgical clamp and pull the myoma outside its fovea, in order to expose the fibrovascular bundle to selectively coagulate and cut (Figure 7). During this maneuver, surgeon does not need to stop the vascular flow to

myometrium to reduce bleeding during myoma enucleation. The uterine stop flow could lead to a potential risk of myometrial/endometrial ischemia.

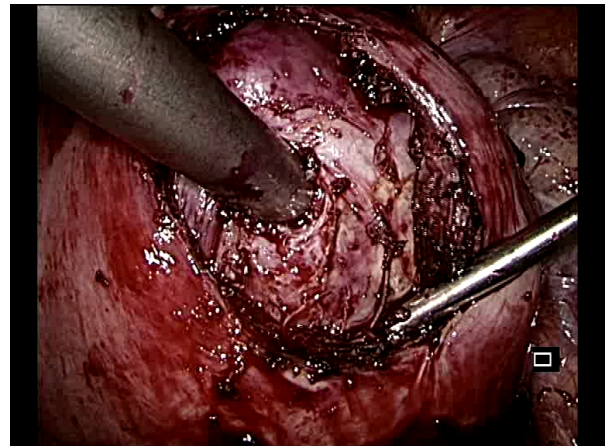


Figure 7: To avoid excessive bleeding, surgeon pulls the myoma outside its fovea, in order to expose the fibrovascular bundles to gently and selectively coagulate and cut them.

On the contrary, because of progressive clotting during myoma enucleation, focused on pseudocapsule gentle sparing (Figure 8), it is very important to avoid two popular maneuvers among surgeons:

- 1) the temporary occlusion of uterine artery by clamps;
- 2) the use of vasopressin into myometrium injection before myomectomy.

Both are not useful and even harmful for the correct healing of myometrium, basing on myoma/myometrial anatomy described below.

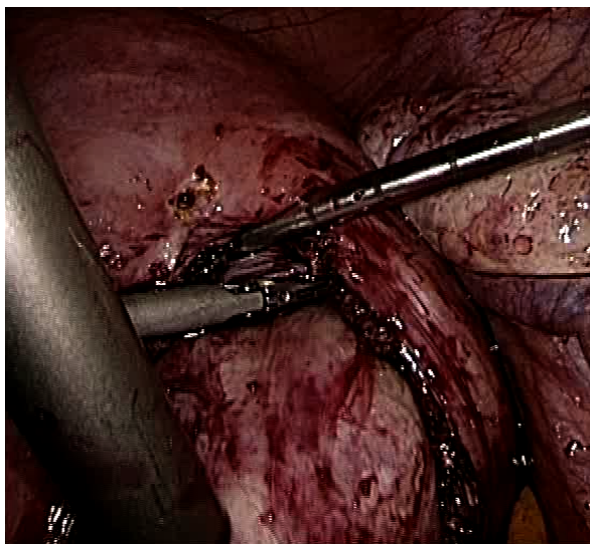


Figure 8: Laparoscopic intracapsular myomectomy by gentle pseudocapsule sparing during myoma enucleation.

Another problem of myometrium temporary devascularization by stop flow is that it could mask the successive bleeding from temporarily collapsed vessels (by uterine artery occlusion or vasopressin injection).

Following these anatomical surgical concepts, a correct modern myomectomy should be performed as in cardiovascular surgery (contemporary to heart beating), without the uterine routine temporary stop-flow, to avoid:

- To mask the fibrovascular cleavage plane [8]
- The collateral pharmacological side effects of vasopressin injection on patient's cardiovascular system [7]
- The possible unexpected postoperative bleeding from scar, after myometrial revascularization (that could lead to post-surgical adhesions)
- The lack of scientific evidence on efficacy of the temporary occlusion of uterine artery or use of vasopressin injection [11] on myometrial/endometrial wellbeing.

Occasionally, during the enucleation of deep intramural fibroids, it can happen that the bleeding is excessive because of the myometrial layer to cross during myoma achievement. This happens especially in case of deep intramural myoma of small volume. Only in such cases, it is reasonable to use the temporary occlusion of uterine artery by clamps or use of vasopressin, to reduce the bleeding prior to enucleate the myoma.

CONTROVERSIES ON LEIOMYOSARCOMA MIS-DIAGNOSIS PRIOR MYOMECTOMY

Some studies reviewed the risk of occult uterine leiomyosarcoma, during surgery for presumed benign fibroids. The prevalence of leiomyosarcoma is 10-fold higher in women older than age 60 years when compared with women younger than age 50 years [12]. Bojahr *et al* reported two occult leiomyosarcoma among 8,720 women having surgery for leiomyomas (0.023%), and reported a prevalence of 2 of 8,720 (0.023%) [13], while Parker *et al*. reported prevalence of 1 in 1,960 (0.051%) with the randomized controlled trials having a prevalence of 0 [14]. Comparing data, the reanalyzed FDA data set yielded a prevalence of 1 in 1,550 (0.064%), while Pritts investigation reported a prevalence of 1 in 1,960 (0.051%) with the randomized controlled trials having a prevalence of 0, and the Bojahr study reported a prevalence of 2 of 8,720 (0.023%). By these data therefore, it is clear that we are in the presence of a very rare event. Moreover, even if leiomyosarcoma was removed intact without morcellation, it has always a poor prognosis. Parker *et al*. I [14], basing on oncological Surveillance, Epidemiology, and End Results data, reported that the 5-year survival of stage I and II leiomyosarcoma was only 61%.

Whether morcellation influences the prognosis of women with leiomyosarcoma is not known and the biology of this tumor has not been well understood. Distant metastasis occurs early in the disease process, primarily by hematogenous dissemination. Four quoted published studies examined patients' survival after power morcellation. Surprisingly, virtually none of the women in these studies had power morcellation. Furthermore, the data presented in these studies have been slightly analyzed and patients' cohorts were very few. The only scientific dogma is that no scientifically reliable method to significantly differentiate, preoperatively, a leiomyoma from a leiomyosarcoma exists (Figure 9) [14].

The proposal methods to investigate, in preoperative set, the leiomyoma characteristics were:

a) Dynamic MRI with serum measurement of lactate dehydrogenase (LDH-3) levels;

b) Gadolinium injection in vein, at the time of the MRI, seeing RMN slides 40-60 seconds after injection, and, if a sarcoma is suspected, the dye will light up the mass on the MRI;

c) The F-fluorodeoxyglucose positron emission tomography [15].

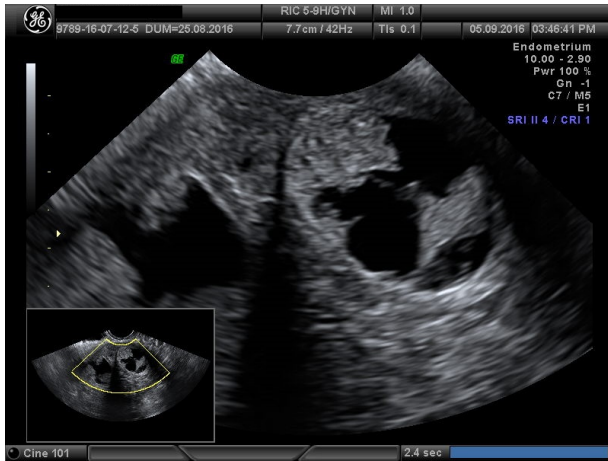


Figure 9: Ultrasonographic evaluation of a myoma in necrotic degeneration.

With these methods, yet under investigation, in the near future, medicine will be able to highlight deserving cases of clinical diagnostic investigation for suspected leiomyosarcoma. On the contrary, the definitive diagnosis of leiomyosarcoma is currently only by histology [16].

An increasing incidence of leiomyosarcoma was observed in patients:

- a) Over 45 years;
- b) Women treated by Tamoxiphen;
- c) Patients treated by Radiotherapy [14].

In these selected patients, the incidence on leiomyosarcoma is increased comparing with other

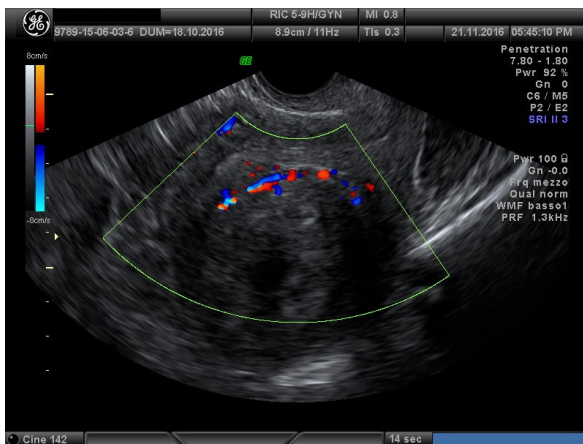
patients, in which the biology of the leiomyoma is completely different from leiomyoma, as they have a different biological characterization. Generally, leiomyosarcoma arises from a new cell clone different from the cell clone of leiomyoma; leiomyosarcoma born, thus, "de novo" and it does not originate in a leiomyoma. Finally, the myoma always has a pseudocapsule (detected by ultrasonographic Doppler scan, as a "ring of fire") (Figure 10) [17], but the leiomyosarcoma not routinely [18].

DOUBTS ON SAFENESS OF "IN BAG" MORCELLATION TO AVOID A POSSIBLE LEIOMYOSARCOMA SPREADING

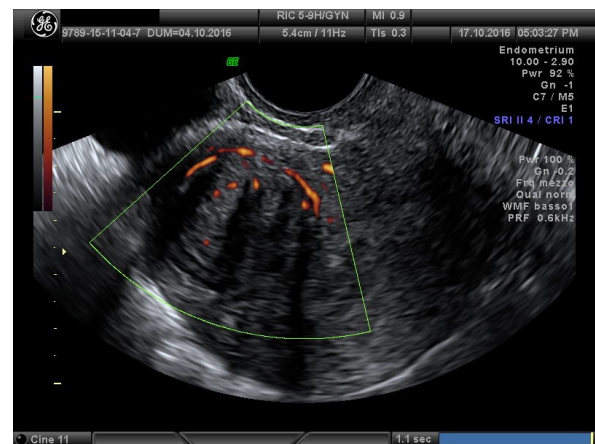
From the beginning of its use, laparoscopic-aided morcellation allowed the surgeon to inspect the pelvic and abdominal cavities and to irrigate and to remove tissue fragments under visual magnification. On the contrary, the surgeon cannot visually inspect the peritoneal cavity during vaginal or minilaparotomy procedures. Morcellation within containment bags has recently been used in an attempt to avoid spread of tissue. These methods have not yet been proven effective or safe, and there is concern that bags may make morcellation more cumbersome and less safe.

There are no scientific studies showing that the use of the bag in myoma morcellation:

- 1. can improve the prognosis of leiomyosarcoma, can reduce the risk cancer spreading (when coring tumor from the uterus);
- 2. can lead to a reduction staging compared to morcellation out of bags, when surgeon coring the "cancer mass" from uterus.



(A)



(B)

Figures 10 A and B: Myoma always has a pseudocapsule, detected by ultrasonographic Doppler scan, as a "ring of fire".

At this point, thinking about the scientific data, we could make a comparison between two clinical unsolved problems: the use of the "in bag morcellation" to reduce undiagnosed leiomyosarcoma during myomectomy and the use of caesarean section to avoid a possible risk of shoulder dystocia. Given the absolute low rate of leiomyosarcoma after myomectomy, the problem of unnecessary "in bag" myoma morcellation for the hypothetic risk of occulted leiomyosarcoma could be compared to a famous obstetric study. Rouse *et al.* [19] examined the cost-effectiveness of a caesarean delivery to reduce shoulder dystocia risk, for suspected macrosomia in nondiabetic mothers with estimated weight greater than 4,500 grams: They concluded that, in order to prevent JUST ONE case of permanent brachial plexus injury, 3,695 caesarean sections would need to be performed (at a cost of US\$8.7 million) [19]. If we think to both these supposed risks and the related costs of time and surgery, we could be more realistic in our daily surgery.

In fact, the "in bag" morcellation, recommended by many surgeons to reduce an hypothetic risk of leiomyosarcoma spreading after myomectomy led to:

a) Unjustified increase of the times of laparoscopy and robotics, against hypothetical benefits that the bag can support (time consuming);

b) An unjustified increase of the possible complications during in bag morcellation, as additive scientifically untested surgical time, to an overall increase of the intervention costs (bags and times).

One final thought is on myoma fragments spreading during morcellation. These fragments may be the cause of the parasitic leiomyomas (Figure 11), probably related to the incorrect myomectomy technique. If leiomyoma is removed from the uterus with part of the pseudocapsule on its surface during fibroid morcellation, adequate caution should be exercised to remove all myoma fragments. Myoma pseudocapsule has a proper very active angiogenesis [20] and the myoma fragments surrounded by pseudocapsule could attach the peritoneal surface during morcellation, the muscle or other organs. It could create, by its own angiogenesis, the maintenance and growth of myoma at the implantation site, so called the parasitic leiomyomas. This could be the real benefit of the "in bag" morcellation after myomectomy.

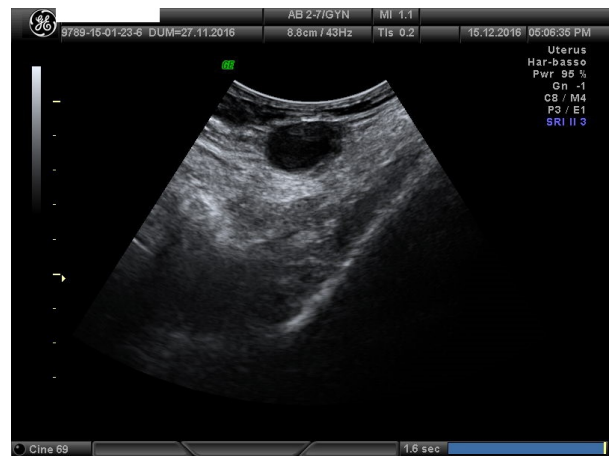


Figure 11: Ad abdominal ultrasonographic scan showing a parasitic leiomyoma near the oblique muscle of the rectus, where it had been positioned the ancillary trocar.

REFERENCES

- [1] Tinelli A, Sparic R, Kadija S, Babovic I, Tinelli R, Mynbaev OA, Malvasi A. Myomas: anatomy and related issues. *Minerva Ginecol.* 2016; 68(3): 261-73.
- [2] Tinelli A, Malvasi A. Uterine fibroid pseudocapsule. In: Tinelli A, Malvasi A. *Uterine myoma, myomectomy and minimally invasive treatments*; Springer Berlin 2015; 73-93. https://doi.org/10.1007/978-3-319-10305-1_6
- [3] Tinelli A, Malvasi A, Cavallotti C, Dell'Edera D, Tsin DA, Stark M, Mettler L. The management of fibroids based on immunohistochemical studies of their pseudocapsules. *Exp Opin Ther Targets* 2011; 15: 1241-7. <https://doi.org/10.1517/14728222.2011.616196>
- [4] Tinelli A, Malvasi A, Rahimi S, Negro R, Cavallotti C, Vergara D *et al.* Myoma pseudocapsule: a distinct endocrino-anatomical entity in gynecological surgery. *Gynecol Endocrinol* 2009; 25(10): 661-7. <https://doi.org/10.1080/09513590903015502>
- [5] Malvasi A, Cavallotti C, Morroni M, Lorenzi T, Dell'Edera D, Nicolardi G *et al.* Uterine fibroid pseudocapsule studied by transmission electron microscopy. *Eur J Obstet Gynecol Reprod Biol* 2012; 162: 187-91. <https://doi.org/10.1016/j.ejogrb.2012.02.017>
- [6] Ito F, Kawamura N, Ichimura T, Tsujimura A, Ishiko O, Ogita S. Ultrastructural comparison of uterine leiomyoma cells from the same myoma nodule before and after gonadotropin-releasing hormone agonist treatment. *Fertil Steril* 2001; 75(1): 125-30. [https://doi.org/10.1016/S0015-0282\(00\)01660-5](https://doi.org/10.1016/S0015-0282(00)01660-5)
- [7] Tinelli A, Malvasi A, Hurst BS, Tsin DA, Davila F, Dominguez G *et al.* Surgical management of neurovascular bundle in uterine fibroid pseudocapsule. *JLS* 2012; 16(1): 119-29. <https://doi.org/10.4293/108680812X13291597716302>
- [8] Tinelli A, Mettler L, Malvasi A, Hurst B, Catherino W, Mynbaev OA *et al.* Impact of surgical approach on blood loss during intracapsular myomectomy. *Minim Invasive Ther Allied Technol* 2014; 23(2): 87-95. <https://doi.org/10.3109/13645706.2013.839951>
- [9] Tinelli A, Hurst BS, Hudelist G, Tsin DA, Stark M, Mettler L *et al.* Laparoscopic myomectomy focusing on the myoma pseudocapsule: technical and outcome reports. *Hum Reprod* 2012; 27(2): 427-35. <https://doi.org/10.1093/humrep/der369>
- [10] Mynbaev OA, Malvasi A, Melerzanov AV, Stark M, Tinelli A. Abdominopelvic drainage during laparoscopic myomectomy: left-over hook or still relevant? *Eur J Obstet Gynecol Reprod*

- Biol 2015; 191: 138-9.
<https://doi.org/10.1016/j.ejogrb.2015.05.002>
- [11] Kongnyuy EJ, Wiysonge CS. Interventions to reduce haemorrhage during myomectomy for fibroids. *Cochrane Database Syst Rev* 2014; 15; (8): CD005355.
<https://doi.org/10.1002/14651858.cd005355.pub5>
- [12] Pritts EA, Vanness DJ, Berek JS, Parker W, Feinberg R, Feinberg J, Olive DL. The prevalence of occult leiomyosarcoma at surgery for presumed uterine fibroids: a meta-analysis. *Gynecol Surg* 2015; 12(3): 165-177.
<https://doi.org/10.1007/s10397-015-0894-4>
- [13] Bojahr B, De Wilde R, Tchartchian G. Malignancy rate of 10,731 uteri morcellated during laparoscopic supracervical hysterectomy (LASH). *Arch Gynecol Obstet* 2015; 292: 665-72.
<https://doi.org/10.1007/s00404-015-3696-z>
- [14] Parker WH, Kaunitz AM, Pritts EA, Olive DL, Chalas E, Clarke-Pearson DL, Berek JS; Leiomyoma Morcellation Review Group. U.S. Food and Drug Administration's Guidance Regarding Morcellation of Leiomyomas: Well-Intentioned, But Is It Harmful for Women? *Obstet Gynecol* 2016; 127(1): 18-22.
<https://doi.org/10.1097/AOG.0000000000001157>
- [15] Bolan C, Caserta MP. MR imaging of atypical fibroids. *Abdom Radiol (NY)* 2016; 41(12): 2332-2349.
<https://doi.org/10.1007/s00261-016-0935-0>
- [16] Wen KC, Horng HC, Wang PH, Chen YJ, Yen MS, Ng HT; Taiwan Association of Gynecology Systematic Review Group. Uterine sarcoma Part I-Uterine leiomyosarcoma: The Topic Advisory Group systematic review. *Taiwan J Obstet Gynecol.* 2016; 55(4): 463-71.
<https://doi.org/10.1016/j.tjog.2016.04.033>
- [17] Tinelli A, Mynbaev OA, Sparic R, Vergara D, Di Tommaso S, Salzet M *et al.* Angiogenesis and vascularization of uterine leiomyoma: clinical value of pseudocapsule containing peptides and neurotransmitters. *Curr Protein Pept Sci* 2016; 22. [Epub ahead of print]
<https://doi.org/10.2174/1389203717666160322150338>
- [18] Resta L. Uterine myomas and histopathology. In: Tinelli A, Malvasi A. *Uterine myoma, myomectomy and minimally invasive treatments*; Springer, Berlin 2015; 27-38.
https://doi.org/10.1007/978-3-319-10305-1_3
- [19] Rouse DJ, Owen J, Goldenberg KL, Cliver SP. The effectiveness and costs of elective caesarean delivery for fetal macrosomia diagnosed by ultrasound. *Jama* 1996; 276: 1480-1486
<https://doi.org/10.1001/jama.1996.03540180036030>
- [20] Rizzello A, Franck J, Pellegrino M, De Nuccio F, Simeone P *et al.* A proteomic analysis of human uterine myoma. *Curr Protein Pept Sci* 2016; 22. [Epub ahead of print]

Received on 01-03-2017

Accepted on 03-04-2017

Published on 12-04-2017

<http://dx.doi.org/10.15379/2408-9761.2017.04.01.03>

© 2017 Andrea Tinelli; Licensee Cosmos Scholars Publishing House.

This is an open access article licensed under the terms of the Creative Commons Attribution Non-Commercial License

[\(http://creativecommons.org/licenses/by-nc/3.0/\)](http://creativecommons.org/licenses/by-nc/3.0/), which permits unrestricted, non-commercial use, distribution and reproduction in any medium, provided the work is properly cited.