

# An Interesting Solid Mass in the Posterior Maxilla of a Pregnant Woman

Can Engin Durmaz<sup>1</sup>, Aydın Gülses<sup>1</sup>, Yaşam Kemal Akpak<sup>2,\*</sup> and Nilay Karaca<sup>3</sup>

<sup>1</sup>Ankara Mevki Military Hospital, Dental Service, Ankara, Turkey

<sup>2</sup>Ankara Mevki Military Hospital, Department of Obstetrics and Gynecology, Ankara, Turkey

<sup>3</sup>Bezmialem University Hospital, Department of Obstetrics and Gynecology, Istanbul, Turkey

**Abstract:** We report a case of a 22 year-old pregnant woman who was considered in the differential diagnosis included an erupted odontoma and an exposed necrotic bone of the maxilla at the time of the third trimester. During the 4<sup>th</sup> week of the postpartum period, an orthopantomography was taken and radiopaque mass and ill-defined impacted molar teeth were observed. After the surgical operation, the final diagnosis of ossifying fibroma was rendered. Ossifying fibromas behave like benign bone neoplasms and are often considered to be a type of fibro-osseous lesions. They can affect both the mandible and the maxilla, particularly the mandible. Fibroosseous lesions with unusual clinical and radiological presentations might disquieten both the dental practitioner and the patient.

**Keywords:** Dental surgery, Gingival overgrowth, Ossifying fibroma, Ossifying variant, Postpartum, Pregnancy.

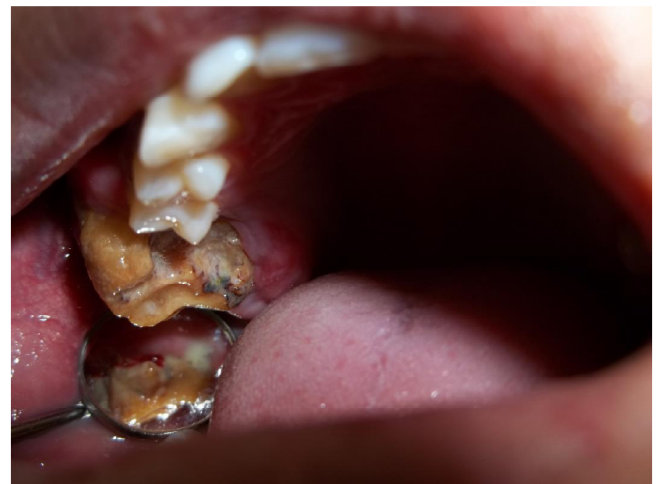## INTRODUCTION

Benign fibro-osseous lesions be divided into 3 categories, including fibrous dysplasia, ossifying fibroma, and osseous dysplasia [1]. Clinically, ossifying fibromas (OF) are most common in the mandibular-premolar region of female patients and has a benign behavior. They occur at second to fourth decade of life. The certain pathogenesis is still undefined, but trauma-induced stimulation may play a effective role. Radiologically the lesion appears as a dense radiopaque mass surrounded by a thin, well-defined regular radiolucent rim [2]. Surgery is the treatment of choice, though the recurrence rate could reach about 20% so generally, the recommended treatment for OF is complete excision of the tumor [2]. We report a case of OF in a 22 year-old pregnant woman. The purpose of this case is to evaluate this benign bone neoplasm and to underline the steps of the radiological and pathological diagnosis; thus, to make some contribution to the literature.

## CASE REPORT

A 22-year-old pregnant woman admitted to our department with the complaints of pain and swelling in the right maxillary region. Intraoral examination revealed the presence of a solid mass resembling a malformed molar tooth (Figure 1). There was no fluctuant swelling, drainage or fistula. According to the

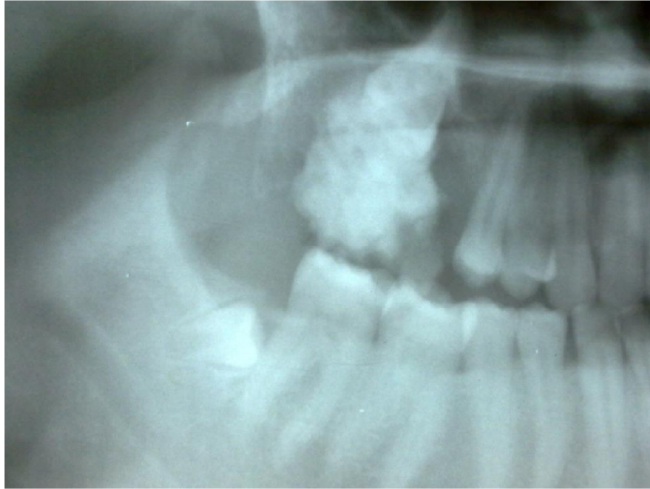
patient's history, she has noticed the lesion during the third trimester of her pregnancy and attended to a dental practitioner. However, her dentist has denied to take an orthopantomography (OPTG) and removal of the mass due to the the pregnancy and delayed the ablative surgery to the end of the pregnancy. After consultation with her obstetricians during the 4<sup>th</sup> week of the postpartum period, an OPTG was taken and radiopaque mass and ill-defined impacted molar teeth were observed (Figure 2). The patient was referred to our hospital due to the necessity of an operation general anesthesia. After a provisional diagnosis had been made, complete removal of the lesion was performed and the adjacent impacted molar tooth was extracted under general anaesthesia. The patient was operated under general anesthesia via oroendotracheal



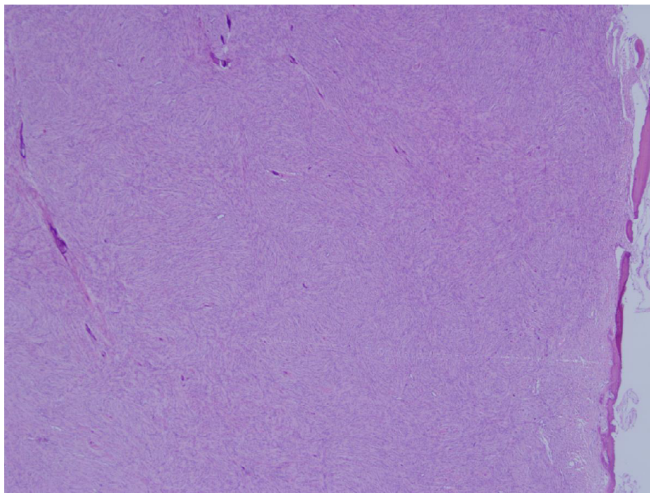
**Figure 1:** Intraoral view of the mass.

\*Address correspondence to this author at the Department of Obstetrics and Gynecology, Ankara Mevki Military Hospital, Ankara, Turkey 06100; Tel: +90 533 4876138; Fax: +90 312 2220583; E-mail: yasamaster@gmail.com

intubation. A full thickness mucoperiosteal flaps was raised and the lesion and the impacted molar were totally removed. The final histopathologic evaluation revealed highly cellular fields with calcified areas (Figure 3) and the final diagnosis of ossifying fibroma was rendered. After one year follow up, no pathological alterations were detected.



**Figure 2:** Radiography of the lesion. Please note the adjacent impacted molar.



**Figure 3:** Photomicrograph of the histopathological examination (H&E staining) of the lesion showing highly cellular fields with calcified areas ( $\times 10$ ).

## DISCUSSION

OF behave like benign bone neoplasms and are often considered to be a type of fibro-osseous lesions. They can affect both the mandible and the maxilla, particularly the mandible. This bone tumour consists of highly cellular, fibrous tissue that contains varying amounts of calcified tissue resembling bone and/or

cementum [3]. Eversole *et al* [4] have described the radiographic characteristics of OF, and two major patterns were noted, expansile unilocular radiolucencies and multilocular configuration. Kumar *et al* [5] have suggested that considerable confusion has prevailed in the nomenclature of ossifying fibromas. According to Eversole *et al* [4], when bone and cementum-like tissues are observed, the lesions have been referred to as cemento-ossifying fibroma.

The case reported herein was an unusual presentation of an ossifying fibroma thus the lesion has been exposed to the oral cavity and was observed during the pregnancy. It is obvious that pregnancy could be associated with granulomatous epithelial lesions such as granuloma gravidarum or pyogenic granuloma, however, it is not possible to associate OF with pregnancy [6]. To our opinion, first, the lesion was thought to be a upper first molar with a caries. Following the further exposure to the oral cavity, it started to differ from a carious tooth and the patient has started to seek treatment.

The differential diagnosis included an erupted odontoma and an exposed necrotic bone of the maxilla must be considered. Odontomas are the most common type of odontogenic tumors and they are often associated with permanent or temporary tooth eruption disturbances. Peripheral odontoma arising in the extra osseous soft tissues is rare and if not removed early, may enlarge over time and eventually erupt in the oral cavity [7]. Although the odontomas erupting in the oral cavity are controversial, the reason is attributed to the eruptive forces of the apparently impacted teeth [8].

Hanemann *et al.* [7] have suggested that there is a predilection for children and young persons and in over 50% of cases the erupted odontomas affected the palatal region. In the current case, the age of the patient was in accordance with the literature; however the lesion has not affected the palatal region.

The clinical examination of the current case was also resembling an intraorally-exposed necrotic bone. Nowadays, the term "osteonecrosis of the jaw (ONJ) is used almost synonymously with the term "bisphosphonate-associated ONJ." However, necrosis of the jawbones leading to exposure of bone is associated with other factors [9, 10]. Almazroa and Woo [9] have conducted a literature search and divided the causes of ONJ into the following conditions: systemic medication use; radiation; bacterial, viral and

deep fungal infections; direct chemical toxicity; trauma; idiopathy; etc. None of the above mentioned conditions and signs or symptoms was present in the medical history of the current case. In addition, radiological findings were inconsistent with the findings of a necrotic bone.

## CONCLUSION

Radiological features of oral lesions during pregnancy can vary and every additional report can further help us to diagnose this unusual presentations. In addition, fibroosseous lesions with unusual clinical and radiological presentations might disquieten both the dental practitioner and the patient. Therefore, discussion of the differential diagnosis should be done very carefully to prevent unnecessary distress to the patient.

## ACKNOWLEDGEMENTS

None

## CONFLICT OF INTEREST

None

## FUNDING SOURCE

None

## REFERENCES

- [1] Amaral MB, Souto GR, Horta MC, Gomez RS, Mesquita RA. Ossifying odontogenic fibroma: A rare case report. *J Clin Exp Dent* 2014; 6: 588-91. <http://dx.doi.org/10.4317/jced.51440>
- [2] Vura NG, Gaddipati R, Ramiseti S, Kumara R, Reddy R, Kanchi U. Surgical Management of Ossifying Fibroma in Maxilla: Report of Two Cases. *J Int Oral Health* 2015; 7: 115-8.
- [3] Liu Y, Wang H, You M, et al. Ossifying fibromas of the jaw bone: 20 cases. *Dentomaxillofac Radiol* 2010; 39: 57-63. <http://dx.doi.org/10.1259/dmfr/96330046>
- [4] Eversole LR, Leider AS, Nelson K. Ossifying fibroma: a clinicopathologic study of sixty-four cases. *Oral Surgery Oral Medicine and Oral Pathology* 1985; 60: 505-11. [http://dx.doi.org/10.1016/0030-4220\(85\)90239-7](http://dx.doi.org/10.1016/0030-4220(85)90239-7)
- [5] Kumar SK, Ram S, Jorgensen MG, Shuler CF, Sedghizadeh PP. Multicentric peripheral ossifying fibroma. *Journal of Oral Science* 2006; 48: 239-43. <http://dx.doi.org/10.2334/josnusd.48.239>
- [6] Cornejo C, Rossi G, Rama A, et al. Oral health status and oral health-related quality of life in pregnant women from socially deprived populations. *Acta Odontol Latinoam* 2013; 26: 68-74.
- [7] Hanemann JA, Oliveira DT, Garcia NG, Santos MR, Pereira AA. Peripheral compound odontoma erupting in the gingiva. *Head Face Med* 2013; 9: 15. <http://dx.doi.org/10.1186/1746-160X-9-15>
- [8] Vengal M, Arora H, Ghosh S, Pai KM. Large erupting complex odontoma: a case report. *J Can Dent Assoc* 2007; 73: 169-73.
- [9] Almazrooa SA, Woo SB. Bisphosphonate and nonbisphosphonate-associated osteonecrosis of the jaw: a review. *J Am Dent Assoc* 2009; 140: 864-75. <http://dx.doi.org/10.14219/jada.archive.2009.0280>
- [10] Badel T, Pavicin IS, Carek AJ, Rosin-Grgset K, Grbesa D. Pathophysiology of osteonecrosis of the jaw in patients treated with bisphosphonate. *Coll Antropol* 2013; 37: 645-51.

Received on 09-09-2015

Accepted on 08-10-2015

Published on 25-11-2015

<http://dx.doi.org/10.15379/2408-9761.2015.02.03.03>

© 2015 Durmaz *et al.*; Licensee Cosmos Scholars Publishing House.

This is an open access article licensed under the terms of the Creative Commons Attribution Non-Commercial License

(<http://creativecommons.org/licenses/by-nc/3.0/>), which permits unrestricted, non-commercial use, distribution and reproduction in any medium, provided the work is properly cited.