

Ovarian Sclerosing Stromal Tumour Presenting with Pseudo-Meigs' Syndrome

Ashu Loona, David O'Neill and Suha Deen*

Department of Histopathology, Nottingham University Hospitals NHS Trust, Derby Road Nottingham NG7 2UH UK

Abstract: Sclerosing stromal tumour (SST) is an uncommon ovarian sex-cord stromal neoplasm that has distinctive clinical, pathological and radiological features. Unlike other stromal tumours, which commonly present in the fifth and sixth decades, it occurs predominantly in the second and third decades, typically in the early 20s [1]. As SST is rare, reports of unusual presentations might assist diagnosis.

Keywords: Ovary, Childhood, Germ cell tumour, Sclerosing stromal tumour.

INTRODUCTION

Case Report

We would like to report a 15 year old girl who presented with abdominal pain. On examination there was a large mass arising from the pelvis. A transabdominal ultrasound scan was performed and demonstrated a 20 cm solid and cystic left ovarian mass. Tumour marker profile showed a raised serum CA-125 at 325 units. The serum human chorionic gonadotrophin and alpha-fetoprotein were normal. At laparotomy, the ovarian mass did not involve the uterus or bowel and a moderate quantity of ascites was noted.

On macroscopic examination (Figure 1), the mass appeared to be predominantly solid, nodular, weighing 1750 grams. The surface was focally roughened albeit with intact capsule. Sectioning revealed a homogeneous rubbery meaty brown cut surface with focal haemorrhage at one end. Numerous smooth thin-walled cystic locules present, the largest 40 mm in maximal diameter and filled with clear serous fluid.

Microscopically, the ovarian tumour comprised monotonous sheets of polygonal cells showing alternating cellular and oedematous hypocellular areas (Figure 2, inset). Focally, tumour cells demonstrated clear cytoplasm. They were separated by scattered short wisps of collagen. Reticulin stain highlighted organisation into short fascicles without obvious pericellular deposition. Occasional mitotic figures were noted (up to 2 per 10 high power fields), mainly in the

region adjacent to the area of haemorrhage. An absence of organisation within the haematoma suggested surgical artefact. Well-developed sclerotic stroma was not a feature.

Despite generous sampling, the haemangiopericytoma-like branching vascular pattern was seen in only one block (Figure 2).

Tumour cells were immunopositive for CD117, CD56, Smooth Muscle Actin and, focally CD10. Whereas negative staining was reported for S100-protein, Melan A, HMB45, CD31, CD34, Inhibin, CA125, Calretinin, Ber ep4, cam 5.2, AE1/AE3, WT1, ER, PR, CD99 or Desmin. Nuclear positivity for Ki-67 was seen in approximately 5% of the tumour cells.

The case presented clinically as pseudo-Meigs' Syndrome and demonstrated the characteristic morphological features of SST which included haemangiopericytoma-like pattern and oedematous hypocellular areas, albeit without a distinctive nodular pattern.

Meigs suggested that the ascites might arise from local irritation of peritoneal surfaces by the solid ovarian tumour leading to over-production of peritoneal fluid [2]. Samantha and Black offered an alternative hypothesis that the ascitic fluid might be secreted by ovarian tumours that are larger than 10cm and feature an oedematous myxoid element [3]. We also speculate that the oedematous areas within the current tumour may have contributed to the production of ascitic fluid.

Interestingly, in this case, despite the presence of elevated serum CA-125, it was not possible to demonstrate expression of this marker in the tumour cells using immunohistochemistry. This raises the

*Address correspondence to this author at the Department of Histopathology Queen's Medical Centre campus Nottingham University Hospitals NHS Trust Derby Road Nottingham NG7 2UH; Tel: +44 0115 9249924; Fax: 0115 9709479; E-mail: sdeen@doctors.org.uk

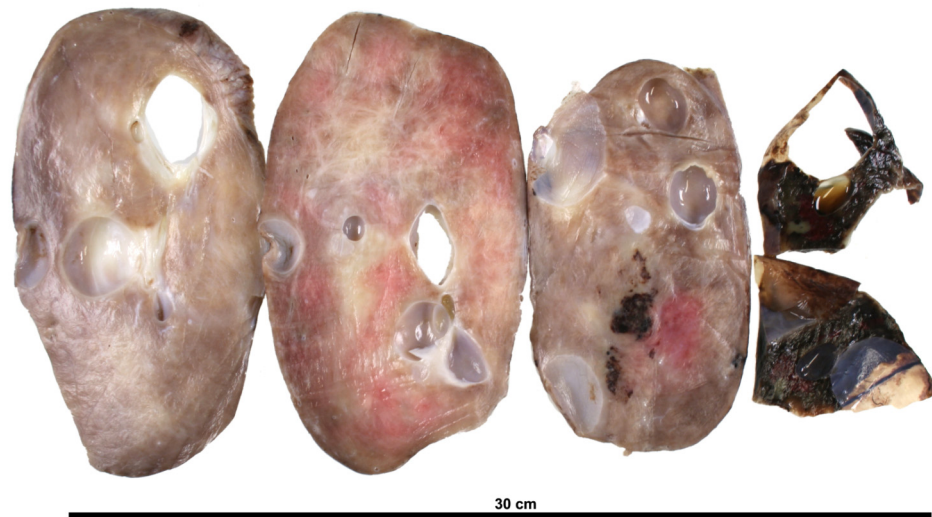

Figure 1: Solid mass with a homogeneous rubbery meaty brown cut surface and focal haemorrhagic area at one end. Smooth thin-walled cystic locules are seen, the largest 40 mm in maximal diameter.

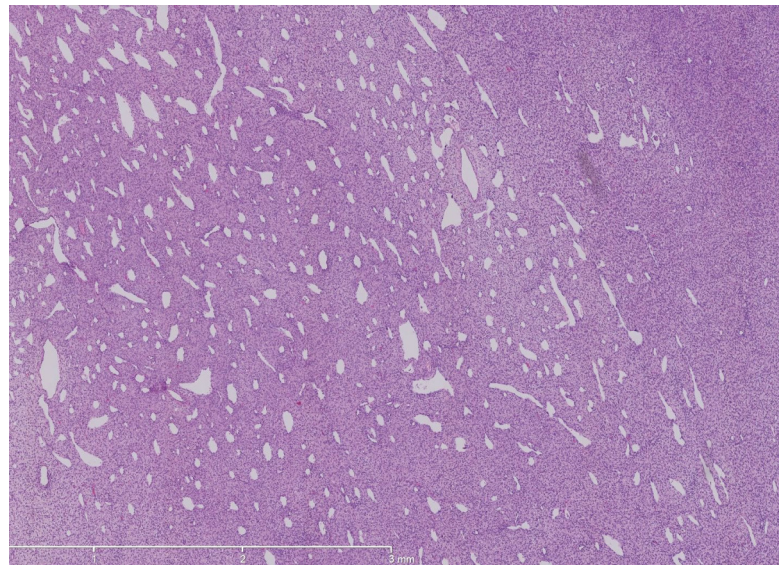


Figure 2: Focal haemangiopericytoma-like branching vascular pattern x4. Inset, the tumour shows alternating cellular and oedematous hypocellular areas x4.

possibility that raised serum CA-125 was caused by mesothelial irritation secondary to tumour expansion and accumulation of ascitic fluid. This is consistent with recent reports of elevated serum CA-125 levels in patients with advanced chronic heart failure due to increased neurohormonal activation [4, 5].

In summary, we report a case of ovarian sclerosing tumour with an unusual clinical presentation characterised by pseudo-Meigs' syndrome associated with raised serum CA-125, featuring only focal distribution of characteristic morphological changes and without overt tumoural expression of CA-125.

REFERENCES

- [1] Metu akbulut *et al.* Sclerosing stromal tumour of the ovary: Report of a case and review of literature. *Aegean pathology journal* 2004; 1: 84-89.
- [2] Meigs JV. Fibroma of the ovary with ascites and hydrothorax; Meig's syndrome. *Am J Obs Gynecol.* 1954; 67(5): 962-985.
- [3] Samantha KK, Black WC. Benign ovarian stromal tumors associated with free peritoneal fluid. *Am J Obstet Gynecol.* 1970; 107(4): 538-45.
- [4] Duman D, Palit F, Simsek E, Bilgehan K. Serum carbohydrate antigen 125 levels in advanced heart failure: Relation to B-type natriuretic peptide and left atrial volume. *The European Journal of Heart Failure;* 10(2008); 556-559.

- [5] Kouris NT, Zacharos ID, Kontogianni DD, Goranitou GS, Sifaki MD, Grassos HE, *et al.* The significance of CA125 levels in patients with chronic congestive heart failure. Correlation with clinical and echocardiographic parameters. The European Journal of Heart Failure 2005; 199-203

Received on 19-10-2014

Accepted on 11-11-2014

Published on March-2015

<http://dx.doi.org/10.15379/2408-9761.2015.02.01.7>

© 2015 Loona *et al.*; Licensee Cosmos Scholars Publishing House.

This is an open access article licensed under the terms of the Creative Commons Attribution Non-Commercial License

(<http://creativecommons.org/licenses/by-nc/3.0/>), which permits unrestricted, non-commercial use, distribution and reproduction in any medium, provided the work is properly cited.