

# Band Sequence - Past, Present and Future

Suresh Chandran<sup>1,2,3,4,\*</sup> and Gopagondanahalli Krishna Revanna<sup>1</sup>

<sup>1</sup>Department of Neonatology, KK Women's and Children's Hospital, Singapore

<sup>2</sup>Duke-NUS Graduate School of Medicine, Singapore

<sup>3</sup>Yong Loo Lin School of Medicine, National University of Singapore, Singapore

<sup>4</sup>Lee Kong Chian School of Medicine, Nanyang Technological University, Singapore

**Abstract:** Amniotic band sequence (ABS) is a constellation of congenital malformations involving mostly distal extremities, less often craniofacial and visceral defects. It is often characterized by the asymmetry of the organ involvement and can manifest with varying severity. Amniotic band sequence lacks a precise definition and pathogenic mechanism, with the extrinsic theory of "Early amnion rupture sequence" being the most widely accepted hypothesis. Using 3-dimension (3D) or 4-dimension (4D) ultrasound scans, ABS related fetal diagnoses can be made early in pregnancy facilitating fetal interventions. Today with minimally invasive fetal surgery, the amniotic bands can be released to save a limb or to avoid a fetal death due to amniotic band constriction of the umbilical cord. To date, no definite genetic basis has been known for the defects seen in ABS. Published articles; monographs and personal experience in fetal and neonatal diagnosis of ABS have contributed extensively to this review article.

**Keywords:** Amniotic band syndrome, Amniotic band sequence, Limb body wall complex.

## INTRODUCTION

Amniotic band sequence is the term applied to a highly variable spectrum of complex congenital anomalies that occur in association with amniotic bands. Etiology of ABS is still obscure and many theories have been put forth to explain the defect. It has been addressed with many names such as Streeter's dysplasia, amnion rupture sequence, ADAM (amniotic deformities/adhesions/mutilations) complex, amniotic band syndrome; congenital constriction band and limb body wall complex (LBWC). The severity of deformities in ABS is variable. This state of the art review article covers the historic aspects, epidemiology, pathogenesis, clinical features, diagnosis and treatment of ABS.

## HISTORICAL PERSPECTIVE

ABS has intrigued great scholars like Hippocrates and Aristotle as early as 300 BC. Hippocrates first suggested that extrinsic forces in utero might be the cause of malformations of the extremities in fetus [1, 2]. In 1652, J.B van Helmont reported intrauterine amputation, of which he attributed the condition to mothers having observed maimed soldiers early in their pregnancies [1]. Montgomery (1832) and Simpson (1836) described patterns of deformities associated

with amniotic bands [2, 3]. George Streeter (1930) postulated the germ plasm theory that became popular as it explained the anomalies occurring away from the site of constriction [4]. Patterson (1961) explained the lack of mesodermal development as a cause of constriction ring as they resembled normal skin creases on histological examination [5]. Torpin (1965) later refuted this theory. Torpin proposed the theory of extrinsic constriction by encircling strands, which was originally proposed by Hippocrates [6]. Even though widely accepted, many authors still debate over Torpin's theory, that it may not explain many of the defects that occur in ABS.

## PATHOGENESIS

There are three theories explaining the pathogenesis: the germplasm theory of Streeter (intrinsic), the early amnion rupture sequence theory of Torpin (extrinsic) and the vascular disruption theory of Van Allen [7].

George Streeter, the director of embryology at Carnegie Institute, proposed primary failure in development of the amniotic cavity and limb buds from imperfect histogenesis as the cause of ABS [4]. Streeter's intrinsic theory proposed a genetic etiology due to germ plasm defects and hence, was named "fetal focal dysplasia". According to this theory a disrupting event during blastogenesis leads to focal mesenchymal hypoplasia, tissue loss and later scarring. This theory is supported by the case in which

\*Address correspondence to this author at the Department of Neonatology KK Women's and Children's Hospital Singapore 229899; Tel: (65) 91799244; Fax: (65) 62919079; E-mail: schandran1312@yahoo.co.uk

the affected fetus is born with intact amnion and also explains the occurrence of other internal organ involvement where amniotic band could not have reached. McKenzie supported the intrinsic theory and suggested that the defective tissue at the site of constriction reflects programmed cell death, a normal physiological process in embryogenesis [8]. In 1992, Bamforth re-examined Streeter's hypothesis of "germ plasm theory". He concluded that LBWC might be caused by a localized disturbance in establishment of embryonic organization [9].

Richard Torpin, an obstetrician proposed the "extrinsic theory" to explain the etiology of ABS [6]. At 12<sup>th</sup> week of gestation, amnion fuses with chorion, obliterating the extra embryonic coelom. Torpin proposed the "early amnion rupture sequence" theory, where early amnion rupture is the precipitating event. The amniotic cavity ceases to grow and progressively separates from the chorion, followed by loss of amniotic fluid and extrusion of all or parts of the fetus into the chorionic cavity. Transient oligohydramnios ensues and aggravates the deformations seen in ABS. Following rupture of the amniotic membrane multiple mesoblastic fibrous strings emanate from the chorionic side of the amnion which is thought to entangle or entrap fetal parts. Chandran *et al* has reported the first case of acalvaria with ABS in the literature [10]. This case supports Torpin's hypothesis, with failure of the cranial bones to develop at the site of attachment of amniotic bands, as stated in his monograph [11]. Torpin's theory is now widely accepted however, fails to explain affected fetuses with intact amnion, and those with involvement of internal organs.

Higginbottom *et al* reported that deformation, malformation or disruption occurs, depending on the time of amnion rupture during gestation [12].

Vascular disruption theory (VDT), proposed by Van Allen *et al* (1987), described that vascular disruption plays a role on normal embryonic blood supply during embryogenesis and can interrupt morphogenesis and damage existing structures [7]. Several animal studies to date have since supported the VDT [13, 14]. Vascular compromise as a primary pathogenic mechanism was proposed by Moerman *et al* and described three types of lesions that include constrictive tissue bands, amniotic adhesions and LBWC defects [15]. A prospective study using angiography was conducted in children born alive with

limb defects affected by amniotic bands. Gross vessel abnormalities were detected in the affected limb whereas its absence in the contralateral limb was striking, supporting vascular compromise as the primary event [16]. Despite this, not all spectrum of anomalies detected in ABS can be explained by VDT.

Familial cases of ABS are reported in the literature, where the ABS defects are inherited as autosomal dominant trait [17, 18]. Lock wood *et al* observed that the occurrence of ABS was significantly more common in monozygotic twins [19].

After all, we authors believe that the pathogenesis of ABS may not be explained by one single mechanism, and that a combination of more than one of the above-described theories may be possible.

## EPIDEMIOLOGY AND RISK FACTORS

The incidence of ABS may be as high as 1:56 in pre-viable fetuses, and can range from 1:1200 to 1:15,000 live births, with an equal expression in males and females [20]. The risk of ABS has been reported to be higher among the first-degree and second-degree relatives than general population indicating possibility of a genetic mechanism [21]. Amniocentesis induced injury also results in some typical lesions seen in ABS [22]. Other possible but inconclusive risk factors like firstborns, maternal drug usage (misoprostol), high altitude, ethnicity and vaginal bleeding during first trimester have been reported [21, 23, 24]. Centre for Disease Control and Prevention, Atlanta reported an increased risk of limb reduction defects in association with amniotic bands in presence of maternal smoking and aspirin use [25].

## CLINICAL SPECTRUM

Amniotic bands cause the varied clinical spectrum through malformation, deformation or disruption. Malformation is a defect in structure arising from an abnormality in the process of embryologic development eg. myelomeningocele. A deformation is a defect in a structure that embryo logically has developed normally as seen in constriction ring defects. Disruption, on the other hand occurs when a structure programmed to develop normally is damaged before it has had the chance to develop fully, like a swallowed fibrous string cuts through the mid facies producing disruption of the normal sequence. The resulting defects usually

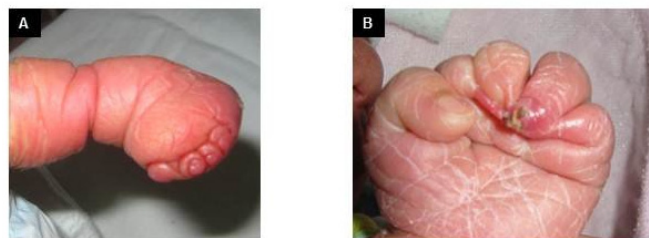
**Table 1: Groups of Structural and Associated Anomalies Based on the Time of Disruption of Embryonic Development**

Group	Time of Disruptive Event	Structural Anomalies
Group 1 disorder	3 to 6 weeks of gestation	Severe cranial malformations craniofacial clefts Limb body wall defects
Group 11 disorder	4 to 7 weeks of gestation	Facial clefts involving lip and palate. Congenital heart defects with associated internal anomalies. Limb reduction defects
Group 111 disorder	7 to 12 weeks of gestation	Oligohydramnios sequence which include renal agenesis, clubfoot.
Group IV disorder	9 weeks of gestation and above	Limb entanglement in the amnion resulting in constriction bands to limb amputation

depends on the above-mentioned events and stage of embryonic development [26].

Van Allen *et al* described four groups of structural and associated anomalies based on the time of disruption of embryonic development [27] (Table 1).

Limb defects observed in ABS include ring constrictions, amputation of digits or limbs, and syndactyly (Figure 1A and B). Constriction ring defects are the most common, affecting upper limbs more than the lower limbs. In a large study quoted by Moran *et al*, it was reported that hand involvement (55%) was more frequent than feet (24%) and the middle finger (28%) was affected more often than ring finger (27%) and index finger (23%)[28]. If constriction is severe enough to cause vascular and lymphatic obstruction it can cause edema of distal part requiring immediate intervention. Multiple anomalies can be found in more than 70% of cases [28-30]. Acrosyndactyly has been reported in ABS and is characterized by a constriction ring around adjacent digits, with distal soft tissue webbing and epithelial sinus tracts at the base of the proximal phalanx [30, 31]. Patterson classified the deformities of extremities [5] as shown in Table 2.



**Figure 1: A and B.** Ring constriction of the toes with amputation of big and little toes. Amniotic band causing circumferential banding above the ankle with lymphedema. Amputation of the distal phalanx of 2<sup>nd</sup> to 5<sup>th</sup> fingers with soft tissue webbing and partial fusion.

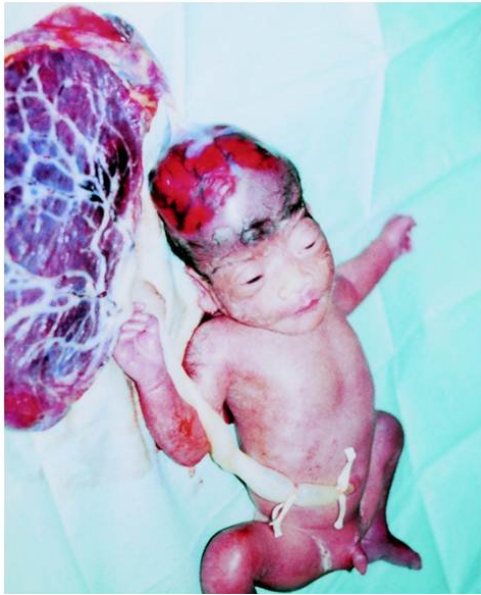**Table 2: Deformities of Extremities in ABS**

Type 1	Simple ring constriction
Type 2	Ring constriction accompanied by fusion of the distal bony parts, with or without lymphedema.
Type 3	Ring constriction accompanied by fusion of soft tissue parts.
Type 4	Demonstrates intrauterine amputations

Equino deformity of the foot is seen in approximately 25% cases of ABS. The deformity is typically rigid and in about 50% cases a tight band can be found around peroneal nerve, causing muscle imbalance and deformity, leading to gross limb length discrepancy [32]. Other less common digital anomalies reported with ABS are long bone hypoplasia, absent limbs, proximal syndactyly, preaxial polydactyly, camptodactyly, symbrachydactyly, arthrogryposis, and ectrodactyly [28].

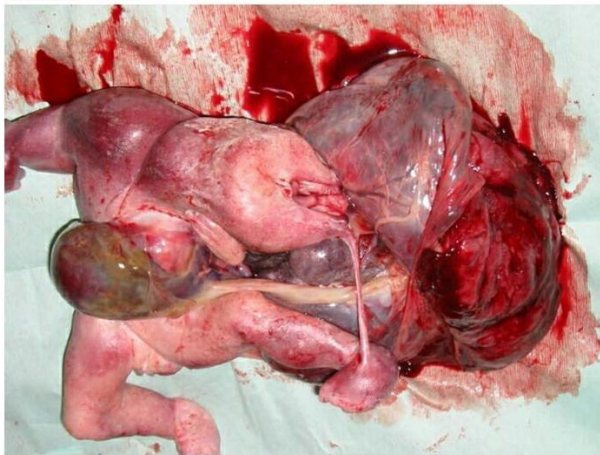
### Craniofacial Deformities

Are often multiple, multiform and asymmetric. The deformities usually include combination of facial clefts, cleft lip and palate associated with or without orbital lesions and other cranial anomalies. Tessier's widely accepted classification of cranial and facial defects, which are numbered 0-14, used orbit as the reference [33]. Other lesions described with ABS include asymmetric meningocele, myelomeningocele, exencephaly, acrania, and anencephaly [34, 35]. Chandran *et al*. has reported a case of acalvaria with ABS. Acalvaria is characterized by the absence of the dome-like superior portion of the cranium with complete cranial contents. In the reported case, amniotic membrane was fused to the scalp and folded up before entering the placenta. Neuropathological examination was unremarkable [10] (Figure 2).



**Figure 2:** Amniotic band with acalvaria. Amniotic membrane was fused to the scalp to protect the brain and folded up like a cradle cap. (Reproduced with permission from BMJ Publishing group Ltd [10]).

Chandran *et al* reported a case of disruptive amniotic band sequence due to swallowing of amniotic bands causing severe defects in the mid face and cranium exposing the brain. This fetus had omphalocele and a large band extending from the dorsum of the left foot to the left cheek before merging with the placenta [29] (Figure 3). Acephalia following spontaneous intrauterine decapitation was reported by Swinburne [36].



**Figure 3:** Disruptive ABS. Fetus swallowed the band, bisecting the nose and maxilla. No calvaria seen. Placenta was adherent to the duramater. Eyeballs were exposed and cloudy. A large band connecting the dorsum of left foot to left cheek and merged with the placental membrane. Gastroschisis noted. (Reproduced with permission from Ministry of Health, Brunei Darussalam [29]).

## Ocular Abnormalities

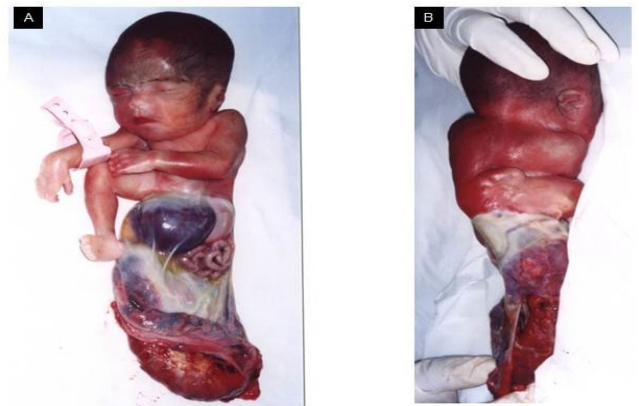
Are usually seen as part of craniofacial anomalies. The reported lesions seen in association with ABS are anophthalmus, microphthalmus, bony orbital cleft, lid coloboma, ptosis, lacrimal outflow obstruction and globe involvement in severe cases [37]. Bilateral epibulbar choriostoma, corneal leukoma and abnormal iris are rarely reported [38, 39].

## Visceral Manifestations

Of ABS are infrequent. Gastroschisis is the most common visceral defect seen in ABS. There is a high incidence of associated anomalies of internal organs, omphalocele, absent or dysplastic kidneys, bladder exstrophy, malrotation, atresia or shortened bowel, ambiguous genitalia, absent gonad, streak ovaries, vertebral hypoplasia and imperforate anus [40]. Abdominal constrictions due to amniotic bands [41], single umbilical artery and Sirenomelia sequence have been reported in ABS [42].

Stillbirths have been reported due to strangulation of umbilical cord by amniotic bands [43]. Egan JFX *et al* have observed an association of Pentalogy of Cantrell/ectopia cordis with amniotic bands [44].

Limb body wall complex is a rare fetal polymalformation syndrome defined by the presence of two out of three of the following features: 1) Exencephaly/encephalocele with facial clefts, 2) Thoraco-abdominoschisis/ventral body wall defects and



**Figure 4: A and B.** Limb body wall complex. Abdominal wall was absent with viscera exposed. Placenta was adherent to the peritoneum. Left lower limb was absent with a remnant of the left foot attached to the back of lower thorax. (Reproduced with permission from Ministry of Health, Brunei Darussalam [29]).

3) Limb defects [7]. Van Allen has reported that thoraco-abdominal (64%) defects were more often seen than isolated abdominal (32%) wall defects and left side (72%) being affected more often than right side (22%) in LBWC. Exencephaly was reported in 56% cases of LBWC where as meningomyelocele and hydrocephalus with aqueductal stenosis was less often noted. Associated midfacial clefts were seen in 40% cases. Limb defects (96%) and scoliosis (77%) were reported with higher frequency [34] (Figure 4 A and B).

## DIAGNOSIS

The diagnosis of ABS is based either on antenatal ultrasound (US) findings or postnatal physical examination. Demonstration of amniotic bands in prenatal US scan alone should not be the basis for diagnosis of ABS in the absence of fetal structural abnormalities.

ABS should be excluded when gross fetal anomalies are detected in US scan. Fisk *et al* made the first report of prenatal US diagnosis of amniotic bands of fetal limbs [45]. However 2D US have its own limitations in visualization of the continuity, extension and motion of amniotic bands [46]. Today 3D and 4-Dimensional (4D) US scan made it possible to see the spatial relationship of bands to the fetal parts. Fetal diagnosis of the first case of constriction band of the upper arm using 3D US was reported in 2004 by Paladini *et al*, highlighting the precision with which the diagnosis can be made and counsel the parents [47]. It has been shown that transvaginal 3D and 4D US has higher accuracy in diagnosing fetal hand and foot abnormalities in early 2<sup>nd</sup> trimester [48]. 4D US has given the parents an opportunity to look at near-photographic depiction of bands and associated fetal anomalies and make decision regarding continuation of pregnancy when faces with lethal malformations. Cranial bone defects can be diagnosed using US as early as 10-14 weeks of gestation [49]. Fetal diagnosis of LBWC can be made in late first trimester using US scan and Quijano *et al* reported a case diagnosed as early as 9 weeks of gestation [50].

Doppler studies are particularly useful when limb involvement is suspected, which helps to determine the adequacy of blood flow beyond the constriction. If flow is compromised, a band releasing surgery could be considered. In view of the danger of cord compression by amniotic bands, some authors advise routine

Doppler study of cord blood flow in suspected cases as the compression of cord by bands has potentially fatal outcome [51]. Neuman *et al* reported the first case series where fetal magnetic resonance imaging (MRI) was used as adjunct to US study and they opined that fetal MRI provided larger field of vision, high soft tissue contrast and better understanding of anatomy [52]. MRI also provides extent of damage to growing fetus when multiple malformations are noted [52, 53]. In 2<sup>nd</sup> trimester a marked elevation of maternal alpha-fetoprotein levels was noted in 100% cases of LBWC [54].

## MANAGEMENT

Management of ABS depends on the site, type, extent and severity of anomalies. As ABS has a highly varied spectrum of presentation both in fetal and neonatal period, knowledge of this entity will increase the frequency of suspicion and diagnosis. Even in the hands of experienced obstetrician/sonologist, ABS can be missed due to its non-classical presentation. Anomalies that is otherwise unexplainable in fetal scan warrant consideration of ABS in the differential diagnosis. Termination of pregnancy should be offered to antenatally diagnosed lethal ABS manifestations like acalvaria, LBWC defects etc.

Over the years the experience with the techniques of fetal surgery has grown. The indications for fetal interventions have been extended with increasing knowledge of the natural history of certain non-life-threatening conditions. This extended list of conditions needing fetal surgery included ABS when faced with a fetus in a life - threatening situation involving constriction of umbilical cord or amputation of a limb by amniotic bands. Earliest animal studies by Crombleholme *et al* demonstrated the functional recovery of banded extremities following band release [55]. Quintero *et al* performed the first fetoscopic lysis of bands in human fetuses using novel minimally invasive surgical techniques [56]. This procedure may help to save/restore limb function and morphology or even life saving when critical compression of umbilical cord is imminent. Javadian *et al* have reported an overall success of 50% in terms of preserving limb function following fetoscopic release of amniotic bands [57]. Preterm prelabor rupture of the membranes (78%) and preterm births (67%) has been reported in fetuses subjected to band release surgery [58].

Once ABS is suspected in the fetal scan, it is reasonable to follow up closely till Doppler studies are normal. As spontaneous resolution of amniotic bands has been reported, expectant management is advisable with a close surveillance of fetus[59]. Measurement of flow including the pulsatility index proximal and distal to the constriction band in comparison with flow in the contra lateral extremity should definitely be considered. Abnormal but presence of arterial Doppler flow to the distal limb and swelling has been suggested as the important specifications for fetuses that may benefit from a fetal surgical procedure [60].

Surgical interventions for congenital constriction rings (CCR), such as multiple Z or W-plasty, the Mutaf procedure and the replacement of Z-plasty with direct closure have been described with good success rates [61-63]. Recently described two-stage sine plasty combined with removal of the fibrous groove and fasciotomy for CCR has been reported to have favorable outcome [64]. The corrective procedures are completed before school age and are done either multi-staged or single stage as advocated by many surgeons [65, 66].

## CONCLUSION

ABS is a collection of asymmetric defects associated with fibrous amniotic bands. Defects seen in ABS vary from ring constrictions to severe lethal forms like craniorachischisis and LBWC. Index of suspicion for ABS during fetal imaging can facilitate early diagnosis after which close follow up with serial US scans is warranted. Fetal diagnosis using 3D/4D/MRI can confirm ABS with high accuracy, which can facilitate fetal interventions to save life or limb. Management of infants with ABS should aim at increasing function and optimal physical and neurological development in addition to aesthetic appearance. Current evidence does not support a genetic basis for ABS and most of the reported cases are of sporadic occurrences in otherwise normal families. This observation aids the counseling of parents of affected fetuses, with reassurance of the non-familial nature of anomalies seen in ABS. AS ABS is reported mostly as case reports, case series, clinical patterns of deformities and specific management aspects, this comprehensive review will add on to the body of literature covering historical perspective to management issues of amniotic bands.

## ACKNOWLEDGEMENTS

We sincerely thank Dr Kong Juin Yee, Associate Consultant, department of Neonatology, KK Women's and Children's Hospital, Singapore for her assistance with various aspects of the preparation of this manuscript. We thank Ms Siti Nurfadilah, department of Neonatology for her assistance in preparing the text, figures and tables.

## REFERENCE

- [1] Baker CJ, Rudolf AJ. Congenital ring constrictions and intrauterine amputations. *Am J Dis Child* 1971; 121: 393-400.
- [2] Montgomery W. Spontaneous Amputation in Utero. *Dublin J Med Sci* 1832; 2: 49.
- [3] Simpson J. Essays on diseases of the placenta. *Dublin J Med Sci* 1836; 10: 220.
- [4] Streeter G. Focal deficiencies in fetal tissues and their relation to intrauterine amputations. *Contributions Embryol Carnegie Inst* 1930; 22: 1-46.
- [5] Patterson TJ. Congenital ring-constrictions. *Br J Plast Surg* 1961; 14: 1-31.
- [6] Torpin R. Amniochorionic Mesoblastic Fibrous Strings and Amniotic Bands: Associate Constricting Fetal Malformations or Fetal Death. *Am J Obstet Gynecol* 1965; 91: 65-75.
- [7] Van Allen MI, Curry C, Walden CE, Gallagher L, Patten RM: Limb body wall complex.11. Limb and spine defects. *Am J Med Genet* 1987; 28: 549-65.
- [8] McKenzie J. Amniotic bands. *British Society for Developmental Biology, Symposium 2: The early development of mammals. Cambridge: University Press; 1975.*
- [9] Bamforth JS. Amniotic band sequence: Streeter's hypothesis re-examined. *Am J Med Genet* 1992; 44: 280-7.
- [10] Suresh Chandran, MengKeang Lim, Victor Yu-Hei Yu. Fetal acalvaria with amniotic band syndrome. *Arch Dis Child Fetal Neonatal Ed* 2000; 82: F11-F13.
- [11] Torpin R. Fetal malformations caused by amnion rupture during gestation. 1<sup>st</sup>ed. Charles C Thomas, Springfield, Ill; 1968. p 3-53.
- [12] Higginbottom MC, Jones KL, Hall BD, Smith DW. The Amniotic band disruption complex: Timing of amniotic rupture and variable spectra of consequent defects. *J Pediatr* 1979; 95: 544-9.
- [13] Kino Y. Clinical and experimental studies of the congenital constriction band syndrome, with an emphasis on its etiology. *J Bone Joint Surg Am* 1975; 57: 636-43.
- [14] Kennedy LA, Persaud TV. Pathogenesis of developmental defects induced in the rat by amniotic sac puncture. *Acta Anat (Basel)* 1977; 97: 23-35.
- [15] Moerman P, Fryns JP, Vandenberghe K, Lauweryns JM. Constrictive bands, amniotic adhesions, and limb body wall complex: discrete disruption sequences with pathogenic overlap. *Am J Med Genet* 1992; 42: 470-9.
- [16] Van Allen MI, Siegel-Bartelt J, Dixon J *et al.* Constriction bands and limb reduction defects in two newborns with fetal ultrasound evidence for vascular disruptions. *Am J Med Genet* 1992; 44: 598-604.
- [17] Etches PC, Stewart AR, Ives EJ. Familial congenital amputations. *J Pediatr* 1982; 101: 448-9.
- [18] Lubinsky M, Sujansky E, Sanger W, Salyards P, Severn C. Familial amniotic bands. *Am J Med Genet* 1983; 14: 81-7.

- [19] Lockwood C, Ghidini A, Romero R. Amniotic band syndrome in monozygotic twins: prenatal diagnosis and pathogenesis. *ObstetGynecol* 1988; 71: 1012-6.
- [20] Froster UG, Baird PA. Amniotic band sequence and limb defects: data from a population-based study. *Am J Med Genet* 1993; 46: 497-500.
- [21] Liascovich R, Castilla EE, Rittler M. Consanguinity in South America: Demographic aspects. *Hum Heredity* 2001; 51: 27-34.
- [22] Kennedy LA, Persaud TVN. Pathogenesis of developmental defects induced in the rat by amniotic sac puncture. *Acta Anatomica* 1977; 97: 23-35.
- [23] Torfs CP, Katz EA, Bateson TF, Lam PK, Curry CJR. Maternal medications and environmental exposures as risk factors for gastroschisis. *Teratology* 1996; 54: 84-92.
- [24] Lopez-Camelo JS, Orioli IM. Heterogeneous rates for birth defects in Latin America: hints on causality. *Genet Epidemiol* 1996; 13: 469-81.
- [25] Werler MM, Bosco JL, Shapira SK. Maternal vasoactive exposures, amnio bands, and terminal transverse limb defects. *Birth Defects Res A Clin Mol Teratol* 2009; 85: 52-7.
- [26] Higgin bottom MC, Jones KL, Hall BD, Smith DW. The Amniotic band disruption complex: Timing of amniotic rupture and variable spectra of consequent defects. *J Pediatr* 1979; 95: 544-9.
- [27] Morovic CG, Berwart F, Varas J: Craniofacial anomalies of the amniotic band syndrome in serial clinical cases. *Plast Reconstr Surg* 2004; 113: 1556-62.
- [28] Swinburne LM: Van Allen MI. Vascular disruptions. In: Gilbert-Barness E, Potter EL, eds. *Potter's Pathology of the Fetus and Infant*. 2<sup>nd</sup> ed. St. Louis, MO: Mosby; 1997.p 356-87.
- [29] Moran SL, Jensen M, Bravo C. Amniotic Band Syndrome of the upper extremity: Diagnosis and Management. *J Am Acad Orthop Surg* 2007; 15: 397-407.
- [30] Chandran S, Wickramasinghe HT. Disruptive bands and Limb-Body wall complex: Spectrum of Amniotic Band Syndrome. *BIMJ* 2005; 4: 98-101.
- [31] Kino Y: Clinical and experimental studies of the congenital constriction band syndrome, with an emphasis on its etiology. *J Bone Joint Surg Am* 1975; 57: 636-43.
- [32] Crombleholme TM, Dirkes K, Whitney TM, Alman B, Garmel S, Connelly RJ: Amniotic band syndrome in fetal lambs: I. Fetoscopic release and morphometric outcome. *J Pediatr Surg* 1995; 30: 974-8.
- [33] Gomez, VR. Clubfeet in congenital annular constricting bands. *Clin Orthop Rel Res* 1996; 323: 155-62.
- [34] Tessier P. Anatomical classification of facial, craniofacial, laterofacial clefts. *J Maxillofac Surg* 1976; 4: 69-92.
- [35] Van Allen MI, Curry C, Gallagher L. Limb body wall complex: I. Pathogenesis. *Am J Med Genet* 1987; 28: 529-48.
- [36] Spontaneous intrauterine decapitation. *Arch Dis Child* 1967; 42: 636-41
- [37] Miller MT, Deutsch TA, Cronin C, Keys CL: Amniotic bands as a cause of ocular anomalies. *Am J Ophthalmol* 1987; 104: 270-9
- [38] Chamney S, Willoughby CE, Mc Loone E. Amniotic band syndrome associated with an atypical iris and optic nerve defect. *J AAPOS* 2013; 17: 539-41.
- [39] Murata T, Hashimoto S, Ishibashi T, Inomata H, Sueishi K. A case of amniotic bandsyndrome with bilateral epibulbarchoristoma. *Br J Ophthalmol* 1992; 76: 685-7.
- [40] Martínez-Frías ML, Bermejo E, Rodríguez-Pinilla E. Body stalk defects, body wall defects, amniotic bands with and without body wall defects, and gastroschisis: comparative epidemiology. *Am J Med Genet* 2000; 92: 13-8.
- [41] Kim JB, Berry MG, Watson JS. Abdominal constriction band: A rare location for amniotic band syndrome. *J Plast Reconstr Aesthet Surg* 2007; 60: 1241-3.
- [42] Managoli S, Chaturvedi P, Vilhekar KY, Iyenger J. Mermaid syndrome with amnioticband disruption. *Indian J Pediatr* 2003; 70(1): 105-7.
- [43] Lurie S, Feinstein M, Mamet Y. Umbilical cord strangulation by an amniotic band resulting in a stillbirth. *J Obstet Gynaecol Res* 2008; 34(2): 255-7.
- [44] Egan JFX, Petrikowsky BM, Vintzileos AM, *et al*: Combined pentalogy of Cantrell and sirenomelia: A case report with Speculation about a common etiology. *Am J Perinatal* 1993; 10: 327-9.
- [45] Fiske CE, Filly RA, Golbus MS. Prenatal ultrasound diagnosis of amniotic band syndrome. *J Ultrasound Med* 1982; 1: 45-7.
- [46] Hill LM, Kislak S, Jones N. Prenatal ultrasound diagnosis of a forearm constriction band. *J Ultrasound Med* 1988; 7: 293-5.
- [47] Paladini D, Foglia S, Sglavo G, Martinelli P. Congenital constriction band of the upper arm: The role of three-dimensional ultrasound in diagnosis, counseling and multidisciplinary consultation. *Ultrasound Obstet Gynecol* 2004; 23: 520-2.
- [48] Hata T, Tanaka H, Noguchi J. 3D/4D sonographic evaluation of amniotic band syndrome in early pregnancy: A supplement to 2D ultrasound. *J Obstet Gynaecol Res* 2011; 37: 656-60.
- [49] Johnson SP, Sebire NJ, Snijders RJ, Tunkel S, Nicolaidis KH. Ultrasound screening for anencephaly at 10-14 weeks of gestation. *Ultrasound Obstet Gynecol* 1997; 9: 14-6. *Jog*
- [50] Quijano F E, Rey MM, Echeverry M, Fliedner RA. Body Stalk Anomaly in a 9-week Pregnancy. *Case Rep Obstet Gynecol* 2014; 2014: 357285.
- [51] Sifakis S, Mantas N, Konstantinidou A, Koukoura O, Avgoustinakis E, Koumantakis E: A stillborn fetus with amniotic band syndrome and elevated levels of alpha-fetoprotein plus beta-human chorionic gonadotropin: a case report. *Fetal Diagn Ther* 2008; 24: 111-4.
- [52] Neuman J, Calvo-Garcia MA, Kline-Fath BM *et al*. Prenatal diagnosis of amniotic band sequence: utility and role of fetal MRI as an adjunct to prenatal US. *Pediatr Radiol* 2012; 42: 544-51.
- [53] Lee SH, Lee MJ, Kim MJ, Son GH, Namgung R. Fetal MR imaging of constriction band involving skull and brain. *J Comput Assist Tomogr* 2011; 35: 685-7.
- [54] Morrow RJ, Whittle MJ, Mc Nay MB, Raine PA, Gobson AA, Crossley J. Prenatal diagnosis and management of anterior abdominal wall defects in the west of Scotland. *Prenat Diagn* 1993; 13: 111-5.
- [55] Crombleholme TM, Dirkes K, Whitney TM, Alman B, Garmel S, Connelly RJ. Amniotic band syndrome in fetal lambs. I: Fetoscopic release and morphometric outcome. *J Pediatr Surg* 1995; 30: 974-8.
- [56] Quintero RA, Morales WJ, Phillips J, Kalter CS, Angel JL. In utero lysis of amniotic bands. *Ultrasound Obstet Gynecol* 1997; 10: 316-20.
- [57] Javadian P, Shamshirsaz AA, Haeri S *et al*. Perinatal outcome after fetoscopic release of amniotic bands: a single-center experience and review of the literature. *Ultrasound Obstet Gynecol* 2013; 42: 449-55.
- [58] Richter J, Wergeland H, De Koninck P, De Catte L, Deprest JA. Fetoscopic release of an amniotic band with risk of amputation: case report and review of the literature. *Fetal Diagn Ther* 2012; 31: 134-7.
- [59] Pedersen TK, Thomsen SG. Spontaneous resolution of amniotic bands. *Ultrasound Obstet Gynecol* 2001; 18: 673-4.
- [60] Husler MR, Wilson RD, Horii SC, Bebbington MW, Adzick NS, Johnson MP. When is fetoscopic release of amniotic bands indicated? Review of outcome of cases treated in utero

- and selection criteria for fetal surgery *Prenat Diagn* 2009; 29: 457-63.
- [61] Mutaf M, Sunay M. A new technique for correction of congenital constriction rings. *Ann Plast Surg* 2006; 57: 646-52.
- [62] Takayuki M. Congenital constriction band syndrome. *J Hand Surg* 1984; 9: 82-8.
- [63] Stevenson TW. Release of circular constricting scars by Z flaps. *Plast Reconstr Surg* 1946; 1: 39-42.
- [64] Hung NN. Congenital constriction ring in children: sine plasty combined with removal of fibrous groove and fasciotomy. *J Child Orthop* 2012; 6: 189-97.
- [65] Hall EJ, Johnson-Giebink R, Vasconez LO. Management of the ring constriction syndrome: A Reappraisal. *Plast Reconstr Surg* 1982; 69: 532-6.
- [66] Greene WB. One stage release of congenital circumferential constriction bands. *J Bone Joint Surg Am* 1993; 75: 650-5.

---

Received on 11-02-2015

Accepted on 26-02-2015

Published on March-2015

<http://dx.doi.org/10.15379/2408-9761.2015.02.01.6>

© 2015 Chandran and Revanna; Licensee Cosmos Scholars Publishing House.

This is an open access article licensed under the terms of the Creative Commons Attribution Non-Commercial License (<http://creativecommons.org/licenses/by-nc/3.0/>), which permits unrestricted, non-commercial use, distribution and reproduction in any medium, provided the work is properly cited.