

First Trimester Screening

Alokananda Ray*

Department of Obstetrics and Gynaecology Tata Main Hospital Jamshedpur, India

Abstract: Screening for aneuploidies in the first and second trimester of pregnancy is an important aspect of prenatal testing. The overall prevalence of aneuploidy is around 1 in 228 (0.4%). First trimester screening has proved effective in identifying aneuploid fetuses, the definitive diagnostic test for aneuploidy available in first trimester is chorion villous sampling (CVS).

Keywords: First trimester, Screening, Aneuploidy.

INTRODUCTION

In the last few decades, the fetus has been considered as an individual with extensive efforts in investigation and treatment of the unborn. Advances in technology and skills in the field of Fetal Medicine has enabled us to visualise and manipulate the fetus for various prenatal diagnostic procedures and invasive fetal therapies.

Screening for aneuploidies in the first and second trimester is an important aspect of prenatal testing. The overall prevalence of aneuploidy is around 1 in 228 (0.4%) - which includes live births, miscarriages and intra uterine fetal demise (IUD). The three most common trisomies- Trisomy 21, 18 and 13 constitute 71% of all aneuploidies. Trisomy 21 or Down's syndrome is the commonest (53%). First trimester screening has proved effective in identifying aneuploid fetuses, the definitive diagnostic test for aneuploidy available in first trimester is chorion villous sampling (CVS).

THIS ARTICLE AIMS TO

- 1) Discuss the current methods of prenatal screening in the first trimester,
- 2) Review the ultrasound, biochemical markers and newer methods- like non-invasive prenatal testing (NIPT), used in prenatal screening and
- 3) Application of the information gained through these tests to our clinical practice.

GUIDELINES FOR PRENATAL SCREENING

The first method of screening for aneuploidies was based on the association of advanced maternal age

and the increased incidence of trisomy 21. This method of screening was introduced in the early 1970s, with the traditional recommendation of amniocentesis to all women above 35 years of age. In the 1970s about 5% of the pregnant population belonged to this group. However with advancing maternal age in most developed countries, this population has now increased to around 15 to 20%.

In 2007, ACOG (American College of Obstetricians and Gynaecologists) opined that invasive testing like amniocentesis should be advised based on multiple screening test results and that advanced maternal age alone should not be the indication for invasive testing. They also suggested that screening should be offered to all pregnant women who attend the antenatal clinic prior to 20 weeks in order to determine the patient specific risk for chromosomal defects [1].

Every woman has a risk of her fetus or baby having a chromosomal defect. The back ground or *a priori* risk depends on the maternal age and gestational age of the fetus. The patient specific risk is then calculated by multiplying this *a priori* risk with a series of likelihood ratios depending on the screen test results. Everytime a test is performed, the *a priori* risk is multiplied by the likelihood ratio of the test to calculate a new risk which then becomes the *new* risk for the next test. [2] Likelihood ratio is calculated as- percentage of chromosomally abnormal fetus/ % of normal fetus with a given test result or measurement.

IMPORTANCE OF MATERNAL AGE AND PERIOD OF GESTATION

The prevalence of trisomy 13, 18 and 21 increase with maternal age. However since these trisomies are associated with a high risk of miscarriage and intrauterine fetal demise, its prevalence decreases with increase in the period of gestation [3, 4]. e.g. the risk of

*Address correspondence to this author at the Department of Obstetrics and Gynaecology Tata Main Hospital Jamshedpur, India;
E-mail: alokanandaray@yahoo.com

T21 in a woman aged 40 years, decreases from 1 in 51 at first trimester to 1 in 113 at term. This is because the rate of spontaneous loss of T21 fetuses between 12 to 40 weeks is about 30%. [5, 6] Similarly for T13 and T18 the rate of miscarriage or fetal demise between 12 to 40 weeks is about 80%. The prevalence of Turner's syndrome (45, XO) is about 1 in 1500 at 12 weeks decreases to 1 in 3000 at 20 weeks and 1 in 4000 at term. Turner's syndrome is usually related to loss of paternal X chromosome and is thus unrelated to increased maternal age. For the sex chromosome aneuploidies- (47,XXY, 47,XYY and 47,XXX) there is no significant change with maternal age, and since the rate of fetal loss does not increase as the pregnancy progresses, its prevalence of 1 in 500 does not change with increase in the gestational age. Polyploidy is extremely lethal, reported in about 2% of recognised pregnancy, rarely seen as live birth, the prevalence at 12 weeks and 20 weeks is about 1 in 2000 and 1 in 2,50,000 respectively [7].

PREVIOUS HISTORY OF AFFECTED PREGNANCY

Maternal history of trisomy in a previous pregnancy increases the risk in the current pregnancy, for that trisomy by 0.75% higher than her a priori risk [8]. Thus for a woman of 35 years, who has had a previous baby with T21, the risk at 12 weeks increases from 1 in 249 (0.4%) to 1 in 87 *i.e.* (1.15%). Likewise for a woman aged 25 years, the risk for T21 increases from 1 in 946 (0.106%) to 1 in 117 (0.856%). This increase in risk occurs because a small proportion of couples with a previous affected pregnancy suffer from parental mosaicism or abnormal dysjunction, the risk of recurrence in this group is high. However in a majority of couples (about 95%) the risk is not increased.

PRENATAL SCREENING COMPONENTS IN THE FIRST TRIMESTER INCLUDE

- First trimester ultrasound
- First trimester biochemical markers
- Non Invasive Prenatal Testing (NIPT)

The advantages of screening early in pregnancy are many. It gives information about the pregnancy at an earlier date and definitive diagnostic test can be performed by chorion villous sampling (CVS), should there be a need for invasive diagnostic testing. Ultrasound can pick up most anomalies in the first

trimester, it is also a good time to date the pregnancy and determine the chorionicity for twin gestations. Most pregnant women would prefer to know about the status of their pregnancy early rather than wait till the second trimester. [9] And finally termination based on diagnostic tests would be a lot safer at this point of time than later in pregnancy.

NUCHAL TRANSLUCENCY

In 1992, Nicolaides and co-workers described the sonographic appearance of fluid beneath the skin, at the back of the fetal neck, seen in all foetuses in the first trimester. They called this the nuchal translucency (NT) and reported an increased incidence of aneuploidies, specially trisomies in foetuses having an increased NT thickness [10, 11]. It is now well documented that an increased NT is associated with increased risk of aneuploidies and birth defects. The concept of measuring the NT in all foetuses in the first trimester forms the basis of first trimester screening by ultrasound.

The Fetal Medicine Foundation has very strict criteria for measuring the nuchal translucency [11-15].

- The gestational age of the fetus should be 11 to 13+6 weeks with a CRL between 45-84 mm
- It should be a good mid- sagittal view with the fetus in neutral position
- The magnification should be such that only the fetal head and thorax should be in the image
- The maximum thickness of the subcutaneous translucency should be measured. Fetal skin should be distinguished from the amnion.
- The cross bar of the calipers measuring the NT should merge with the white line of the border of the subcutaneous translucency

More than one measurement must be taken and the largest recorded. In 5-10% of cases the umbilical cord may be around the neck, in such a situation the NT should be measured above and below the cord and an average of the two readings should be taken.

The NT increases with the increase in the crown rump length (CRL) and gestational age. The median NT increases from 1.2mm at a CRL of 45mm to 1.9mm at a CRL of 84mm, likewise the 95th centile increases

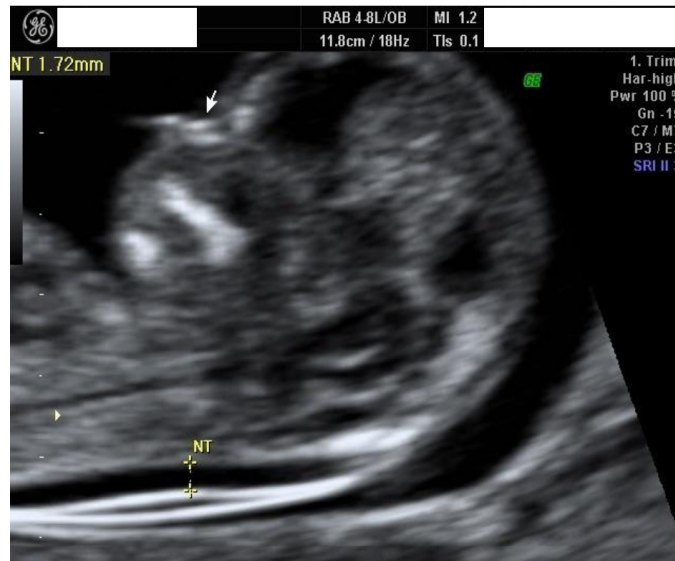

Figure 1: Measurement of NT. Nasal bone depicted by an arrow.

from 2.1mm to 2.7mm from a CRL of 45mm to 84mm [16]. A positive NT scan is defined as a NT measurement which is more than the 95th centile for a given CRL. The larger the NT measurement, the higher the likelihood ratio and therefore greater the new risk, in contrast the smaller the NT, lower the new risk for chromosomal abnormality. The thickness of the NT is important in estimating the risk and not its appearance e.g. whether it is septated or not, restricted to the fetal neck or enveloping the entire fetus [17]. Increased NT usually resolves after 14 weeks, however in some cases it can further evolve to nuchal oedema, cystic hygroma or fetal hydrops. The median NT for normal foetuses is 2mm, and significantly higher for aneuploidies 3.5mm for T21, 5.5mm for T18, 4mm for T13 and 9.2mm for 45XO.

Apart from chromosomal abnormalities a large number of other defects can result in an increased NT thickness such as- cardiac defects, genetic anaemias - thalasemia, congenital erythropoetic porphyria, fanconi's syndrome, venous congestion in head and neck, obstruction of lymphatic drainage, altered composition of extracellular matrix, fetal hypoproteinemia and fetal infections like parvo virus B19. About 20% of foetuses with increased NT thickness are aneuploid. The rest 80% have no chromosomal abnormality, of them 2.5% die in utero, 10% have major structural defects and 87.5% are normal. This suggests that NT is a marker and if the karyotype is normal and no other structural abnormality is detected, the long term outcome of foetuses with

increased NT is not adverse [18-23].

MATERNAL SERUM BIOCHEMICAL MARKERS AND FIRST TRIMESTER SCREENING FOR ANEUPLOIDIES

In the last 25 years several biochemical markers have been evaluated for screening purposes, the two most important and useful markers in the first trimester are- free beta HCG and pregnancy associated plasma protein A (PAPP- A). Maternal free beta HCG normally decreases beyond 10 weeks and PAPP-A increases till term. Levels of these two markers vary in aneuploid foetuses. Each type of aneuploidy has its own biochemical profile. (24-28)

In T21, free β HCG tends to be higher and PAPP-A lower than euploid foetuses. In T13 and T18- both the markers are substantially lower, in sex chromosome aneuploidies PAPP-A alone tends to be lower. In triploidy levels depend on the origin of the additional set of chromosome- The diandric type of triploidy is associated with very high levels of serum free β hCG and mildly decreased levels of PAPP-A. In digynic triploidy, both free β hCG and PAPP-A are significantly decreased [29-34].

Maternal weight, race, smoking and method of conception can affect the levels of these biochemical markers, also different laboratory assays yield different results. Therefore all these factors should be taken into account for risk analysis in any algorithm for prenatal screening.

The first trimester combined screening, includes - maternal age, maternal history, gestational age, NT measurement, and maternal serum levels of free β hCG and PAPP-A. For a false positive rate of 5% the detection rate for combined first trimester screening test is as high as 90% for all trisomies (Trisomy 21, 18 and 13) and for monosomy X [35, 36]. Structural anomalies usually seen in aneuploid fetuses can also be detected in first trimester ultrasonography.

OTHER ULTRASOUND MARKERS USED IN SCREENING FOR ANEUPLOIDY

Nasal Bone (NB)

With the turn of the century in 2001 it was recognised that nasal bone is absent in 60-70% of fetuses with trisomy 21. The image of the nose has three distinct lines (Figure 1). The top line represents the nasal skin, the bottom one which is thicker and more echogenic than the overlying skin represents the nasal bone. The third line almost in continuity with the skin, but slightly at a higher level represents the tip of the nose. A normal nasal bone is more or as echogenic as the overlying skin. The nasal bone is absent in 60-70% of T21 and 1-2.5% of euploid fetuses. Absence of NB in normal fetus is maximum in individuals of African ethnicity (10%). NB is absent in 30% and 50% of fetuses with T13 and T18 respectively [37-40].

Ductus Venosus

The ductus venosus is a unique shunt in the fetus which directs almost 50% of the well oxygenated blood from the hepatic portion of the umbilical vein to the inferior vena cava. Abnormal flow in the ductus venosus in the first trimester is associated with chromosomal defects, cardiac anomalies and poor perinatal outcome. The blood flow in the ductus has a typical waveform. There is a high velocity flow during ventricular systole (S wave) and ventricular diastole (D wave) and a rapid drop in the forward flow during atrial contraction (a wave). However throughout the cardiac cycle it is a forward flow in the ductus venosus wave form in a normal fetus. Reversed ductus venosus a wave is seen more commonly in fetuses with aneuploid than euploid foetus. (T21- 60%, T13 and T18- 53-58%, Monosomy- 75% as compared to 3% of normal fetuses) (Figure 2). The possible explanation for reversal of a wave could be- right ventricular dilatation with increased filling pressure and ultrastructural abnormalities in the heart resulting in ventricular wall stiffening. In these situations the right atrium would require a more forceful contraction to

push the blood forward into the right ventricle across the tricuspid valve. This increase in atrial pressure gets transmitted to the ductus venosus, resulting in reversal of a waves [41-43].

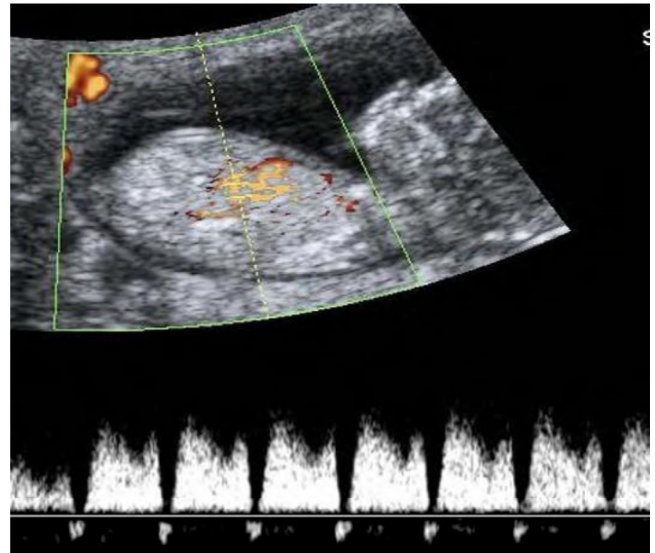


Figure 2: Reversal of 'a' wave in ductus venosus.

Tricuspid Regurgitation (TR)

Tricuspid regurgitation is another important ultrasound marker in the first trimester and is more commonly seen in the aneuploid than in euploid fetuses (55% in T21, 33% in T18, 30% in T13, 38% in monosomy compared to 1% in normal fetuses) [44]. In aneuploid fetuses abnormalities are present in ultrastructural and biochemical levels, resulting in TR even in the absence of gross structural abnormality in the heart. e.g. in Trisomy 21 right ventricular dilatation result in an enlargement of the tricuspid valve annulus, which in turn results in TR [45].

The normal flow across the tricuspid valve during diastole is bi phasic - the first is due to increase in the forward flow in the beginning of the ventricular diastole and the second increase is due to atrial contraction. Any flow across the tricuspid valve during systole represents tricuspid regurgitation (TR) and is abnormal (Figure 3). The tricuspid regurgitant flow should last for at least 30% of the systole with the peak velocity of the regurgitant flow > 60 cm/sec.

Frontomaxillary Facial Angle (FMF angle)

A classical abnormal feature of trisomy 21 is a flat face and this can be objectively measured by measuring the FMF angle. Studies have demonstrated

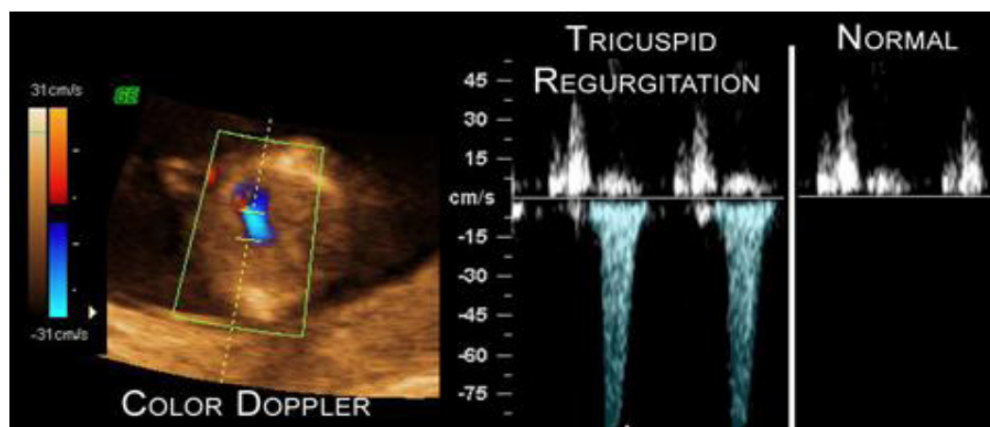


Figure 3: Tricuspid regurgitation.

that this angle decreases from 83.5° at a crown rump length (CRL) of 45mm to 76.4° at a CRL of 84mm [46]. FMF angle > 95th centile for a given CRL is seen in almost 70% of foetuses with trisomy 21.

Inclusion of the newer ultrasound markers in the screening protocols can improve the detection rate to 95% for a false positive rate of 2.5% for T21 and 0.1% for T13 and T18 [43, 44, 47].

Thus there are several markers for screening a fetus in the first trimester, one approach could be to use all of them as the primary method of screening. However this might not always be practical as it requires high level of training, time and skill to perform all the ultrasound markers. Thus the Fetal Medicine Foundation has proposed an algorithm on how best to use the markers. The primary approach should begin with the first trimester combined screen test, which includes- maternal age and history, period of gestation, NT thickness, serum free β hCG and PAPP-A. Based on the test results, the population is divided into three groups,-high risk (risk > 1 in 50 for trisomy 21) intermediate risk (risk 1 in 51 to 1 in 1000) and low risk- (risk < 1 in 1000). The high risk comprises of 1.5% of the population screened and has 85% of T21 fetuses. This group should be subjected to invasive prenatal diagnostic testing like CVS or the non-invasive prenatal testing (NIPT) to rule out aneuploidies. The intermediate risk group comprises of 15% of the population with 14% of T21, this group should be offered a second look ultrasound with the newer USG markers (Nasal Bone, Tricuspid valve, Ductus venosus and frontomaxillary facial angle). If the risk for trisomy is 1 in 100 or more after inclusion of the newer USG markers, NIPT or CVS should be offered. The rest are managed as in the low risk group. 83.5% of the screened population belong to the low risk group with

about 1% of T21 foetuses. This group should be offered a routine mid trimester anomaly scan at 20 weeks.

First Trimester Screening in Multifetal Pregnancy

First trimester screening in twin gestation includes maternal biochemical markers and USG, with similar detection and false positive rates as in singleton pregnancy [48, 49]. However the biochemistry in multiple pregnancy, does not perform as effectively, therefore USG is a very important marker for multiple pregnancy. It helps in determining the number of foetuses, chorionicity and any other structural abnormality in the fetus.

The chorionicity is determined by the thickness of the amniotic membrane at the point it connects with the placenta- thicker Lambda sign for di-chorionic twins and thinner T sign for mono chorionic twins. In mono chorionic twins the risk is calculated based on the average of the NT measurement of both twins. In dichorionic twins, the risk is assigned to each fetus depending on the NT measurement of that fetus. Discordance in NT thickness in mono chorionic twins can be a predictor of early twin transfusion syndrome (TTTS) [50, 51]. Normal values of biochemical markers in di-chorionic twins is higher than mono chorionic twins.

EFFICIENCY OF FIRST TRIMESTER SCREENING IN HIGHER ORDER MULTIPLE PREGNANCY IS LESS WELL UNDERSTOOD

Fetal structural Abnormalities in First Trimester

Most major structural abnormalities can now be detected by ultrasonography after 11 weeks of gestation. Several structural abnormalities are known

to be associated with aneuploidies- eg holoprosencephaly (risk 1:2 for T13), diaphragmatic hernia (risk 1:4 for T18), AVSD (risk 1:2 for T 21), omphalocele (risk 1:4 for T18, and 1:10 for T13) etc [52, 53]. All pregnancies detected with major structural abnormalities in the fetus should be subjected to invasive prenatal diagnostic testing- CVS, to rule out aneuploidy.

Non Invasive Prenatal Testing (NIPT)

NIPT utilizes cell free fetal DNA in maternal plasma as a screening tool for fetal aneuploidy. The genetic material is derived from dead placental tissue. About 10% of cell free DNA in maternal circulation is of fetal origin – it has a short half life of about 20 minutes and disappears from the maternal circulation completely two hours post partum. This test can be performed anytime after 10 weeks.

Quantitative differences in chromosome fragments in maternal blood is utilised to differentiate aneuploid fetuses (mainly trisomy 21,18,13 and some other aneuploidies like monosomy and sex chromosome aneuploidies) from normal fetuses. [54-59] Elevated levels of fetal genetic material for a particular chromosome, indicates trisomy of that chromosome. Test report can also interpret two sex chromosomes, with or without detection of Y chromosome.

NIPT is not a diagnostic test; it can only screen for the common trisomies and has a high sensitivity and specificity- 98-99% and a false positive of < 1% for Trisomy 21 and 18. NIPT is indicated as a primary screen test in women who are at a high risk for aneuploidy and in those who have a positive first trimester combined screen test. However it can give no other genetic information about the pregnancy, or any other aspect of fetal wellbeing.

The American College of Obstetricians and Gynaecologists (ACOG) and Society of Maternal and Fetal Medicine put forward a committee opinion in 2012 on NIPT as follows [60].

NIPT is indicated in women with high risk for aneuploidy (advanced maternal age, prior affected pregnancy, positive first trimester screen test, parent carriers of Robertsonian translocation involving chromosome 13 and 21).

It should not be a routine prenatal test and should not be offered to low risk and multifetal pregnancies.

If fetal structural abnormality is detected in ultrasound, invasive diagnostic tests (CVS or amniocentesis) should be offered.

A positive test should be referred for genetic counselling and offered CVS or amniocentesis for confirmation of test results.

NIPT DOES NOT REPLACE THE DIAGNOSTIC ACCURACY OF CVS OR AMNIOCENTESIS

Conclusion and Key points

- Every woman has a risk that her fetus or baby has a chromosomal defect, hence screening should be offered to all pregnant women prior to 20 weeks of gestation.
- The back ground or a priori risk depends on the maternal age and period of gestation.
- The basic first trimester combined screen test to calculate the risk include- maternal age, maternal history, gestational age, NT thickness, maternal serum levels of free β hCG and PAPP-A.
- Additional ultrasound markers- nasal bone, TR, Ductus venosus flow and FMF angle can further improve the detection rates and is presently used for re-evaluating the risk in the population with intermediate risk.
- Several structural abnormalities which are commonly associated with aneuploidies can be detected in the first trimester scan.
- NIPT is an additional screening test available now for the common trisomies (T 21, 18 and 13) and is indicated in women who at a high risk for aneuploidy.
- A positive combined screen test should be offered either NIPT or invasive diagnostic tests like chorion villous sampling (CVS) or amniocentesis.
- NIPT is not a diagnostic test--a negative test result in NIPT does not completely rule out aneuploidy and a positive test result has to be confirmed by an invasive definitive diagnostic test- CVS or amniocentesis.

The future of first trimester screening will largely depend upon where NIPT will figure in the algorithm for

first trimester screening. Will it accompany or replace the biochemical markers or NT screening? Will it also be advised to the low risk population and multifetal pregnancies? Presently ACOG does not recommend NIPT to these two groups as further research is required to sufficiently evaluate the use of NIPT in these groups. And finally whether NIPT as a technology will evolve further to enable detection of a larger number of aneuploidies, chromosomal mosaicism, microdeletions and duplications.

All the standardised views and algorithm for screening mentioned in this article were developed by the Fetal Medicine Foundation, and can be accessed in their website- <http://www.fetalmedicine.com/training/certification/11-13+6weekscan>.

REFERENCES

- [1] American College of Obstetricians and Gynecologists. ACOG Practice Bulletin No. 88, December 2007. Invasive prenatal testing for aneuploidy. *Obstet Gynecol.* 2007; 110(6): 1459-67. PubMed PMID: 18055749
- [2] Snijders RJM, Nicolaides KH. Assessment of risks. In *Ultrasound Markers for Fetal Chromosomal Defects*. Carnforth, UK: Parthenon Publishing, 1996: 109-13
- [3] Snijders RJM, Holzgreve W, Cuckle H, Nicolaides KH. Maternal age-specific risks for trisomies at 9-14 weeks' gestation. *Prenat Diagn* 1994; 14: 543-52
- [4] Snijders RJM, Sebire NJ, Cuckle H, Nicolaides KH. Maternal age and gestational age-specific risks for chromosomal defects. *Fetal Diag Ther* 1995; 10: 356-67
- [5] Halliday JL, Watson LF, Lumley J, Danks DM, Sheffield LJ. New estimates of Down syndrome risks at chorionic villus sampling, amniocentesis, and livebirth in women of advanced maternal age from a uniquely defined population. *Prenat Diagn* 1995; 15: 455-65
- [6] Morris JK, Wald NJ, Watt HC. Fetal loss in Down syndrome pregnancies. *Prenat Diagn* 1999; 19: 142-5
- [7] Snijders RJM, Sebire NJ, Cuckle H, Nicolaides KH. Maternal age and gestational age-specific risks for chromosomal defects. *Fetal Diag Ther* 1995; 10: 356-67
- [8] Snijders RJM, Sundberg K, Holzgreve W, Henry G, Nicolaides KH. Maternal age and gestation-specific risk for trisomy 21. *Ultrasound Obstet Gynecol* 1999; 13: 167-70.
- [9] Mulvey S, Wallace EM. Women's knowledge of and attitudes to first and second trimester screening for Down's syndrome. *BJOG* 2000; 107: 1302-5.
- [10] Nicolaides KH, Azar G, Byrne D, Mansur C, Marks K. Fetal nuchal translucency: ultrasound screening for chromosomal defects in first trimester of pregnancy. *BMJ* 1992; 304: 867-9.
- [11] Nicolaides KH, Brizot ML, Snijders RJM. Fetal nuchal translucency: ultrasound screening for fetal trisomy in the first trimester of pregnancy. *BJOG* 1994; 101: 782-6.
- [12] Whitlow BJ, Economides DL. The optimal gestational age to examine fetal anatomy and measure nuchal translucency in the first trimester. *Ultrasound Obstet Gynecol* 1998; 11: 258-61
- [13] Braithwaite JM, Morris RW, Economides DL. Nuchal translucency measurements: frequency distribution and changes with gestation in a general population. *Br J Obstet Gynaecol* 1996; 103: 1201-4
- [14] Whitlow BJ, Chatzipapas IK, Economides DL. The effect of fetal neck position on nuchal translucency measurement. *Br J Obstet Gynaecol* 1998; 105: 872-6
- [15] Schaefer M, Laurichesse-Delmas H, Ville Y. The effect of nuchal cord on nuchal translucency measurement at 10-14 weeks. *Ultrasound Obstet Gynecol* 1998; 11: 271-3
- [16] Snijders RJM, Noble P, Sebire N, Souka A, Nicolaides KH. UK multicentre project on assessment of risk of trisomy 21 by maternal age and fetal nuchal translucency thickness at 10-14 weeks of gestation. *Lancet* 1998; 351: 343-6.
- [17] Moline F, Avgidou K, Kagan KO et al. Cystic hygroma, nuchal edema and nuchal translucency at 11-14 weeks of gestation. *Ostet Gynecol* 2006 ; 107; 678-83
- [18] Brady AF, Pandya PP, Yuksel B, Greenough A, Patton MA, Nicolaides KH. Outcome of chromosomally normal livebirths with increased fetal nuchal translucency at 10-14 weeks' gestation. *J Med Genet* 1998; 35: 222-4.
- [19] Hyett J, Perdu M, Sharland G, Snijders R, Nicolaides KH. Using fetal nuchal translucency to screen for major congenital cardiac defects at 10-14 weeks of gestation: population based cohort study. *BMJ* 1999; 318: 81-5.
- [20] Makrydimas G, Sotiriadis A, Ioannidis JP. Screening performance of first-trimester nuchal translucency for major cardiac defects: a meta-analysis. *Am J Obstet Gynecol* 2003; 189: 1330-5.
- [21] Michailidis GD, Economides DL. Nuchal translucency measurement and pregnancy outcome in karyotypically normal fetuses. *Ultrasound Obstet Gynecol* 2001; 17: 102-5.
- [22] Souka AP, von Kaisenberg CS, Hyett JA, Sonek JD, Nicolaides KH. Increased nuchal translucency with normal karyotype. *Am J Obstet Gynecol* 2004;
- [23] Souka AP, Krampfl E, Bakalis S, Heath V, Nicolaides KH. Outcome of pregnancy in chromosomally normal fetuses with increased nuchal translucency in the first trimester *Ultrasound Obstet Gynecol* 2001; 18: 9-17.
- [24] Ozturk M, Milunsky A, Brambati B, Sachs ES, Miller SL, Wands JR. Abnormal maternal levels of hCG subunits in trisomy 18. *Am J Med Genet* 1990; 36: 480-3
- [25] Spencer K, Macri JN, Aitken DA, Connor JM. Free beta hCG as a first trimester marker for fetal trisomy. *Lancet* 1992; 339: 1480
- [26] Isles RK, Sharma K, Wathen NC, et al. hCG, free subunit and PAPP-A composition in normal and Down's syndrome pregnancies. In *Fourth conference: Endocrinology and Metabolism in Human Reproduction*. London: RCOG, 1993
- [27] Brambati B, Tului L, Bonacchi I, Shrimanker K, Suzuki Y, Grudzinskas JG. Serum PAPP-A and free beta hCG are first-trimester screening markers for Down syndrome. *Prenat Diagn* 1994; 14: 1043-7
- [28] Krantz DA, Larsen JW, Buchanan PD, Macri JN. First trimester Down syndrome screening: free human chorionic gonadotropin and pregnancy associated plasma protein A. *Am J Obstet Gynecol* 1996; 174: 612-16
- [29] Kagan KO, Wright D, Syngelaki K et al, First trimester screening for trisomy 21 by free beta- human chorionic gonadotropin and pregnancy associated plasma protein -A, impact of maternal and pregnancy characteristics. *Ultrasound Obstet Gynecol* 2008; 31: 493-502.
- [30] Tul N, Spencer K, Noble P et al, Screening for trisomy 18 by fetal nuchal translucency and maternal serum free beta hCG and PAPP-A at 10-14 weeks of gestation. *Prenat Diagn* 1999;19: 1035-42
- [31] Spencer K, Ong C, Skentou H et al, Screening for trisomy 13 by fetal nuchal translucency and maternal serum free beta hCG and PAPP-A at 10-14 weeks of gestation. *Prenat Diagn* 2000;20: 411-6
- [32] Spencer K, Tul N, Nicolaides KH, Maternal serum free beta hCG and PAPP-A in fetal sex chromosome defects in the first trimester. *Prenat Diagn* 2000; 20: 390-4

- [33] Spencer K, Liao A, Skentou H *et al*, Screening for triploidy by fetal nuchal translucency and maternal serum free beta hCG and PAPP-A at 10-14 weeks of gestation. *Prenat Diagn* 2000;20: 495-9
- [34] Kagan KO, Anderson JM, Anwandter G, *et al*. Screening for triploidy by the risk algorithm for trisomies 21,18 and 13 at 11 weeks to 13 weeks and 6 days of gestation. *Prenat Diagn* 2008; 28: 1209-13.
- [35] Spencer K, Souter V, Tul N, Snijders R, Nicolaides KH. A screening program for trisomy 21 at 10-14 weeks using fetal nuchal translucency, maternal serum free b-human chorionic gonadotropin and pregnancy-associated plasma protein-A. *Ultrasound Obstet Gynecol* 1999; 13: 231-7.
- [36] Spencer K, Spencer CE, Power M, Dawson C, Nicolaides KH. Screening for chromosomal abnormalities in the first trimester using ultrasound and maternal serum biochemistry in a one stop clinic: A review of three years prospective experience. *BJOG* 2003; 110: 281-6.
- [37] Cicero S, Curcio P, Papageorgiou A, Sonek J, Nicolaides KH. Absence of nasal bone in fetuses with trisomy 21 at 11-14 weeks of gestation: an observational study. *Lancet* 2001; 358: 1665-7.
- [38] Cicero S, Rembouskos G, Vandecruys H, Hogg M, Nicolaides KH. Likelihood ratio for trisomy 21 in fetuses with absent nasal bone at the 11-14 weeks scan. *Ultrasound Obstet Gynecol* 2004; 23: 218-23.
- [39] Nicolaides KH. Nuchal translucency and other first-trimester sonographic markers of chromosomal abnormalities. *Am J Obstet Gynecol* 2004; 191: 45-67.
- [40] Viora E, Masturzo B, Errante G *et al*, Ultrasound evaluation of fetal nasal bone at 11-14 weeks in a consecutive series of 1906 fetuses. *Prenat Diagn* 2003; 23: 784-7
- [41] Borrell A, Martinez JM, Seres A, Borobio V, Cararach V, Fortuny A. Ductus venosus assessment at the time of nuchal translucency measurement in the detection of fetal aneuploidy. *Prenat Diagn* 2003; 23: 921-6.
- [42] Matias A, Gomes C, Flack N, Montenegro N, Nicolaides KH. Screening for chromosomal abnormalities at 11-14 weeks: the role of ductus venosus blood flow. *Ultrasound Obstet Gynecol* 1998; 2: 380-4.
- [43] Maiz N, Valencia C, Kagan KO *et al* Ductus venosus Doppler in screening for trisomies 21,18 and 13 and Turner syndrome at 11-13 weeks of gestation *Ultrasound Obstet Gynecol* 2009; 33: 512-7
- [44] Kagan KO, Valencia C, Livanos P *et al*, Tricuspid regurgitation in screening for trisomies 21,18 and 13 and Turner syndrome at 11-13+6 weeks of geatation *Ultrasound Obstet Gynecol* 2009; 33: 18-22
- [45] Sonek JD, Nicolaides KH, Additional first trimester ultrasound markers *Clin Lab Med* 2010;30: 573-92
- [46] Borenstein M, Persico N, Kagan KO, Gazzoni A, Nicolaides KH. Frontomaxillary facial angle in screening for trisomy 21 at 11 to 13 + 6 weeks. *Ultrasound Obstet Gynecol* 2008; 32; (1): 5-11
- [47] Kagan KO, Cicero S, Staboulidou I *et al*, Fetal nasal bone in screening for trisomies 21,18 and 13 and Turner syndrome at 11-13+6 weeks of geatation *Ultrasound Obstet Gynecol* 2009; 33: 259-64
- [48] Sebire NJ, Snijders RJM, Hughes K, Sepulveda W, Nicolaides KH. Screening for trisomy 21 in twin pregnancies by maternal age and fetal nuchal translucency thickness at 10-14 weeks of gestation. *BJOG* 1996a; 103: 999-1003.
- [49] Spencer K, Nicolaides KH. Screening for trisomy 21 in twins using first trimester ultrasound and maternal serum biochemistry in a one-stop clinic: a review of three years experience. *BJOG* 2003; 110: 276-80.
- [50] Matias A, Montenegro N, Areias JC. Anticipating twin-twin transfusion syndrome in monochorionic twin pregnancy. Is there a role for nuchal translucency and ductus venosus blood flow evaluation at 11-14 weeks? *Twin Res* 2000; 3: 65-70.
- [51] Sebire NJ, Souka A, Skentou H, Geerts L, Nicolaides KH. Early prediction of severe twin-to-twin transfusion syndrome. *Hum Reprod* 2000; 15: 2008-10.
- [52] Snijders RJM, Brizot ML, Faria M, Nicolaides KH. Fetal exomphalos at 11-14 weeks of gestation. *J Ultrasound Med* 1995; 14: 569-74.
- [53] Snijders RJM, Farrias M, von Kaisenberg C, Nicolaides KH. Fetal abnormalities in ultrasound markers for fetal chromosomal defects. Snijders RJM, Nicolaides KH Editors, Camforth, UK, Parthenon Publishing; 1996; 1-62.
- [54] Ashoor G, Syngelaki A, Wagner M, *et al*. Chromosome-selective sequencing of maternal plasma cell-free DNA for first-trimester detection of trisomy 21 and trisomy 18. *Am J Obstet Gynecol*. 2012; 206(4): 322. PubMed PMID: 22464073.
- [55] Chiu RW, Akolekar R, Zheng YW, *et al*. Non-invasive prenatal assessment of trisomy 21 by multiplexed maternal plasma DNA sequencing: large scale validity study. *BMJ*. 2011; 11; 342: c7401. doi: 10.1136/bmj.c7401. PubMed PMID: 21224326; PubMed Central PMCID: PMC3019239.
- [56] Chiu RW, Chan KC, Gao Y, *et al*. Noninvasive prenatal diagnosis of fetal chromosomal aneuploidy by massively parallel genomic sequencing of DNA in maternal plasma. *Proc Natl Acad Sci U S A*. 2008 Dec 23; 105(51): 20458-63. Epub 2008 Dec 10. PubMed PMID: 19073917; PubMed Central PMCID: PMC2600580
- [57] Sehnert AJ, Rhee B, Comstock D, *et al*. Optimal detection of fetal chromosomal abnormalities by massively parallel DNA sequencing of cell-free fetal DNA from maternal blood. *Clin Chem*. 2011 Jul; 57(7): 1042-9. Epub 2011 Apr 25. PubMed PMID: 21519036.
- [58] Sparks AB, Wang ET, Struble CA, *et al*. Selective analysis of cell-free DNA in maternal blood for evaluation of fetal trisomy. *Prenat Diagn*. 2012 Jan; 32(1): 3-9. doi: 10.1002/pd.2922. Epub 2012 Jan 6. PubMed PMID: 22223233
- [59] Zimmermann B, Hill M, Gemelos G, *et al*. Noninvasive prenatal aneuploidy testing of chromosomes 13, 18, 21, X, and Y, using targeted sequencing of polymorphic loci. *Prenat Diagn* 2012 Oct 32: 1-9 doi: 10.1002/pd.3993 PubMed PMID: 23108718
- [60] American College of Obstetricians and Gynecologists and Society for Maternal-Fetal Medicine. Committee Opinion No. 545, December 2012. Noninvasive prenatal testing for fetal aneuploidy. *Obstet Gynecol* 2012; 120: 1532-4.