

Role of Hysteroscopy in Infertility – A Retrospective Study

Neema Acharya* and Amruta Gadge

DATTA Meghe Institute of Medical Sciences, India

Abstract: *Aim:* The aim of this study is to assess the results of hysteroscopy done in cases of infertility.

Objective: To determine the incidences of abnormal findings of hysteroscopy in evaluation of infertility.

Material and Methods: This retrospective observational study was carried out at department of Gynaecology AVBRH, sawangi, over a period of six months from October 2016 to March 2017. After detailed clinical evaluation, all patients of infertility and subinfertility, irrespective of their obstetric history, coming to AVBRH, sawangi were informed regarding the procedure and written informed consent was taken. Hysteroscopy was performed in operation theatre by using KARL STORZZ hysteroscope. It is a rigid continuous flow panoramic hysteroscope 25 cm in length, 5 mm diameter of an outer sheath and 30° fiberoptic lens. All procedures were done under general anaesthesia. Distension of uterine cavity was achieved with normal saline by pressure bag or Endomat. Endocervical canal followed by whole uterine cavity with all four walls and bilateral ostias were visualised. Endometrial biopsy was taken for histopathological examination under direct vision if required. If any pathology like intrauterine adhesions, polyp, myoma or septa was diagnosed, operative procedure was done at the same sitting.

Data was collected from the medical records department of the hospital. Statistical analysis was done by using descriptive and inferential statistics using z-test for single proportion and software used in the analysis were SPSS 17.0 version and EPI-INFO 6.0 version and $z > 1.96$ considered as significant.

Results: Hysteroscopy was performed in 85 infertile women, out of which 61 (71.76%) presented with primary infertility and 24 (28.24%) women were with secondary infertility. Analysis was performed against primary and secondary infertility.

Keywords: Hysteroscopy, Infertility, Submucous fibroid, Endometrial polyp.

INTRODUCTION

Infertility is “a disease of the reproductive system defined by the failure to achieve a clinical pregnancy after 12 months or more of regular unprotected sexual intercourse” [1] (WHO-ICMART glossary). Approximately 15 % of couples are affected by infertility, which is defined as the inability to conceive after 12 months of regular unprotected sexual intercourse [2].

Infertility related to uterine cavity abnormalities has been estimated to be the cause in 10% to 15% of couples seeking treatment. Also abnormal uterine findings have been found in 34% to 62% of women with infertility [3]. Such pathologies of uterus cause structural and functional impairment of endometrium, making it unfit for the implantation. Uterine abnormalities perhaps impair the proper embryo implantation and growth due to poor vascularization [3].

The modalities used to assess the uterine cavity are Transvaginal ultrasonography (TVS), Hysterosalpin-gography (HSG), Saline infusion sonography (SIS) and Hysteroscopy. Transvaginal ultrasonography (TVS) is

the simplest imaging examination which is non-invasive, cost effective and has high clinical significance. It helps in evaluation of size, shape, volume and contour of the uterine cavity and determination of any intrauterine pathology. The overall sensitivity and specificity for TVS in the diagnosis of intra-uterine abnormality is 79% and 82% respectively [4]. HSG can also be helpful in evaluating uterine cavity abnormalities. It is considered to have a high sensitivity (60–98 %) but low specificity (15-80 %) in detecting uterine abnormalities, and hysteroscopy remains the method of choice for the final assessment [2].

SIS is a minimally invasive, cost-effective and acceptable diagnostic modality. It gives an excellent anatomic detail of the uterus and has been shown to be highly accurate in the diagnosis of polyp, endometrial hyperplasia, and various uterine anomalies. The sensitivity of SIS in the detection of intrauterine abnormalities in infertility was 88% with specificity of 94% [5].

However, WHO recommends office hysteroscopy in females who are suspected of intrauterine abnormality on clinical basis or complementary exams (ultrasound, HSG) or after *in vitro* fertilization (IVF) failure. Direct view of the uterine cavity offers a significant advantage over other blind or indirect diagnostic methods, also it's a therapeutic procedure so even when no abnormality

*Address correspondence to this author at the DATTA Meghe Institute of Medical Sciences, India;
Tel: 9326692511; 9420854365;
E-mail: neemadk@hotmail.com

is found with these tools, hysteroscopy should be considered. Thus, this study is being done to assess the results of hysteroscopy done in cases of infertility.

Table 1: Distribution of Patients According to their Type of Infertility

Type of Infertility	No of Patients	Percentage (%)	z-Value
Primary	61	71.76	14.69,S
Secondary	24	28.24	5.78,S
Total	85	100.00	

If $z > 1.96$, Result is Significant.

Among 85 women with infertility, 61(71.76%) were nulliparous and 24 were multiparous (28.24%). Among 24 women with secondary infertility, 3 (12.5%) women had parity 2, 14 (58.33%) were primiparous, 7 (29.16%) women had history of one abortion, 6 (25%) had two abortions while only 1 (4.16%) woman had history of three abortions.

Table 2: Distribution of Patients According to their Obstetrical Formula (Pre- Procedure)

Obstetrical Formula (Pre- Procedure)	No of Patients	Percentage (%)	z-Value
Nulliparous	61	71.76	14.69,S
Multiparous	24	28.24	5.78,S
Total	85	100.00	

If $z > 1.96$, Result is Significant

Among 85 women with an age range of 20-45 years, 61.17% women were of age < 30 years while 38.82% women were of age \geq 30 years. The mean age was 29.21 ± 5.40 years in both primary and secondary infertility.

Table 3: Showing Distribution of Patients According to Age

Age Group (yrs)	No of Patients	Percentage (%)
20-29 yrs	52	61.18
30-39 yrs	29	34.12
40-49 yrs	4	4.71
Total	85	100.00
Mean \pm SD	29.21 \pm 5.40(20-45 years)	

Table 4 shows distribution of women undergoing hysteroscopy in primary and secondary infertility group. Normal intrauterine findings were found in 41 women.

Majority of these women were of age less than 30 years (73.17%) and presented with primary infertility (78.04%). Abnormal Hysteroscopic findings were found in 44 women, of whom maximum women were with primary infertility (65.90%) and of age \geq 30 years (37.93%).

Table 4: Distribution of Patients According to their Hysteroscopic Findings

Hysteroscopic Findings	No of Patients	Percentage (%)	z-Value
Intrauterine Adhesions	11	12.94	3.55,S
Normal	41	48.24	8.90,S
Polyp	17	20.00	4.61,S
Septum	11	12.94	3.55,S
Submucous Fibroid	3	3.53	1.76,NS
Unicornuate Uterus	2	2.35	1.43,NS
Total	85	100	

If $z > 1.96$, Result is Significant.
S-Significant, NS-Not Significant.

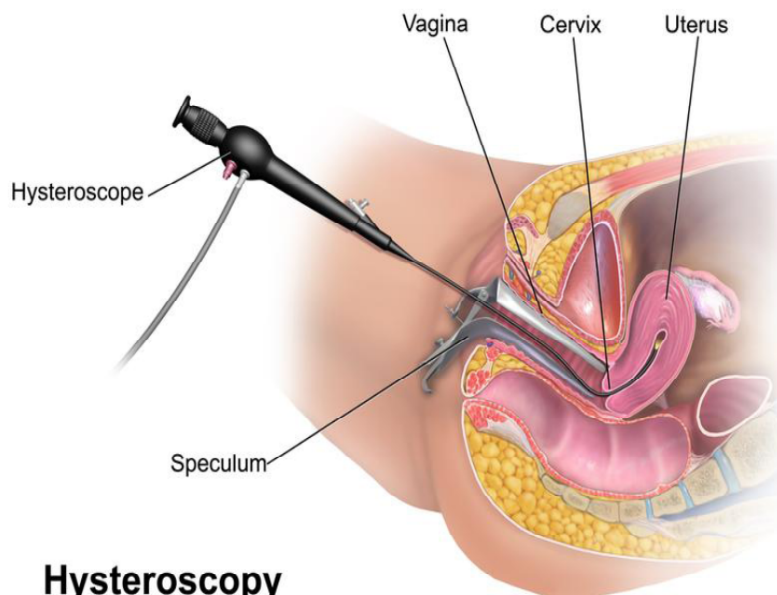
In primary infertility group, intrauterine pathologies were diagnosed in (52.45%) women. The most common finding was endometrial polyp (41.37%) followed by intrauterine adhesions (24.13%), septum (24.13%), unicornuate uterus (6.89%) and sub mucous myoma (3.44%). In group with secondary infertility, abnormal intrauterine pathologies were detected in 15 women (62.5%). The most common intrauterine pathology was endometrial polyp, seen in 33.33% women.

DISCUSSION

In Table 1, among 85 women with infertility, 61(71.76%) were nulliparous and 24 were multiparous (28.24%). Table 2 shows among 24 women with secondary infertility. Unfortunately, pre-hysteroscopic ultrasound or HSG finding results were not available in all our patients.

In the present study out of 85 hysteroscopy performed, 61 were performed for evaluation of women with primary infertility, while 24 women had secondary infertility.

Endometrial polyp was diagnosed in 17 (38.63%) cases out of 44 cases of abnormal intrauterine pathology, of which no statistically significant difference was seen between primary and secondary infertility group. Shokeir TA *et al.* [7] did a study to determine



Hysteroscopy

incidence of endometrial polyps on hysteroscopy in an infertile eumenorrheic population. Out of 244 women who underwent hysteroscopy, endometrial polyp was found in 36 (13.53%) patients. Hence this study concluded that Diagnostic hysteroscopy should be used routinely in the work-up of infertile woman and persistent functional endometrial polyps, even if small, are likely to impair fertility so removal of such lesions should be done to improve subsequent reproductive performance.

Septate uterus is one of the common developmental intrauterine anomalies. In our study, it was seen in 11 cases (25%). The pooled data suggest that the prevalence of septate uterus is similar in infertile and fertile women (approximately 1%) [8]. It is associated with various complications such as first trimester pregnancy loss, second trimester abortion and preterm delivery. Pregnancy outcomes dramatically improved after surgical correction. Therefore, hysteroscopy helps in not only diagnosing the septa but also its simultaneous resection [8].

Uterine myoma was found in 3 (6.81%) women in the current study. Myoma might adversely affect fertility include dysfunctional uterine bleeding interfering with ovum or sperm transport or embryo implantation, cornualmyoma compressing the interstitial segment of the tube and poor regional blood flow resulting in focal endometrial attenuation or ulceration [9]. Donnez and Jadoul tried to address the issue of whether myomas influence fertility, by reviewing 106 relevant articles [10]. They concluded that they do influence fertility, mainly based on the favorable pregnancy rates

obtained after Myomectomy. Furthermore, they concluded that submucous and intramural myomas distort the cavity, impairing implantation and pregnancy rates in women undergoing IVF. Hence, Hysteroscopy not only diagnose these pathologies, but also enables Myomectomy at same siting [10].

Limitation of the study is that as it is a retrospective data study, pregnancy rate after procedure could not have been followed up.

CONCLUSION

This study suggests that the hysteroscopy was able to identify intrauterine pathologies in 51.76% of women with infertility so it may also be included as a routine investigation in future in evaluation of female infertility.

Correction of any uterine abnormalities even if small or minor, improves chance of conception in infertile women having no other cause of infertility. Hence we suggest that hysteroscopy should be included as a routine investigation in evaluation of female infertility.

REFERENCES

- [1] WHO-ICMART revised glossary.
- [2] Pundir J, El Toukhy T. Uterine cavity assessment prior to IVF. *Womens Health (Lond Engl)* 2010; 6(6): 841-848. <https://doi.org/10.2217/WHE.10.61>
- [3] Brown SE, Coddington CC, Schnorr J, Toner JP, Gibbons W, et al. Evaluation of outpatient hysteroscopy, saline infusion hysterosonography and hysterosalpingography in infertile women: a prospective, randomized study. *Fertil Steril* 2000; 74(5): 1029-1034. [https://doi.org/10.1016/S0015-0282\(00\)01541-7](https://doi.org/10.1016/S0015-0282(00)01541-7)

- [4] Maryam N, Hadieh H, Ahmadi F, Fatemeh N, Mohammad C. Diagnostic Accuracy of Transvaginal Sonography in the Detection of Uterine Abnormalities in Infertile Women. *Iran J Radiol* 2012; 9(3): 139-144. <https://doi.org/10.5812/iranjradiol.8063>
- [5] Seshadri S, El-Toukhy T, Douiri A, Jayaprakasan K, Khalaf Y. Diagnostic accuracy of saline infusion sonography in the evaluation of uterine cavity abnormalities prior to assisted reproductive techniques: a systematic review and meta-analyses. *Hum Reprod Update* 2015; 21(2): 262-274. <https://doi.org/10.1093/humupd/dmu057>
- [6] Practice committee of American Society for Reproductive Medicine. Diagnostic evaluation of the infertile female: a committee opinion. Birmingham, AL: American Society for Reproductive Medicine. *Fertil Steril* 2015; 103(6): e44-e50. <https://doi.org/10.1016/j.fertnstert.2015.03.019>
- [7] Shokeir TA, Shalan H, El-Shafei. Significance of endometrial polyps detected hysteroscopically in eumenorrheic infertile women. *J Obstet Gynaecol Res* 2004; 30(2): 84-89. <https://doi.org/10.1111/j.1447-0756.2003.00163.x>
- [8] Homer HA, Li TC, Cooke ID. The septate uterus: A review of management and reproductive outcome. *Fertil Steril* 2000; 73(1): 1-14. [https://doi.org/10.1016/S0015-0282\(99\)00480-X](https://doi.org/10.1016/S0015-0282(99)00480-X)
- [9] Vollenhoven BJ, Lawrence AS, Healy DL. Uterine fibroids: A clinical review. *Br J Obstet Gynaecol* 1990; 97(4): 285-298. <https://doi.org/10.1111/j.1471-0528.1990.tb01804.x>
- [10] Donnez J, Jadoul P. What are the implications of myomas on fertility? A need for a debate? *Hum Reprod* 2002; 17: 1424-30. <https://doi.org/10.1093/humrep/17.6.1424>

Received on 02-05-2017

Accepted on 31-08-2017

Published on 20-11-2017

<http://dx.doi.org/10.15379/2408-9761.2017.04.03.01>

© 2017 Acharya and Gadge; Licensee Cosmos Scholars Publishing House.

This is an open access article licensed under the terms of the Creative Commons Attribution Non-Commercial License

[\(http://creativecommons.org/licenses/by-nc/3.0/\)](http://creativecommons.org/licenses/by-nc/3.0/), which permits unrestricted, non-commercial use, distribution and reproduction in any medium, provided the work is properly cited.