

First Diagnosed Heart Failure Due to Churg-Strauss Syndrome. A Case Report

Konstantinos M. Lampropoulos*, Athanasios I. Triantafyllou, Aikaterini I. Megalou, Ioannis E. Kapelakis, Epameinondas A. Triantafyllou and Antonios S. Manolis

Cardiology Department Evaggelismos General Hospital Athens Greece

Abstract: Churg Strauss Syndrome (CSS) is an autoimmune condition that causes inflammation of small and medium-sized blood vessels. It is a non-infectious systemic vasculitis, which affects mainly the lungs but also other tissues and organs. CSS is considered a highly variable condition in terms of its presentation and its course. The most serious complication of the vasculitic stage is congestive heart failure with reduced ejection fraction. We present a case with first diagnosed heart failure because of CSS and review of the literature.

Keywords: Churg-Strauss syndrome, Allergic granulomatosis, Heart failure, Non-infectious systemic vasculitis.

CASE PRESENTATION

A 50-year-old female was admitted to the emergency department of our hospital with symptoms of dyspnoea on exertion, retrosternal burning pain, numbness of upper and lower limbs and inability to walk. The patient presents with worsening dyspnoea on exertion the last ten days and retrosternal pain within 24 hours.

She has been hospitalized to pulmonary clinic twenty days ago and left with a diagnosis of postinfectious bronchial asthma for which has been treated with corticosteroids and antibiotics. Three weeks later she presented numbness of lower limbs, muscular weakness, burning pain in ankle joints and Purpura type rash in the legs. Medical history was positive for arterial hypertension on treatment (carvedilol, valsartan and hydrochlorothiazide), smoking and presence of thyroid nodules. Family history of asthma and brother with sudden cardiac death are also referred.

The physical examination revealed blood pressure:135/85 mmHg, respiratory rate: 16 / min, temperature: 36.7 °C, pulse: 111 / min, S1, S2 distinct and rhythmic, systolic murmur heard over tricuspid and mitral valve area, distended jugular veins, mild oedema and numbness of lower limbs, diffuse rhonchi bilateral with reduction in the bases, liver painless and slightly palpable, spleen impalpable, reduction in muscle strength of lowering limbs, left foot drop, maculopapular rash on the lower limbs in resolution. Physical examination of other systems was normal.

The admission ECG showed sinus tachycardia (111 / min), poor deployment of R in V1-V3 leads, negative T waves in II, III, aVf, V3-V6 leads, PR: 160 msec, QRS: 80 msec, QTc: 420 msec (Figure 1).

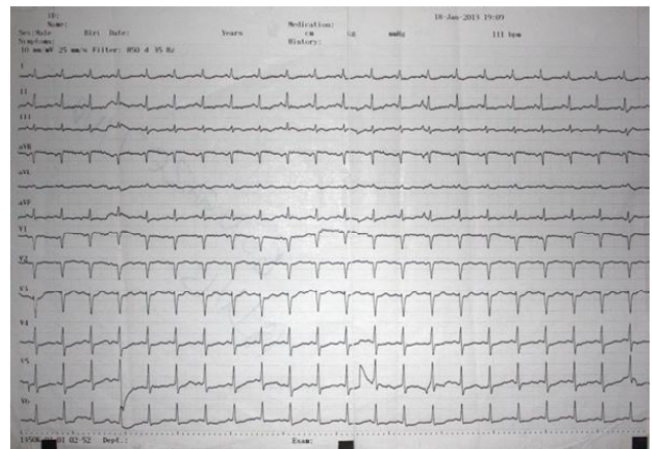


Figure 1:

The chest x-ray showed bilateral distension of pulmonary portals (Figure 2).

Laboratory tests showed elevated troponin (2457 ng/mL) and elevated level of eosinophil count in the peripheral blood (WBC: 14.72/ μ L, NEU/LYM: 36,8/12,6, EOS 48%, RBC: 3,94/MI, HCT: 36, Hb: 12,4 g/dL, MCV: 91,6 fL, PLTs: 316/ μ L).

Echocardiography revealed left ventricle with End Diastolic Diameter 56 mm and normal wall thickness but systolic dysfunction (Ejection Fraction 35%) with hypokinesia of anterior interventricular diaphragm - anterior and lateral wall. There was also mild to moderate mitral and tricuspid regurgitation (PASP 40mmHg) and mild pericardial effusion (maximum 14mm next to right atrium) (Figures 3, 4).

*Address correspondence to this author at the Department of Cardiology, Evaggelismos General Hospital of Athens, Greece. 43, Alopekis str. 10676, Athens, Greece; Tel: +302107294808; Fax: +302107294808; E-mail: konlampropoulos@yahoo.gr

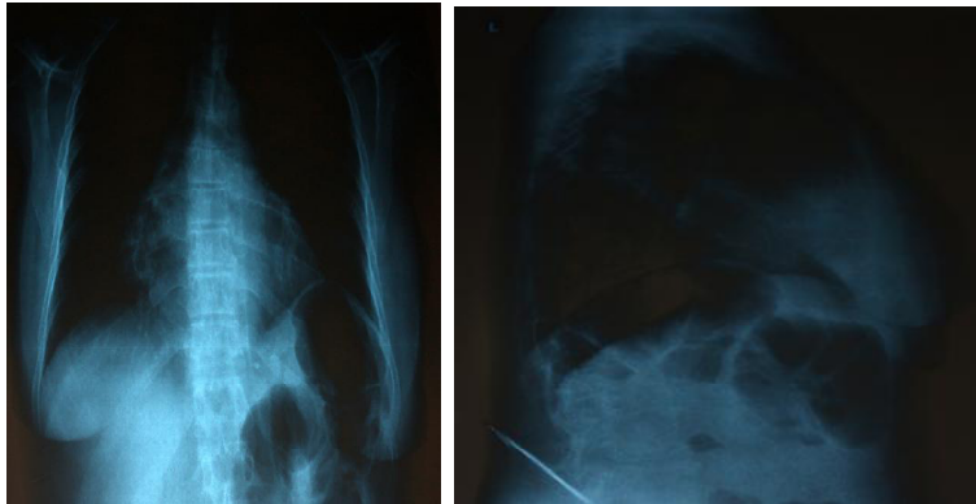


Figure 2:

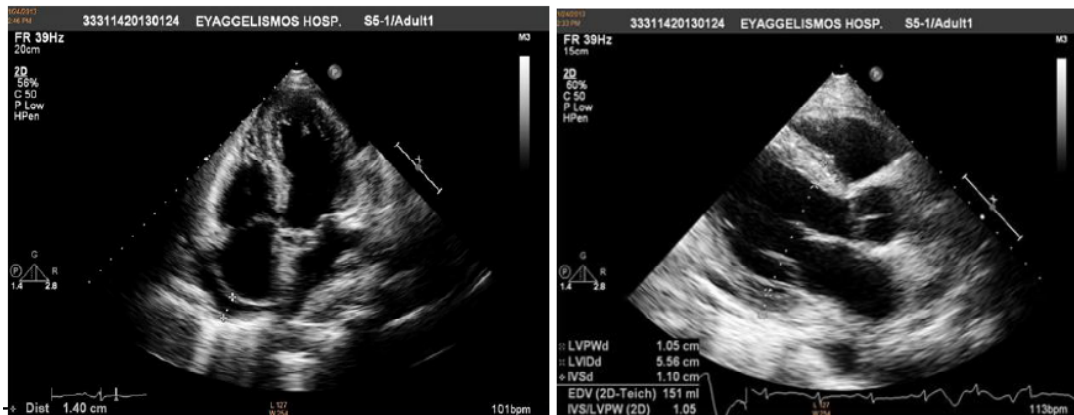


Figure 3:

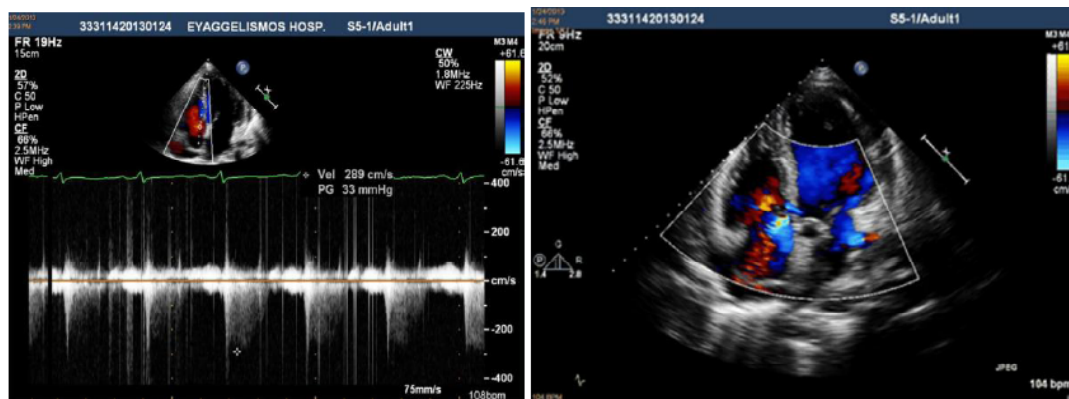


Figure 4:

The patient initially hospitalized in Cardiology clinic due to elevated cardiac enzyme (troponin: 2457 ng/mL) where treated with the recommended medical treatment such as b-blocker, angiotensin II receptor blocker, furosemide, aspirin, spironolactone and statin. There was not conducted urgent coronary angiography because of the presence of fever, and the HCG alterations had no change. The angiographic study

which was performed later did not show any stenosis of the coronary arteries.

The patient was transferred to the Internal Medicine clinic in order to be further searched for his anemia, eosinophilia, neuropathy and asthma. Serological markers of HBV, HCV, HIV, Aspergillus, Echinococcus infection and stool culture were negative. Thyroid

function tests were normal (T3:102, FT4:1.3, TSH :0.1, Anti TPO:18.8, Anti Tg:13.8). Electrophoresis of serum proteins showed mild decrease of albumin and higher levels of alpha globulins (Albumin: 45.9, Alpha1: 10.3, Alpha2:15.4, Beta:11.1, Gamma:17.3). From tumor markers only Cancer Antigen 125 was elevated (CEA: 1.07, AFP: 1.49, CA 15-3:8.2, CA-125: 64.6, CA19-9:13.13). From the rest immunological control higher level of Immunoglobulin E and Rheumatoid Factor arised (IgG: 1150, IgA: 82.2, IgM:84.8, IgE:514, Rheumatoid Factor:22, C3:158,C4:48.4). Plasma autoantibodies (Abs) were negative except from perinuclear anti-neutrophil antibodies (p-ANCA, titres 1:160).

Moreover, we proceeded to detection of fusion gene BCR / ABL in peripheral blood [1] and dedection of FIP1L1-PDGFRa fusion gene [2] in bone marrow smear which are associated with Chronic Myelogenous Leukemia (CML) and Hypereosinophilic Syndrome (HES), respectively.

Bone marrow biopsy was negative and skin-muscle biopsy was not diagnostic.

The Electromyography highlighted sensorimotor neuropathy predominant in lower limbs. Body Computed Tomography revealed hemangioma in thoracic vertebra and fibrous elements in the anterior base of the right and the left lung.

Because of the presence of p-ANCA antibodies, peripheral neuropathy and eosinophilia, the patient considered that he was suffering from Churg Strauss Syndrome (CSS) and treated with prezolon 75 mg and medrol 32 mg per day. The treatment for heart failure

which was mentioned above continued plus inhaled corticosteroids due to symptoms and findings from the respiratory. After regression of eosinophilia and dyspnea she was transferred to the Rheumatology Clinic where she underwent biopsy of left leg nerve and nasal mucosal. Both biopsies were negative. In a new echocardiography study after treatment we found improvement of left ventricle systolic function with mild hypokinesia of anterior apical interventricular septum. The Ejection Fraction was calculated at 50% with Simpson's method. Pericardial fluid was absent (Figure 5).

The patient exited on medical treatment with methylprednisolone 16 mg, calcium, alendronate 70 mg, atorvastatin 40 mg, metoprolol 100 mg, valsartan 40 mg, aspirin 100 mg and omeprazole 20 mg.

DISCUSSION

In our case differential diagnosis should be performed between Churg Strauss Syndrome (CSS), Wegener's granulomatosis, Idiopathic Hypereosinophilia Syndrome, Loeffler Syndrome, Kounis Syndrome, Eosinophilic Leukemia, Takotsubo cardiomyopathy and Ischemic Heart Disease.

CSS [3-5] (also known as eosinophilic granulomatosis with polyangiitis or allergic granulomatosis) is an autoimmune condition that causes inflammation of small and medium-sized blood vessels (vasculitis) in persons with a history of airway allergic hypersensitivity (atopy). It is a non-infectious systemic vasculitis, which affects mainly the lungs but also other tissues and organs. It constitutes 2% of all vasculitis. In asthmatic patients, the frequency of CSS

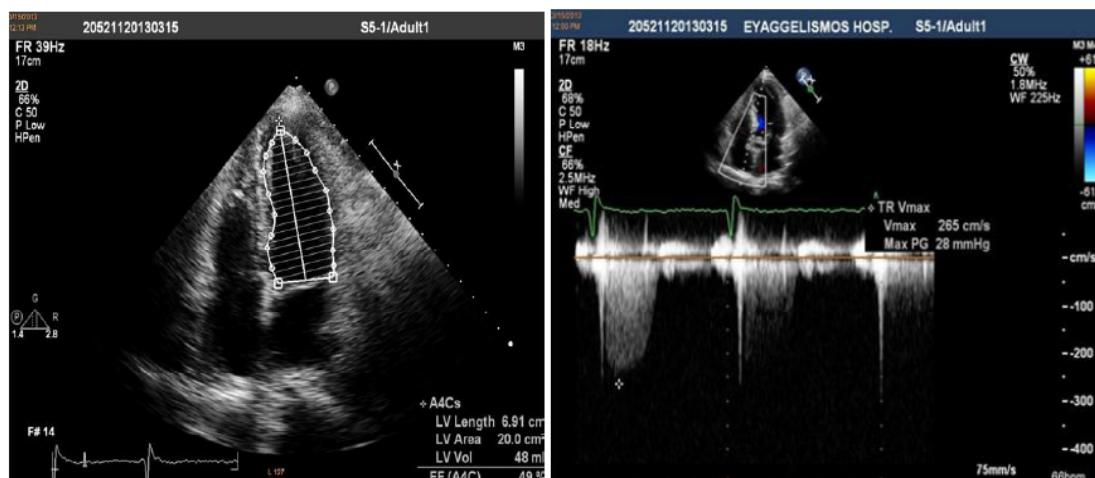


Figure 5:

estimated at 34.6 / 1 million people – years. CSS is slightly more common in males, at a ratio of 1.4 / 1 and is usually seen in people aged 15-69 years. The manifestations of vasculitis usually appear in the middle of the 4th decade of life. CSS is associated with various endogenous or exogenous factors: heredity, parasitic diseases, drugs (carbamazepine, macrolides) and environmental factors.

CSS consists of three stages, but not all patients develop all three stages or progress from one stage to the next in the same order. The early (prodromal) stage is marked by airway inflammation. Almost all patients experience mild to severe asthma and/or allergic rhinitis, nasal polyposis, sinusitis and recurrent bronchitis or pneumonitis. It lasts average 28 months (range 4-72 months) and in some patients 30 years. The second stage is characterized by abnormally high numbers of eosinophils (hypereosinophilia) in peripheral blood, in combination with tissue eosinophilia and Loeffler's syndrome and fever (in exacerbations of the disease). The symptoms of hypereosinophilia depend on which part of the body is affected, but most often it affects the lungs and digestive tract. The eosinophilic stage can last months or years, and its symptoms can disappear, only to return later. Patients may experience the third stage simultaneously. The third stage consists of vasculitis, which can eventually lead to cell death and can be life-threatening. It manifests with congestive heart failure, bloody diarrhea (usually due to mesenteric vasculitis), abdominal pain, pain in the testicles, peripheral neuropathy (usually multiple mononeuritis), convulsions, mental and motor disorders, usually sudden. Often affected the sciatic and, less frequently, the radial, the median and the ulnar nerve. Clinical examination shows motor and sensory (hypesthesia or hyperesthesia, allodynia, pain) disorders, particularly of the lower extremities. Frequent skin lesions are purpura and nodules.

CSS is consequently considered a highly variable condition in terms of its presentation and its course. The most serious complication of the vasculitic stage is congestive heart failure with reduced ejection fraction (85% of cases) and vasculitis coronary artery granulomatous pericarditis (about 1/3 of the patients). Kidney complications have been reported as being less common.

Eosinophilia ($>1.500/\text{mm}^3$ or $>10\%$ of peripheral white blood cells) is typical finding of CSS in the second phase in 90% of untreated patients and remits immediately with corticosteroids. There are also

observed increased acute phase proteins (ESR, CRP), normocytic anemia, increased titles of ANCA, mainly p-ANCA and increase in serum IgE.

For classification purposes, a patient shall be said to have CSS if at least four of these six criteria are positive: Asthma, Eosinophils greater than 10% of a differential white blood cell count, Presence of mononeuropathy or polyneuropathy, Unfixed pulmonary infiltrates, Presence of paranasal sinus abnormalities, Histological evidence of extravascular eosinophils.

Treatment for CSS includes glucocorticoids (such as prednisolone). The corticosteroids are the main treatment for CSS. Other immunosuppressive drugs (such as azathioprine, methotrexate, cyclosporine cyclophosphamide) consists second line treatment when it is indicated (severe manifestations of the disease or non-response/complications in corticosteroids). Interferon- α and plasmapheresis can be used as 3rd line. Over 90% of patients with CSS have remission with corticosteroids, although 25-30% of them relapse. Corticosteroids also improves systolic and diastolic dysfunction of the heart associated with cardiomyopathy. Greater risk of death or serious morbidity are patients with severe myocardial or gastrointestinal vasculitis. The 5-year survival of CSS is 62%.

In our case the obtained biopsies were negative for vasculitis. However due to the presence of positive p-ANCA antibodies, peripheral neuropathy and eosinophilia, the patient considered that he was suffering from CSS and treated with prezolon 75 mg and medrol 32 mg per day. The patient exited on medical treatment with methylprednisolone 16 mg, calcium, alendronate 70 mg, atorvastatin 40 mg, metoprolol 100 mg, valsartan 40 mg, aspirin 100 mg and omeprazole 20 mg.

Idiopathic Hypereosinophilia Syndrome [6, 7] is characterized by eosinophilia and anemia. In our patient, it has been excluded since we did not detect FIP1L1-PDGFR α fusion gene in bone marrow smear which is associated with. Löffler's syndrome [8] is a disease in which eosinophils accumulate in the lung or in the heart in response to a parasitic infection (*Ascaris lumbricoides* mainly). [9] Löffler's endocarditis can be presented with restrictive cardiomyopathy due to infiltration of the endocardium by eosinophils or myocardial fibrosis and thrombi in the cavities of the heart. It progresses rapidly to death. Control for parasite infection was negative in our case. Kounis

syndrome [10, 11] is a group of symptoms that manifests as acute coronary syndrome and is triggered by the release of inflammatory mediators following an allergic insult and causes coronary artery spasm and/or atheromatous plaque erosion or rupture. It is also characterized by eosinophilia and IgE (+).

Wegener's granulomatosis (WG) [12, 13] is a form of vasculitis that affects small size vessels in many organs. Damage to the lungs and kidneys by an autoimmune attack of cytoplasmic antineutrophil antibodies (c-ANCA) can be fatal.

The generalized WG is characterized by necrotizing granulomatous vasculitis of the upper or lower respiratory tract (paranasal sinuses, nasal passages, throat, lungs), generalized necrotizing vasculitis of arteries and veins and focal necrotizing glomerulonephritis. Limited WG affects the upper respiratory or lungs.

Autoimmune or allergic reactions or hypersensitivity reactions to unknown antigens such as bacteria. The most common micro-organism which is involved considered *Staphylococcus aureus*. WG may be silent or may have a rapidly progressive course.

It may be manifest as myocarditis, endocarditis, myocardial ischemia due to coronary vasculitis or complete atrioventricular block. Heart failure may be the first manifestation of the disease. Pericarditis is the most common heart attack event in WG, observed in 50% of cases of histologically established infection of the heart. Diagnosis of WG is based on a combination of clinical manifestations and laboratory findings (anemia, thrombocytosis, eosinophilia, hypergammaglobulinemia, increase ESR and CRP, proteinuria, microscopic hematuria, c-ANCA), and if necessary, histological findings (granulomatous inflammation involving the respiratory tract and of small vessels). Diagnosis requires the presence 2/4 criteria. The presence of any 2 or more criteria has sensitivity 82.2% and specificity of 92%. Corticosteroids and cyclophosphamide are the recommended treatment [14].

REFERENCES

- [1] Tkachuk DC, Westbrook CA, Andreeff M, Donlon TA, Cleary ML, Pinkel D. Detection of bcr-abl fusion in chronic myelogenous leukemia by in situ hybridization *Science* 26 October 1990; Vol. 250 no. 4980 pp. 559-562. <http://dx.doi.org/10.1126/science.2237408>
- [2] Cools J1, Stover EH, Gilliland DG. Detection of the FIP1L1-PDGFR α fusion in idiopathic hypereosinophilic syndrome and chronic eosinophilic leukemia *Methods Mol Med*. 2006; 125: 177-87.
- [3] Churg J, Strauss L. Allergic granulomatosis, allergic angiitis and polyarteritis nodosa. *Am J Pathol* 1951; 27: 277-301.
- [4] Fauci AS, Haynes BF, Katz P. The spectrum of vasculitis: clinical, pathologic, immunologic and therapeutic considerations. *Ann Intern Med* 1978; 89: 660-76. <http://dx.doi.org/10.7326/0003-4819-89-5-660>
- [5] Lanham JG, Elkon KB, Pusey CD, Hughes GR. Systemic vasculitis with asthma and eosinophilia: a clinical approach to the Churg–Strauss syndrome. *Medicine* 1984; 63: 65–81. <http://dx.doi.org/10.1097/00005792-198403000-00001>
- [6] Osowo A, Fettes J, Navaneethan S. Idiopathic hypereosinophilic syndrome: a rare but fatal condition presenting with common symptoms. *South Med J*. 2006 Feb; 99(2): 188-9. <http://dx.doi.org/10.1097/01.smj.0000199745.51112.fa>
- [7] Weller PF, Buley GJ. The idiopathic hypereosinophilic syndrome. *Blood*. 1994 May 15; 83(10): 2759-79.
- [8] "Zur Differential-Diagnose der Lungenfiltrierungen. I. Frühfiltrate unter besonderer Berücksichtigung der Rückbildungszeiten". *Beiträge zum Klinik der Tuberkulose* 79: 338–367.
- [9] Acar A, Oncül O, Cavuşlu S, Okutan O, Kartaloğlu Z. Case report: Löfller's syndrome due to *Ascaris lumbricoides* mimicking acute bacterial community-acquired pneumonia]. *Türkiye Parazitoloj Derg*. 2009; 33(3): 239-41.
- [10] Kounis NG. Coronary hypersensitivity disorder: the Kounis syndrome. *Clin Ther*. 2013 May; 35(5): 563-71. <http://dx.doi.org/10.1016/j.clinthera.2013.02.022>
- [11] Lopez PR, Peiris AN. Kounis syndrome. *South Med J*. 2010 Nov; 103(11): 1148-55. <http://dx.doi.org/10.1097/SMJ.0b013e3181f8c56f>
- [12] Seo P, Stone JH. "The antineutrophil cytoplasmic antibody-associated vasculitides". *Am. J. Med*. 117 (1): 39-502. ^ Jump up to: a b synd/2823 at Who Named It?
- [13] Falk RJ, Gross WL, Guillevin L et al. "Granulomatosis with polyangiitis (Wegener's): An alternative name for Wegener's granulomatosis". *Ann. Rheum. Dis*. 70: 74.
- [14] Tracy CL, Papadopoulos PJ, Bye MR, Connolly H, Goldberg, E, O'Brian RJ, et al. Wolf, RE (10 February 2014). Diamond, HS, ed. "Granulomatosis with Polyangiitis Treatment & Management". *Medscape Reference*. WebMD. Retrieved 16 March 2014.