

Sexual Dimorphism of the *Fovea Capitis Femoris* in a Medieval Population from Gloucester, England

Natalie Murton, Matteo Borrini and Constantine Eliopoulos*

Research Centre in Evolutionary Anthropology and Palaeoecology, School of Natural Sciences and Psychology, Liverpool John Moores University, Byrom Street, Liverpool L3 3AF, U.K.

Abstract: Attempts to develop new methods of sex determination in forensic anthropology are constantly being made by researchers in the field. This paper investigates the potential of using an index of the *fovea capitis femoris* shape as a method of sex determination. The currently held belief is that variation within the *fovea capitis* is purely idiosyncratic. The study was carried out on a sample of 19 males and 19 females from the Gloucester skeletal collection housed at Liverpool John Moores University. Measurements of the maximum *fovea capitis* height and breadth were taken from both the left and right femora and converted into an index. It was found that while there was no significant difference in dimensions alone, there was a significant difference in index values between males and females for both the left ($t_{(34)} = 4.294$, $p < 0.001$) and right ($t_{(32)} = 3.046$, $p = 0.05$) *fovea capitis*. This method was found to have 78.1% accuracy in determining the sex of an individual. Therefore, we may now be able to state that variation of the *fovea capitis* is sexually dimorphic and not exclusively idiosyncratic as first thought.

Keywords: Forensic anthropology, *Fovea capitis*, Sexual dimorphism, Proximal femur, Sex determination, Idiosyncratic variation.

INTRODUCTION

The past two decades have seen the rapid development of metric methods for establishing the sex of an individual from the skeleton. From an anthropological perspective, it is important to note that “sex” and “gender” are not synonyms, and should not be interchanged with one another, as sex refers to biological traits and gender is a social construct [1]. Sex determination from skeletonised remains is based upon two factors: differences in size, with males generally being larger than females, and differences of skeletal structures related to function. The cause for these changes is primarily hormonal, with the influence of testosterone in males having a catalytic effect during puberty, while females retain more paedomorphic features [2]. It has been argued that the identification of the sex of an individual is an important step in any medicolegal investigation [2]. By establishing the sex of an individual and constructing a biological profile, the list of potential victims in a murder case can be narrowed down considerably. Sex determination is a growing area of research nowadays, with osteometric standards constantly being renewed [3]. In archaeological contexts the two main skeletal elements used for sexing (the skull and pelvis) are often not recovered, or are too damaged for detailed

analysis to take place. Therefore, data must be taken from postcranial skeletal elements, especially long bones [4]. The use of the femur for sexual determination has been researched by many anthropologists including Işcan and Miller-Shavitz [5] and Asala *et al.* [6]. It has been argued that determination of sex from the femur is more reliable than from the tibia [5]. However, data can vary considerably according to the population sample under study [7]. The proximal portion of the femur is often preserved in archaeological cases due to its positioning within the acetabulum and its overall robustness. In cases where only the proximal portion of the femur is available for analysis, the maximum diameter of the femoral head is frequently used to establish an individual's sex [8]. However, it is suggested that multiple methods utilizing a single element should be used in order to improve the likelihood of accurate sex determination [3]. It is the opinion of the authors that further metric methods of establishing the sex of an individual from a single skeletal element, such as the femur, are needed. These newly developed methods may help to validate estimates from currently existing methods and provide a way of sexing individuals in cases where there has been poor preservation of remains.

In recent anthropological literature, even though the proximal femur has been studied extensively, there has been very little research into the *fovea capitis* and its potential for providing data for sex determination. The *fovea capitis* is a small, non-articular depression or ‘pit’ located near the centre of the head of the femur which

*Address correspondence to this author at the Research Centre in Evolutionary Anthropology and Palaeoecology, School of Natural Sciences and Psychology, Liverpool John Moores University, Byrom Street, Liverpool L3 3AF, U.K.;
Tel: (0044) 151 231-2038;
E-mail: C.Eliopoulos@ljmu.ac.uk

receives the *ligamentum teres* from the acetabular notch of the *os coxae* [1]. The *ligamentum teres* is usually pyramidal in shape [9] which should be reflected in the *fovea capitis* of both males and females if the *fovea capitis* is not sexually dimorphic. There is a widely accepted view that variation within the *fovea capitis* is purely idiosyncratic. This means that it is simply individual variation that occurs naturally within any population. However, without conducting research into this, the claim can be neither supported nor disputed.

This paper will focus on the possibility of establishing a new method for the sex determination of an individual, using measurements from the *fovea capitis femoris*. The rationale is based on the theory that sexual dimorphism within the skeleton is functional, caused by the differing stresses and strains experienced by males and females. The main aim of this paper is to determine whether there are differences in the height and breadth of the *fovea capitis* between males and females. In addition, it proposes an index that will highlight any differences in *fovea capitis* shape that may be sexually dimorphic. The results of the study will allow us to determine whether the variation of the *fovea capitis* is truly idiosyncratic.

Current methods of sexing an individual by use of the proximal femur are highly accurate, with most having an accuracy of 80-90%. However, these studies are often highly population-specific and it has been suggested that they are only applicable to individuals from similar environmental backgrounds [7]. Some of the advantages of these methods are: they are relatively quick and simple and do not require expensive or highly sophisticated equipment. The method described in this paper aims to replicate the accuracy, speed and simplicity of the existing methods. It is hoped that in the future, this method may be able to be used in conjunction with other metric methods to determine an individual's sex with greater confidence.

MATERIALS AND METHODS

This study utilized the femora and innominate of 38 individuals from the Gloucester collection, housed at Liverpool John Moores University. A total of 19 skeletons were estimated to be male and 19 female. Individuals expressing pathologies affecting the lower limbs, such as osteoarthritis, were omitted from the sample. Only individuals with at least one femur and innominate from the same side preserved were selected for study. All individuals within the sample

were estimated to be between 25 and 60 years of age at the time of death. The age at death of each individual was assessed using Lovejoy's auricular surface method [10]. It is for the reasons stated above and due to the nature of the collection that the sample size of this study is relatively low. The skeletal population under study is not contemporary as the individuals represented in the sample were interred between the 12th and 17th centuries. It is also important to note that the remains used in this study form part of an urban population and the results within this paper should not be generalised to other, more modern populations or archaeological remains from rural communities.

In measuring, the femur was placed in a tray of rice (in order to stabilize it during measuring) with the lateral condyle facing downwards and the femoral head facing upwards. It is important to stabilize the femur during measuring to ensure that all measurements are as accurate as possible. The distances between the most superior and most inferior points (Maximum *fovea capitis* height – AB) and the most medial and most lateral points (Maximum *fovea capitis* breadth – CD) on the *fovea capitis* were measured to the nearest 0.01mm using a Mitutoyo Digimatic Calliper (Figure 1). Great care was taken not to scratch or damage the remains with the sharp points of the calliper during measuring. Each measurement was taken on three separate occasions, and then averaged to increase reliability. A minimum of three days was left between measurements of the same individual, in order to reduce the amount of observer bias. Intra-observer error for the measurements was calculated to be between 0.13 and 3.19%. An index of *fovea capitis* shape was then created using the formula:

$$\frac{\text{Average maximum } fovea \text{ capitis height of individual} \times 100}{\text{Average maximum } fovea \text{ capitis breadth of individual}}$$

Values were calculated for males and females in the same manner, using measurements from both an individual's left and right femora. The sex of each individual was also recorded by scoring the greater sciatic notch and pre-auricular sulcus in accordance with Buikstra and Ubelaker [11] and by the Phenice method when the relevant structures were available [12].

Data organization and analysis was then performed using SPSS statistical analysis software, version 20. Significance levels were set at the 95% confidence level.

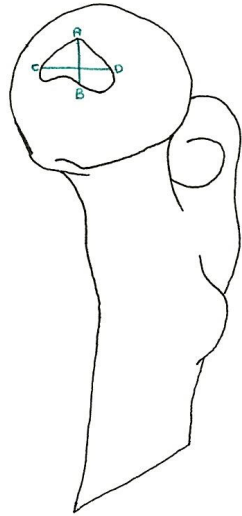


Figure 1: Measurements taken from the *fovea capitis*, where AB is maximum *fovea capitis* height and CD is maximum *fovea capitis* breadth.

RESULTS

To assess whether there is a difference in the *fovea capitis* dimensions of males and females, independent sample t-tests were used. Taking the individual measurements alone, no significant differences were found between the left *fovea capitis* height of males and females $t_{(34)} = 1.534$, $p = 0.134$. The same is also true of the right *fovea capitis* height $t_{(32)} = 0.174$, $P = 0.863$. There were also no significant differences between the left *fovea capitis* breadth $t_{(34)} = -1.049$, $p = 0.301$ or the right *fovea capitis* breadth of males and females $t_{(32)} = -2.073$, $p = 0.064$.

However, the most striking finding to emerge from the data is that when *fovea capitis* breadth and height are combined into an index of shape, a significant result is produced. There is a significant difference between the index score, and therefore the overall shape of the left *fovea capitis* between males and females $t_{(34)} = 4.294$, $p < 0.001$. A significant difference was also found for the index score of the other side, and therefore the overall shape of the right *fovea capitis* between males and females $t_{(32)} = 3.046$, $p = 0.05$. Figure 2 presents the means and standard deviations for the left index scores of both males and females. There is a great difference between the mean index score of males (mean = 85.26) and females (mean = 66.71), with very little overlap between the two sets of data. However, there is one outlier in this data, sample number 19, with a particularly low score on the

left index. In Figure 3 the means and standard deviations for the right index scores of both males and females is presented. Here too there is a great degree of difference between the right index scores of males (mean = 84.05) and females (mean = 65.39). However, for index scores from the right *fovea capitis* there is a higher degree of overlap than for index scores from the left *fovea capitis*.

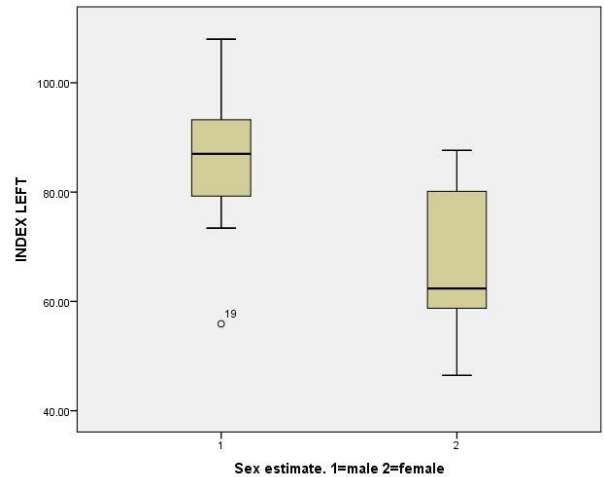


Figure 2: The mean left index score for males and females and the standard deviation

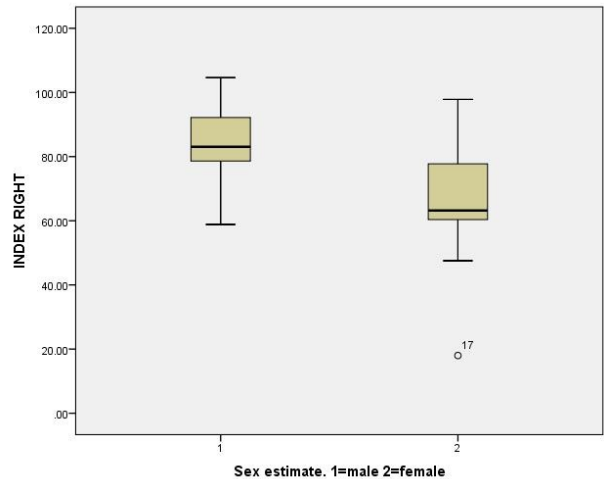


Figure 3: The mean right index score for males and females and the standard deviation

Figure 4 presents the frequency of each index score for the left *fovea capitis* in males and females. It can be seen that most of the males within the sample have a left index score above 70, whilst most of the females within the sample have a left index score below 70. There is a low amount of overlap in the data, showing a small number of individuals for which determining sex using index values alone may be difficult.

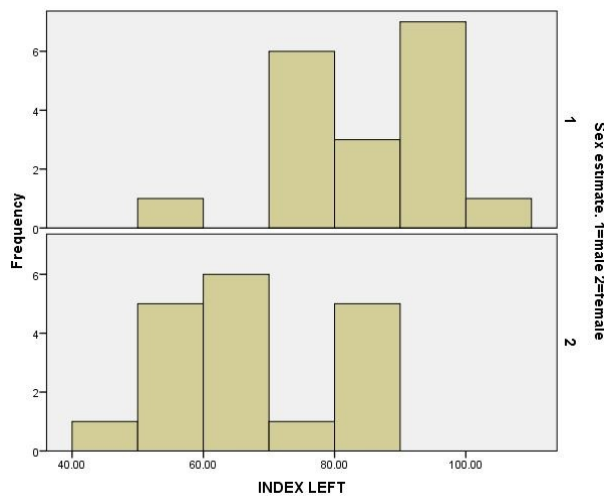


Figure 4: Frequency of each index score for the left *fovea capitis*.

To assess the accuracy of sexing an individual using an index of *fovea capitis* shape, a discriminant function analysis was conducted on the data. The analysis found that 78.1% of the original grouped cases were correctly identified. A p value of 0.02 was given, showing that this model is a good fit for the data. Figure 5 indicates how the data can be classified into two distinct groups for male and female using both the left and right index scores. Values for females tend to fall towards the lower end of the spectrum, with values for males being much higher in most cases. There is an area of overlap in the data, with a small number of males and females sharing similar index scores.

Pearson's product moment correlations were then conducted on the data in order to determine whether there was any relationship between the following variables: 1) Left index score and left sciatic notch score, 2) Left index score and left pre-auricular sulcus score, 3) Right index score and right sciatic notch score, 4) Right index score and right pre-auricular sulcus score. Analysis found a weak, yet significant positive correlation between the left index score and left sciatic notch score $r = 0.386$, $p = 0.029$. A weak, but significant positive correlation was also found between the left index score and the left pre-auricular sulcus score $r = -4.90$, $p < 0.001$. This correlation was found to be significant at both the 0.05 and the 0.01 significance level. No significant correlation was found between the right index score and right sciatic notch score ($r = 0.254$, $p = 0.175$), however, a weak, significant positive correlation was found between the right index score and the right pre-auricular sulcus score, $r = -0.413$, $p = 0.21$.

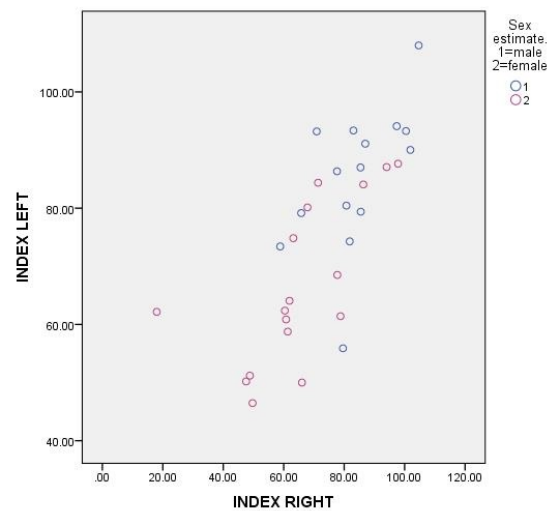


Figure 5: Index scores for males and females: individuals fall into two distinct groups.

DISCUSSION

Thus far, no research on the potential usefulness of the *fovea capitis* in biological profiling has been reported in the literature, and the currently accepted view is that variation in this anatomical area is purely idiosyncratic. However, the results of this study seem to challenge this view. The results of the independent t-test conducted in this study indicate that the shape of the *fovea capitis*, when expressed as an index, is sexually dimorphic. These findings were largely unanticipated, as was the relatively high degree of accuracy (78.1%) of this method. If variation within the *fovea capitis* was purely idiosyncratic we would expect an accuracy of around 50%. Interpretation of the results suggests that individuals with an index score below 70 can be classed as female, individuals with an index score above 85 can be classed as male, and individuals with an index score between 71 and 84 are of indeterminate sex. During the study, the author taking the measurements made an empirical observation: for individuals with an index score above 85, the *fovea capitis* has a round or oval shape. For those with an index score below 70, the *fovea capitis* appears to be more 'triangular' or irregular in shape. It is important to note that in some, but not all cases, this difference in *fovea capitis* shape may be identified macroscopically. However, it is important to remember that methods of 'eyeballing' a trait are far less accurate than metric methods of sex determination and often result in incorrect results [13]. From comparison of the mean index values from right and left femora and their standard deviations (Figures 2 and 3) it appears that measurements from the left *fovea capitis* may be more

discriminant than measurements from the right *fovea capitis*.

The results of the independent t-tests are difficult to explain, but they may be due to a number of different factors, most relating to the function of the femur and pelvis. Firstly, the head of the femur is known as a pressure epiphysis (a point of weight transmission) and is therefore affected by the difference in male and female body weight [14]. The relative axial skeleton weight of males is greater than that of females [15] and therefore a greater amount of pressure is exerted on the femoral head of males than that of females. This may have caused the *ligamentum teres* to have a different effect upon the bones of males and females. Another possible explanation for these results is the anatomical differences in the female pelvis that aid childbirth [13]. The female pelvis is wider than that of the male, which affects the angle of the femur in anatomical position, and therefore may also affect the positioning and dimensions of the *fovea capitis*. An alternative explanation for these results may be that differences in male and female gait produce a slight variation in the way the *ligamentum teres* interacts with the *fovea capitis*, leading to a slight difference in the markings left in bone [16]. It is therefore advised that further research is undertaken in this area in order to fully understand the reasons why the *fovea capitis* appears to be sexually dimorphic. Collaboration between researchers from several different disciplines may be needed.

The claim that the *fovea capitis* may be helpful in determining the sex of an individual is supported, in part, by research conducted by Purkait [14]. Purkait deviated from conventional measurements and developed a new method of determining the sex of an individual using the most superior point on the *fovea capitis*, the apex of the lesser trochanter and the most lateral point on the greater trochanter. Purkait's method was found to have an accuracy of between 95 and 97% for individuals of Indian ancestry. Although Purkait's study did not use measurements from the *fovea capitis* alone, it shows the potential of the *fovea capitis* in helping to develop new methods of sex estimation and was a source of inspiration for the present study. Results of the Pearson's product moment correlations suggest a relationship between the sciatic notch scores, pre-auricular sulcus scores and index scores. The most likely explanation for these correlations appears to be the changes in morphology of the female pelvis due to its reproductive function.

CONCLUSION

Some of the advantages of the method proposed in the current study are that it is uncomplicated, requires only sliding callipers and produces results rapidly. However, limitations of this method are that it cannot be used on juvenile individuals, in whom the epiphyses are not fused onto the shaft of the femur or may not be fully developed. Specimens altered by pathological conditions may also not be suitable. This method may therefore be inappropriate for individuals falling into the older age categories and osteoarthritis is more likely to be present on the head of the femur. Furthermore, before a definitive link between *fovea capitis* shape and sex can be established, further testing of the method is needed using contemporary collections with a large sample size.

All the results within this report need to be interpreted with caution. This study represents an urban population from the medieval time period and therefore the results should not be generalised to other, modern populations. Additional research must be conducted with both contemporary populations and medieval populations from rural areas to see if similar results can be obtained. The relatively small sample size of this study must also be taken into consideration. Further studies with larger population sizes may produce different results, where there is no relationship between *fovea capitis* shape and sex. However, utilising a larger sample size may also help to make the relationship between *fovea capitis* shape and sex clearer and help improve the accuracy of the method. It is important to note that even though height and breadth of the *fovea capitis* alone are not sexually dimorphic, the overall shape when expressed as an index, is. As with all new methods of sex determination, these results will doubtless be much scrutinized, but the findings of the present study suggest that for British medieval populations from an urban environment the *fovea capitis* is sexually dimorphic. Further research on various populations, can also help increase the accuracy of the existing methods.

ACKNOWLEDGEMENTS

The authors would like to thank Gloucester Museum for making their skeletal collection available for study at Liverpool John Moores University.

REFERENCES

- [1] White TD, Folkens PA. The Human Bone Manual, 1st Ed. Elsevier Academic Press, London; 2005.

- [2] Brown RP, Ubelaker DH, Schanfield MS. Evaluation of Purkait's Triangle method for determining sexual dimorphism. *J Forensic Sci* 2007; 52:553-556
<http://dx.doi.org/10.1111/j.1556-4029.2007.00423.x>
- [3] Mall G, Graw M, Gehring KD and Hubig M. Determination of sex from femora. *Forensic SciInt* 2000; 113: 315-321
[http://dx.doi.org/10.1016/S0379-0738\(00\)00240-1](http://dx.doi.org/10.1016/S0379-0738(00)00240-1)
- [4] Di Bennardo R, Taylor JV. Multiple discriminant function analysis of sex and race in the post cranial skeleton. *Am J Phys Anthropol* 1983; 61: 306-314.
- [5] Işcan MY and Miller-Shaivitz P. Determination of sex from the femur in blacks and whites. *Coll. Anthropol* 1984; 2: 169-175
- [6] Asala SA, Bidmos MA, Dayal MR. Discriminant function sexing of fragmentary femur of South African blacks. *Forensic SciInt* 2004; 145: 25-29
<http://dx.doi.org/10.1016/j.forsciint.2004.03.010>
- [7] Alunni-Perret V, Staccini P, Quatrehomme G. Sex determination from the distal part of the femur in a French contemporary population. *Forensic SciInt* 2007; 175: 113-117
<http://dx.doi.org/10.1016/j.forsciint.2007.05.018>
- [8] Kelly MA. Sex determination with fragmented skeletal remains. *J For Sci* 1979; 24: 154-158.
<http://dx.doi.org/10.1520/jfs10802j>
- [9] Byrd JW, Jones KS. Traumatic rupture of the ligamentum teres as a source of hip pain. *Arthroscopy* 2004; 20: 385-391
<http://dx.doi.org/10.1016/j.arthro.2004.01.025>
- [10] Lovejoy CO, Meindl RS, Pryzbeck TR, Mensforth RP. Chronological metamorphosis of the auricular surface of the ilium: A new method for the determination of adult skeletal age at death. *Am J Phys Anthropol* 1985; 68: 15-28
<http://dx.doi.org/10.1002/ajpa.1330680103>
- [11] Buikstra JE, Ubelaker DH. Standards for Data collection from Human Skeletal remains. Fayetteville, Arkansas: Arkansas Archaeological Survey Report Number 44; 2004.
- [12] Phenice TW. A newly developed visual method of sexing the os pubis. *Am J Phys Anthropol* 1969; 30: 297-301.
<http://dx.doi.org/10.1002/ajpa.1330300214>
- [13] Purkait R. Sex determination from femoral head measurements: a new approach. *J Leg Med* 2003; 5: 347-350
[http://dx.doi.org/10.1016/S1344-6223\(02\)00169-4](http://dx.doi.org/10.1016/S1344-6223(02)00169-4)
- [14] Purkait R. Triangle identified at the proximal end of femur: a new sex determinant. *For SciInt* 2004; 147: 135-139.
- [15] William PL, Warwick R. *Gray's Anatomy*, 36th ed. Churchill Livingstone, Edinburgh; 1980.
- [16] Lovejoy CO (1988). Evolution of human walking. *Sci Am* 1988; 256: 118-125.
<http://dx.doi.org/10.1038/scientificamerican1188-118>

Received on 24-11-2015

Accepted on 08-12-2015

Published on 30-12-2015

<http://dx.doi.org/10.15379/2410-2806.2015.02.02.02>© 2015 Murton *et al.*; Licensee Cosmos Scholars Publishing House.

This is an open access article licensed under the terms of the Creative Commons Attribution Non-Commercial License (<http://creativecommons.org/licenses/by-nc/3.0/>), which permits unrestricted, non-commercial use, distribution and reproduction in any medium, provided the work is properly cited.